National Comprehensive Cancer Network®

NCCN Clinical Practice Guidelines in Oncology (NCCN Guidelines®)

Neuroendocrine and Adrenal Tumors

Version 3.2025 — October 1, 2025

NCCN.org

NCCN recognizes the importance of clinical trials and encourages participation when applicable and available. Trials should be designed to maximize inclusiveness and broad representative enrollment.

NCCN Guidelines for Patients® available at www.nccn.org/patients

Continue

Version 3.2025, 10/01/2025 © 2025 National Comprehensive Cancer Network® (NCCN®), All rights reserved. NCCN Guidelines® and this illustration may not be reproduced in any form without the express written permission of NCCN.

PLEASE NOTE that use of this NCCN Content is governed by the End-User License Agreement, and you MAY NOT distribute this Content or use it with any artificial intelligence model or tool.
Printed by Galya Basol Kochav on 1/7/2026 1:55:52 PM. Copyright © 2026 National Comprehensive Cancer Network, Inc. All Rights Reserved.

NCCN Guidelines Version 3.2025
Neuroendocrine and Adrenal Tumors

***Emily Bergsland, MD/Chair †**
UCSF Helen Diller Family Comprehensive Cancer Center

***J. Bart Rose, MD/Vice Chair ¶**
O'Neal Comprehensive Cancer Center at UAB

Al B. Benson III, MD †
Robert H. Lurie Comprehensive Cancer Center of Northwestern University

Zachary Berman, MD ∩
UC San Diego Moores Cancer Center

Lawrence S. Blaszkowsky, MD ‡
Dana-Farber/Brigham and Women's Cancer Center | Mass General Cancer Center

Pamela Brock, MS ∆
The Ohio State University Comprehensive Cancer Center - James Cancer Hospital and Solove Research Institute

Jennifer Chan, MD †
Dana-Farber/Brigham and Women's Cancer Center | Mass General Cancer Center

Deyali Chatterjee, MD ≠
The University of Texas MD Anderson Cancer Center

Paxton V. Dickson, MD ¶
The University of Tennessee Health Science Center

Abbey Fingeret, MD, MHPTT ð ¶
Fred & Pamela Buffett Cancer Center

Apar Kishor P. Ganti, MD †
Fred & Pamela Buffett Cancer Center

Phillip Ge, MD ¤
The University of Texas MD Anderson Cancer Center

Mark Girgis, MD ¶
UCLA Jonsson Comprehensive Cancer Center

Thorvardur R. Halfdanarson, MD ‡ Þ †
Mayo Clinic Comprehensive Cancer Center

Christopher L. Hallemeier, MD §
Mayo Clinic Comprehensive Cancer Center

Jin He, MD, PhD ¶
Johns Hopkins Kimmel Cancer Center

Rong Hu, MD ≠
University of Wisconsin Carbone Cancer Center

Shruti Jolly, MD, MBA §
University of Michigan Rogel Cancer Center

Fouad Kandeel, MD, PhD ð
City of Hope National Medical Center

Syed M. Kazmi, MD † Þ ‡
UT Southwestern Simmons Comprehensive Cancer Center

Xavier Keutgen, MD ¶
The UChicago Medicine Comprehensive Cancer Center

Sajid A. Khan, MD ¶
Yale Cancer Center/ Smilow Cancer Hospital

Christopher Lieu, MD †
University of Colorado Cancer Center

Amr Mohamed, MD †
Case Comprehensive Cancer Center/ University Hospitals Seidman Cancer Center and Cleveland Clinic Taussig Cancer Institute

Shaffer Mok, MD ¤
Moffitt Cancer Center

Nitya Raj, MD †
Memorial Sloan Kettering Cancer Center

Fatma Sen, MD, MSc ϕ ⦶
UC Davis Comprehensive Cancer Center

Shagufta Shaheen, MD †
Stanford Cancer Institute

Heloisa P. Soares, MD, PhD †
Huntsman Cancer Institute at the University of Utah

Michael C. Soulen, MD ∩
Abramson Cancer Center at the University of Pennsylvania

Zachary Stiles, DO, MS ¶
Roswell Park Comprehensive Cancer Center

Jonathan R. Strosberg, MD †
Moffitt Cancer Center

Craig R. Sussman, MD ð Þ
Vanderbilt-Ingram Cancer Center

Nikolaos A. Trikalinos, MD ‡ †
Siteman Cancer Center at Barnes-Jewish Hospital and Washington University School of Medicine

Namrata Vijayvergia, MD †
Fox Chase Cancer Center

Terence Wong, MD, PhD ϕ ⦶
Duke Cancer Institute

Anthony Yang, MD, MS, FACS ¶
Indiana University Melvin and Bren Simon Comprehensive Cancer Center

David B. Zhen, MD †
Fred Hutchinson Cancer Center

NCCN
Cindy Hochstetler, PhD
Beth McCullough, RN, BS

∆ Cancer genetics
⦶ Diagnostic radiology
ð Endocrinology
¤ Gastroenterology
‡ Hematology/Hematology oncology
Þ Internal medicine
∩ Interventional radiology
† Medical oncology
ϕ Nuclear medicine
≠ Pathology
¥ Patient advocacy
§ Radiotherapy/Radiation oncology
¶ Surgery/Surgical oncology
* Discussion Section Writing Committee

NCCN Guidelines Panel Disclosures

Continue

Version 3.2025, 10/01/2025 © 2025 National Comprehensive Cancer Network® (NCCN®), All rights reserved. NCCN Guidelines® and this illustration may not be reproduced in any form without the express written permission of NCCN.

PLEASE NOTE that use of this NCCN Content is governed by the End-User License Agreement, and you MAY NOT distribute this Content or use it with any artificial intelligence model or tool.
Printed by Galya Basol Kochav on 1/7/2026 1:55:52 PM. Copyright © 2026 National Comprehensive Cancer Network, Inc. All Rights Reserved.

NCCN Guidelines Version 3.2025
Neuroendocrine and Adrenal Tumors

NCCN Neuroendocrine and Adrenal Tumors Panel Members
Summary of the Guidelines Updates

Clinical Presentations and Diagnosis (CP-1)
Neuroendocrine Tumors of the Gastrointestinal Tract (Well-Differentiated Grade 1/2), Lung, and Thymus (NET-1)
Neuroendocrine Tumors of the Pancreas (Well-Differentiated Grade 1/2) (PanNET-1)
Neuroendocrine Neoplasms of Unknown Primary (NUP-1)
Well-Differentiated, Grade 3 Neuroendocrine Tumors (WDG3-1)
Extrapulmonary Poorly Differentiated: Neuroendocrine Carcinoma/Large or Small Cell Carcinoma/Mixed Neuroendocrine-Non-Neuroendocrine Neoplasm (PDNEC-1)
Adrenal Gland Tumors (AGT-1)
Pheochromocytoma/Paraganglioma (PHEO-1)
Multiple Endocrine Neoplasia, Type 1 (MEN1-1)
Multiple Endocrine Neoplasia, Type 2 (MEN2-1)

Principles of Pathology for the Diagnosis of Neuroendocrine Neoplasms (NE-A)
Principles of Pathology for the Diagnosis of Adrenocortical Carcinoma (NE-B)
Principles of Pathology for the Diagnosis of Pheochromocytoma/Paraganglioma (NE-C)
Principles of Imaging (NE-D)
Principles of Biochemical Testing (NE-E)
Principles of Surgical Management of Neuroendocrine Tumors (NE-F)
Principles of Hereditary Cancer Risk Assessment and Genetic Counseling (NE-G)
Principles of Systemic Anti-Tumor Therapy (NE-H)
Principles of Radiation Therapy (NE-I)
Principles of Peptide Receptor Radionuclide Therapy with Lutetium Lu 177 Dotatate (NE-J)
Principles of Liver-Directed Therapy for Neuroendocrine Tumor Metastases (NE-K)
Principles of Hormone Control (NE-L)
Staging (ST-1)

Abbreviations (ABBR-1)

Find an NCCN Member Institution: https://www.nccn.org/home/member-institutions.

NCCN Categories of Evidence and Consensus: All recommendations are category 2A unless otherwise indicated.

See NCCN Categories of Evidence and Consensus.

NCCN Categories of Preference: All recommendations are considered appropriate.

See NCCN Categories of Preference.

The NCCN Guidelines® are a statement of evidence and consensus of the authors regarding their views of currently accepted approaches to treatment. Any clinician seeking to apply or consult the NCCN Guidelines is expected to use independent medical judgment in the context of individual clinical circumstances to determine any patient's care or treatment. The National Comprehensive Cancer Network® (NCCN®) makes no representations or warranties of any kind regarding their content, use or application and disclaims any responsibility for their application or use in any way. The NCCN Guidelines are copyrighted by National Comprehensive Cancer Network®. All rights reserved. The NCCN Guidelines and the illustrations herein may not be reproduced in any form without the express written permission of NCCN. ©2025.

PLEASE NOTE that use of this NCCN Content is governed by the End-User License Agreement, and you MAY NOT distribute this Content or use it with any artificial intelligence model or tool.
Printed by Galya Basol Kochav on 1/7/2026 1:55:52 PM. Copyright © 2026 National Comprehensive Cancer Network, Inc. All Rights Reserved.

Updates in Version 3.2025 of the NCCN Guidelines for Neuroendocrine and Adrenal Tumors from Version 2.2025 include:

MS-1
• The discussion section has been updated to reflect changes in the algorithm.

Updates in Version 2.2025 of the NCCN Guidelines for Neuroendocrine and Adrenal Tumors from Version 1.2025 include:

NE-H 9 of 12
• Locally Unresectable and Distant Metastases, new option added: belzutifan.

Updates in Version 1.2025 of the NCCN Guidelines for Neuroendocrine and Adrenal Tumors from Version 5.2024 include:

Global:
• SSTR-PET footnote revised: SSTR-PET tracers ~~include:~~ *(eg,* 68Ga-DOTATATE, 64Cu-DOTATATE, and 68Ga-DOTATOC*)*.

Neuroendocrine Tumors of the Gastrointestinal Tract (Well-Differentiated Grade 1/2), Lung and Thymus
NET-1
• Header revised: ~~First-Line~~ Treatment.
• Evaluation column, As appropriate, third bullet revised: ~~Biochemical evaluation as clinically indicated~~ *Consider baseline 5-HIAA in asymptomatic patients with high burden of metastatic disease* (NE-E).
NET-2
• Evaluation column, Recommended, first bullet revised: Multiphasic abdomen~~/~~ ± pelvis CT or MRI (NE-D).
NET-5
• Surveillance column, middle pathway revised: EGD at 1 y and then *as* clinically indicated~~ as needed~~.
NET-6
• Evaluation column, new bullet added: Consider molecular profiling of tumor tissue (for atypical carcinoid).
• New footnote y added: Tumor/somatic molecular profiling should be considered for patients with locoregional unresectable/metastatic disease who are candidates for anticancer therapy to identify actionable alterations. Testing on tumor tissue is preferred; however, liquid biopsy can be considered if tumor tissue testing is not feasible. (Also for NET-11–12)
NET-8
• Surveillance column:
  ▸ 12 wk–12 mo post-resection:
    ◊ Third bullet revised: Multiphasic abdomen ± pelvis CT or MRI for primary GI NETs~~ and PanNETs~~ (as clinically indicated for lung and thymic NETs) (NE-D).
    ◊ Fourth bullet revised: Chest~~/abdomen~~ CT + *CT or MRI abdomen* with contrast for primary lung/thymic NETs (as clinically indicated for primary GI tumors).
  ▸ >1 y post-resection to 10 y, Every 12–24 mo, third sub-bullet revised: Multiphasic abdomen ± pelvis CT or MRI for primary GI NETs~~ and PanNETs~~ (as clinically indicated for lung and thymic NETs) (NE-D).
• Footnote aa revised: Earlier, if symptoms. If initial scans are negative, the frequency of follow-up scans may decrease.~~ For high-grade tumors, more frequent surveillance may be appropriate.~~

Continued

Version 3.2025, 10/01/2025 © 2025 National Comprehensive Cancer Network® (NCCN®), All rights reserved. NCCN Guidelines® and this illustration may not be reproduced in any form without the express written permission of NCCN.

PLEASE NOTE that use of this NCCN Content is governed by the End-User License Agreement, and you MAY NOT distribute this Content or use it with any artificial intelligence model or tool.
Printed by Galya Basol Kochav on 1/7/2026 1:55:52 PM. Copyright © 2026 National Comprehensive Cancer Network, Inc. All Rights Reserved.

Updates in Version 1.2025 of the NCCN Guidelines for Neuroendocrine and Adrenal Tumors from Version 5.2024 include:

NET-9
- Treatment column:
  - Top option revised: ~~Resect primary, regional lymph nodes + metastases~~ *Surgical treatment of primary and distant disease* (NE-F).
  - Bottom option, second bullet revised: Octreotide LAR or lanreotide ~~(NE-H 1 of 11)~~ and/or alternative front-line therapy *(NE-H 1 of 11 for systemic therapy options and NET-10 for locoregional therapy options)* ~~(see options for disease progression [NET-10 and NE-H 1 of 11])~~.

NET-13
- Footnote rr revised: ~~Potential~~ *Consider* referral to pulmonary *medicine* for ~~management of~~ symptom~~s~~ *management*.

NET-14
- Column following Carcinoid syndrome poorly controlled, second bullet, sub-bullet added: SC octreotide.
- Footnote uu revised: For symptom control, octreotide 100–250 mcg SC TID or octreotide LAR 20–30 mg IM or lanreotide 120 mg SC every 4 weeks. Dose and frequency may be further increased for symptom control as needed. Higher doses have been shown to be safe. ~~Therapeutic levels of octreotide would not be expected to be reached for 10–14 days after LAR injection. Short-acting octreotide can be added to octreotide LAR or lanreotide for rapid relief of symptoms or for breakthrough symptoms.~~
- New footnote vv added: Therapeutic levels of octreotide would not be expected to be reached for 10–14 days after LAR injection. Short-acting octreotide can be added to octreotide LAR or lanreotide for rapid relief of symptoms or for breakthrough symptoms.

Neuroendocrine Tumors of the Pancreas (Well-Differentiated Grade 1/2)

PanNET-2
- New footnote f added: Patients with germline mutations are treated based on any tumors of a concerning size.
- Footnote h revised: Preoperative ~~trivalent vaccine~~ *vaccination against encapsulated bacterium* (ie, pneumococcus, haemophilus influenzae b, meningococcal group C), if considering surgery with possible splenectomy. *See Principles of Surgical Management of Neuroendocrine Tumors (NE-F 2 of 3)*. (Also for PanNET-4, PanNET-6, PanNET-8, and PanNET-10)

PanNET-3
- Evaluation column, As appropriate, third bullet revised: EUS ± *biopsy*.
- New footnote l added: Multidisciplinary discussion prior to biopsy.

PanNET-5
- New footnote o added: Two-thirds of insulinomas are SSTR-PET negative and therefore may impact subsequent therapy and surveillance recommendations.

PanNET-8
- Following Resectable, option revised: Head ~~(rare)~~.

PanNET-11
- Surveillance column:
  - 12 wk–12 mo post-resection, third bullet revised: Multiphasic abdomen ± *pelvis* CT or MRI (NE-D).
  - >1 y post-resection to a maximum of 10 y, Every 6–12 mo, third sub-bullet revised: Multiphasic abdomen ± *pelvis* CT or MRI (NE-D).

Continued

Version 3.2025, 10/01/2025 © 2025 National Comprehensive Cancer Network® (NCCN®), All rights reserved. NCCN Guidelines® and this illustration may not be reproduced in any form without the express written permission of NCCN.

PLEASE NOTE that use of this NCCN Content is governed by the End-User License Agreement, and you MAY NOT distribute this Content or use it with any artificial intelligence model or tool.
Printed by Galya Basol Kochav on 1/7/2026 1:55:52 PM. Copyright © 2026 National Comprehensive Cancer Network, Inc. All Rights Reserved.

Updates in Version 1.2025 of the NCCN Guidelines for Neuroendocrine and Adrenal Tumors from Version 5.2024 include:

PanNET-12
- Following first column, top option removed: If cytoreduction possible (NE-F).
- Treatment column:
  - Following Asymptomatic, low tumor burden, and stable disease, new bullet added: Resect metastases and primary if possible and clinically indicated (NE-F).
  - Following Symptomatic or Clinically significant tumor burden or Clinically significant progressive disease:
    - New bullet added: Resect metastases and primary if possible and clinically indicated (NE-F).
    - Fourth bullet revised: Consider alternative front-line therapy (*NE-H 3 of 11*~~) and (see options for disease progression)~~ f*or systemic therapy options and* ~~(~~PanNET-13 *for locoregional therapy options)*~~ and NE-H 3 of 11)~~.
- Surveillance column, following Resect metastases and primary if possible and clinically indicated (NE-F), new link added: PanNET-11.
- Footnote ee revised: ~~Consider~~ *Use of* belzutifan ~~for resectable tumors~~ in the setting of germline VHL alteration *needs to be individualized* (category 2B). ~~The decision to use belzutifan in small resectable tumors needs to be individualized.~~ *Data for the use of belzutifan for larger tumors, locally advanced unresectable tumors, and distant disease are extremely limited. Clinical trials are ongoing*.

Well-Differentiated, Grade 3 Neuroendocrine Tumors

WDG3-1
- Footnote f revised: ...Testing on tumor tissue is preferred; however, ~~cell-free DNA testing~~ *liquid biopsy* can be considered if tumor tissue testing is not feasible.

WDG3-3
- Treatment column, following Asymptomatic, low tumor burden, new option added: or PRRT with lutetium Lu 177 dotatate (if SSTR-positive) (category 2B).

WDG3-4
- Treatment column, Locoregional therapy options, second bullet revised: Consider addition of liver-directed therapy ~~(embolization, selective internal RT, ablation, SBRT)~~ (NE-K).

Extrapulmonary Poorly Differentiated: Neuroendocrine Carcinoma/Large or Small Cell Carcinoma/Mixed Neuroendocrine-Non-Neuroendocrine Neoplasm

PDNEC-1A
- Footnote g revised: ...Consider specifically testing for potentially actionable somatic findings including, but not limited to: NTRK fusions, RET fusions, BRAF V600E mutations, microsatellite instability-high (MSI-H), mismatch repair deficiency (dMMR), and tumor mutational burden-high (TMB-H). Testing on tumor tissue is preferred; however, ~~cell-free DNA testing~~ *liquid biopsy* can be considered if tumor tissue testing is not feasible.

Adrenal Gland Tumors

AGT-1
- Evaluation column following Morphologic evaluation, option revised: Adrenal protocol *CT scan*.

AGT-3
- Additional Evaluation column following Tumor ≥4 cm or inhomogeneous, irregular margins, local invasion, or other malignant imaging characteristics, third bullet revised: Adrenal protocol *CT scan*.

Continued

Version 3.2025, 10/01/2025 © 2025 National Comprehensive Cancer Network® (NCCN®), All rights reserved. NCCN Guidelines® and this illustration may not be reproduced in any form without the express written permission of NCCN.

PLEASE NOTE that use of this NCCN Content is governed by the End-User License Agreement, and you MAY NOT distribute this Content or use it with any artificial intelligence model or tool.
Printed by Galya Basol Kochav on 1/7/2026 1:55:52 PM. Copyright © 2026 National Comprehensive Cancer Network, Inc. All Rights Reserved.

Updates in Version 1.2025 of the NCCN Guidelines for Neuroendocrine and Adrenal Tumors from Version 5.2024 include:

AGT-5
- New footnote v added: Optimal duration is unknown. The role of adjuvant chemotherapy is under investigation.

Pheochromocytoma/Paraganglioma
PHEO-1
- Evaluation column, As appropriate, if metastatic or multifocal disease suspected, new bullet added: Consider molecular profiling of tumor tissue.
- New footnote k added: Tumor/somatic molecular profiling should be considered for patients with locoregional unresectable/metastatic disease who are candidates for anticancer therapy to identify actionable alterations. Testing on tumor tissue is preferred; however, liquid biopsy can be considered if tumor tissue testing is not feasible.
- Footnote e revised: Both catecholamines and metanephrines/normetanephrines can represent false-positive results. *Some investigators support the use of fractionated urinary and/or plasma catecholamines as a way to differentiate false-positive results and to differentiate epinephrine-secreting PCC*. (Also page PHEO-3)

PHEO-2
- Header revised: ~~First-Line~~ Treatment.

Multiple Endocrine Neoplasia, Type 1
MEN1-1
- Clinical Evaluation column, Parathyroid, second bullet, first sub-bullet revised: Parathyroid hormone (PTH), ~~and~~ 25-OH vitamin D*, inorganic phosphate, 24-hour urine calcium and creatinine (NE-E 2 of 4)*.

Multiple Endocrine Neoplasia, Type 2
MEN2-1
- Clinical Evaluation column, Parathyroid, second bullet, first sub-bullet revised: ~~Parathyroid hormone (~~PTH~~)~~, ~~and~~ 25-OH vitamin D*, inorganic phosphate, 24-hour urine calcium and creatinine*.
- Footnote g revised: Both catecholamines and metanephrines/normetanephrines can represent false-positive results. *Some investigators support the use of fractionated urinary and/or plasma catecholamines as a way to differentiate false-positive results and to differentiate epinephrine-secreting PCC*.

NE-A 2 of 7
- Optional Information, first bullet, new sub-bullet added: Hormone staining with IHC is not helpful and, if positive, it does not mean there is a functional tumor.

NE-A 5 of 7
- Large cell neuroendocrine carcinoma, Criteria column, fifth bullet revised: Positive immunohistochemical staining for one or more neuroendocrine markers (other than NSE)~~ and/or neuroendocrine granules by electron microscopy~~.

NE-A 7 of 7
- Reference removed: Lloyd RV, Osamaru RY, Klöppel G, et al. WHO Classification of Tumours of Endocrine Organs. IARC, Lyon, 2017.

Continued

Version 3.2025, 10/01/2025 © 2025 National Comprehensive Cancer Network® (NCCN®), All rights reserved. NCCN Guidelines® and this illustration may not be reproduced in any form without the express written permission of NCCN.

PLEASE NOTE that use of this NCCN Content is governed by the End-User License Agreement, and you MAY NOT distribute this Content or use it with any artificial intelligence model or tool.
Printed by Galya Basol Kochav on 1/7/2026 1:55:52 PM. Copyright © 2026 National Comprehensive Cancer Network, Inc. All Rights Reserved.

Updates in Version 1.2025 of the NCCN Guidelines for Neuroendocrine and Adrenal Tumors from Version 5.2024 include:

NE-D 1 of 3
- Functional Imaging:
  - First bullet, second sub-bullet revised: *Examples of a*ppropriate SSTR-PET tracers*:* ~~include~~ 68Ga-DOTATATE, 68Ga-DOTATOC, or 64Cu-DOTATATE.
  - Fourth bullet revised: ~~In selected cases where high-grade NET or PDNEC is documented or suspected or where disease is growing rapidly, FDG-PET/CT may be useful to identify high-grade active disease.~~ *FDG-PET should be considered in select cases where G2 or higher NETs or NECs is documented*.

NE-E 2 of 4
- Testing column:
  - Pituitary tumor:
    - Bullets revised:
      - Third bullet: Luteinizing hormone (LH)/follicle-stimulating hormone (FSH)*, gonadotrophin with end organ hormone*.
      - Sixth bullet: Plasma ACTH*/random cortisol*.
    - New bullets added:
      - Total and free (or bioavailable) testosterone in those assigned male at birth.
      - Estradiol in premenopausal patients who were assigned female at birth.
      - Overnight dexamethasone suppression test.
      - 24-hour urine for free cortisol when there is clinical evidence of Cushing syndrome.
  - Suspected or confirmed ACC, new bullet added: 24-hour urine for free cortisol when there is clinical evidence of Cushing syndrome.

NE-F 1 of 3
- Last bullet revised: In the setting of metastatic disease, resection of ~~small bowel~~ *ileum/jejunum* NET*s* (primary tumor*s* and mesenteric lymph nodes) should be performed when symptoms arise from the primary tumor...

NE-F 2 of 3
- First bullet, new sub-bullet added: Parenchymal sparing surgery, including enucleation of liver metastases ± ablation, is preferred to preserve as much liver parenchyma as possible.
- Sixth bullet revised: All patients who undergo a splenectomy should receive ~~trivalent vaccine~~ *vaccination against encapsulated bacterium* (ie, pneumococcus, haemophilus influenzae b, meningococcal group C). *These vaccinations should be administered at least 14 days before elective splenectomy, if possible. If the vaccinations are not administered before surgery, they should be administered after the procedure as soon as the patient's condition is stable*.

NE-H 1 of 12
- Preferred Regimens, new option added: First-line PRRT with lutetium Lu 177 dotatate (if SSTR-positive, Ki-67 ≥10%, and clinically significant tumor burden).

NE-H 3 of 12
- Preferred Regimens, new option added: First-line PRRT with lutetium Lu 177 dotatate (if SSTR-positive, Ki-67 ≥10%, and clinically significant tumor burden).

Continued

Version 3.2025, 10/01/2025 © 2025 National Comprehensive Cancer Network® (NCCN®), All rights reserved. NCCN Guidelines® and this illustration may not be reproduced in any form without the express written permission of NCCN.

PLEASE NOTE that use of this NCCN Content is governed by the End-User License Agreement, and you MAY NOT distribute this Content or use it with any artificial intelligence model or tool.
Printed by Galya Basol Kochav on 1/7/2026 1:55:52 PM. Copyright © 2026 National Comprehensive Cancer Network, Inc. All Rights Reserved.

Updates in Version 1.2025 of the NCCN Guidelines for Neuroendocrine and Adrenal Tumors from Version 5.2024 include:

NE-H 5 of 12
- First column:
  - New header added: Favorable Biology (eg, relatively low Ki-67 [<55%], slow growing, positive SSTR-based PET imaging).
  - Sub-header revised: Locally Advanced/Metastatic Disease ~~with Favorable Biology~~ (Unresectable with Clinically Significant Tumor Burden or Evidence of Disease Progression).
- Second column:
  - New header added: Unfavorable Biology (eg, relatively high Ki-67 [≥55%], faster growing, negative SSTR-based PET imaging).
  - Sub-headers revised:
    - Locoregional Disease (Resectable) ~~with Unfavorable Biology~~.
    - Locally Advanced/Metastatic Disease ~~with Unfavorable Biology~~.
- New footnote m added: There are limitations in terms of the data for what the appropriate cutoff should be, as well as variability/heterogeneity of Ki-67 in a given tumor and over time in serial biopsies. The clinical course can be heterogeneous and treatment considerations need to account for both pathologic and clinical features.
- Footnote removed: Consider trial of SSA before PRRT. Preliminary data suggest reduced efficacy if high Ki-67 and/or FDG-PET avid.

NE-H 7 of 12
- Footnotes revised:
  - Footnote s: Entrectinib ~~and~~, larotrectinib, *and repotrectinib* can be considered for patients with NTRK gene fusion-positive tumors without a known acquired resistance mutation, that are metastatic or where surgical resection is likely to result in severe morbidity, and that have no satisfactory alternative treatments or that have progressed following treatment.
  - Footnote t: Repotrectinib can *also* be considered for patients with NTRK gene fusion-positive tumors that progressed on a prior NTRK-targeted treatment.

NE-H 8 of 12
- Other Recommended Regimens, new option added: Cabozantinib
- Useful in Certain Circumstances:
  - New options added:
    - Nivolumab + ipilimumab
    - Osilodrostat (for symptom control)
  - Option removed: None
- Footnote p added to this page: Nivolumab and hyaluronidase-nvhy is not approved for concurrent use with IV ipilimumab; however, for nivolumab monotherapy, nivolumab and hyaluronidase-nvhy subcutaneous injection may be substituted for IV nivolumab. Nivolumab and hyaluronidase-nvhy has different dosing and administration instructions compared to IV nivolumab.
- New footnote y added: Studies have demonstrated efficacy in the setting of cortisol excess in states like adrenal adenomas, adrenal carcinomas, and ectopic ACTH syndrome.

Continued

Version 3.2025, 10/01/2025 © 2025 National Comprehensive Cancer Network® (NCCN®), All rights reserved. NCCN Guidelines® and this illustration may not be reproduced in any form without the express written permission of NCCN.

PLEASE NOTE that use of this NCCN Content is governed by the End-User License Agreement, and you MAY NOT distribute this Content or use it with any artificial intelligence model or tool.
Printed by Galya Basol Kochav on 1/7/2026 1:55:52 PM. Copyright © 2026 National Comprehensive Cancer Network, Inc. All Rights Reserved.

Updates in Version 1.2025 of the NCCN Guidelines for Neuroendocrine and Adrenal Tumors from Version 5.2024 include:

NE-H 9 of 12
- Locally Unresectable and Distant Metastases, new options added:
  - Cabozantinib
  - Selpercatinib
- New footnote u added: Selpercatinib can be considered for patients with RET gene fusion-positive tumors that have progressed on or following prior systemic treatment or who have no satisfactory alternative treatment options.

NE-H 10 of 12
- New reference 4 added: Singh S, Halperin D, Myrehaug S, et al. [177Lu]Lu-DOTA-TATE plus long-acting octreotide versus high-dose long-acting octreotide for the treatment of newly diagnosed, advanced grade 2-3, well-differentiated, gastroenteropancreatic neuroendocrine tumours (NETTER-2): An open-label, randomised, phase 3 study. Lancet 2024;403:2807-2817.
- Reference 9 updated: ~~Horsch D, Baudin E, Singh S, et al. Lanreotide autogel/depot (LAN) in patients with advanced bronchopulmonary (BP) neuroendocrine tumors (NETs): Results from the phase III SPINET study [abstract]. Ann Oncol 2021;32:S960.~~ *Baudin E, Capdevila J, Hörsch D, et al. Treatment of advanced BP-NETS with lanreotide autogel/depot vs placebo: the phase III SPINET study. Endocr Relat Cancer 2024;31:e230337*.

NE-H 11 of 12
- New references added:
  - Reference 44: Campbell MT, Balderrama-Brondani V, Jimenez C, et al. Cabozantinib monotherapy for advanced adrenocortical carcinoma: A single arm, phase 2 trial. Lancet Oncol 2024;25:649-657.
  - Reference 47: Patel SP, Othus M, Chae YK, et al. Phase II basket trial of dual anti-CTLA-4 and anti-PD-1 blockade in rare tumors (DART) SWOG S1609: Adrenocortical carcinoma cohort. J Immunother Cancer 2024;12:e009074.
  - Reference 48: Pivonello R, Simeoli C, Di Paola N, et al. Osilodrostat: A novel potent inhibitor of 11-beta-hydroxylase for the treatment of Cushing's syndrome. touchREV Endocrinol 2024;20:43-51.
  - Reference 49: Fleseriu M, Biller BMK. Treatment of Cushing's syndrome with osilodrostat: Practical applications of recent studies with case examples. Pituitary 2022;25:795-809.
- References 32 updated: ~~Borghesani M, Reni A, Zaninotto E, et al. Outcomes of upfront treatment with mFOLFIRINOX regimen in G3 GEP-NENs: A monocentric retrospective experience. Paper presented at: 18th Annual ENETS Conference for the Diagnosis and Treatment of Neuroendocrine Tumor Disease; February 25-27, 2021; Virtual Conference.~~ *Borghesani M, Reni A, Lauricella E, et al. Efficacy and toxicity analysis of mFOLFIRINOX in high-grade gastroenteropancreatic neuroendocrine neoplasms. J Natl Compr Canc Netw 2024;22:e247005*.

NE-H 12 of 12
- New reference 50 added: Jimenez C, Habra MA, Campbell MT, et al. Cabozantinib in patients with unresectable and progressive metastatic phaeochromocytoma or paraganglioma (the Natalie trial): A single-arm, phase 2 trial. Lancet Oncol 2024;25:658-667.
- Reference 51 updated: ~~Baudin E, Goichot B, Berruti A, et al. First international randomized study in malignant progressive pheochromocytoma and paragangliomas (FIRSTMAPP): An academic double-blind trial investigating sunitinib [abstract]. Ann Oncol 2021;32:S621.~~ *Baudin E, Goichot B, Berruti A, et al. Sunitinib for metastatic progressive phaeochromocytomas and paragangliomas: results from FIRSTMAPPP, an academic, multicentre, international, randomised, placebo controlled, double-blind, phase 2 trial. Lancet 2024;403:1061-1070*.

Continued

Version 3.2025, 10/01/2025 © 2025 National Comprehensive Cancer Network® (NCCN®), All rights reserved. NCCN Guidelines® and this illustration may not be reproduced in any form without the express written permission of NCCN.

PLEASE NOTE that use of this NCCN Content is governed by the End-User License Agreement, and you MAY NOT distribute this Content or use it with any artificial intelligence model or tool.
Printed by Galya Basol Kochav on 1/7/2026 1:55:52 PM. Copyright © 2026 National Comprehensive Cancer Network, Inc. All Rights Reserved.

Updates in Version 1.2025 of the NCCN Guidelines for Neuroendocrine and Adrenal Tumors from Version 5.2024 include:

NE-L 1 of 3
- Carcinoid Syndrome, new bullet added: Therapeutic levels of octreotide would not be expected to be reached for 10–14 days after LAR injections. Short-acting SC octreotide PRN can help address suboptimal symptom control quickly.

ST-6 to ST-10
- Staging table for Lung was updated to Version 9, 2024.

ST-11 to ST-12
- Staging table for Thymus was updated to Version 9, 2024.

Version 3.2025, 10/01/2025 © 2025 National Comprehensive Cancer Network® (NCCN®), All rights reserved. NCCN Guidelines® and this illustration may not be reproduced in any form without the express written permission of NCCN.

PLEASE NOTE that use of this NCCN Content is governed by the End-User License Agreement, and you MAY NOT distribute this Content or use it with any artificial intelligence model or tool.
Printed by Galya Basol Kochav on 1/7/2026 1:55:52 PM. Copyright © 2026 National Comprehensive Cancer Network, Inc. All Rights Reserved.

CLINICAL PRESENTATIONS AND DIAGNOSIS[a]

Neuroendocrine Tumors (NETs) of the Gastrointestinal Tract (Well-Differentiated Grade 1/2), Lung, and Thymus
Clinical presentations:
- Jejunal, ileal, colon (NET-1)
- Duodenal (NET-2)
- Appendix (NET-3)
- Rectal (NET-4)
- Gastric (NET-5)
- Lung (NET-6)
- Thymus (NET-7)
- Locoregional advanced disease and/or distant metastases of the gastrointestinal (GI) tract (NET-9)
- Locoregional unresectable lung/thymic NETs (NET-11)
- Distant metastatic lung/thymic NETs (NET-12)
- Carcinoid syndrome (NET-13)

Neuroendocrine Tumors of the Pancreas (Well-Differentiated Grade 1/2)
Clinical presentations:
- Nonfunctioning pancreatic tumors (PanNET-1)
- Gastrinoma (PanNET-3)
- Insulinoma (PanNET-5)
- Glucagonoma (PanNET-7)
- VIPoma (PanNET-9)
- Locoregional advanced disease and/or distant metastases (PanNET-12)

Neuroendocrine Neoplasms of Unknown Primary (NUP-1)

Well-Differentiated, Grade 3 Neuroendocrine Tumors (WDG3-1)

Extrapulmonary Poorly Differentiated: Neuroendocrine Carcinoma/Large or Small Cell Carcinoma/Mixed Neuroendocrine-Non-Neuroendocrine Neoplasm (MiNEN) (PDNEC-1)

Adrenal Gland Tumors (AGT-1)[b]

Pheochromocytoma (PCC)/Paraganglioma (PGL) (PHEO-1)

Multiple Endocrine Neoplasia, Type 1 (MEN1) (MEN1-1)
- Parathyroid
- Pancreatic NETs (PanNETs)
- Pituitary tumor
- Lung/thymic NETs

Multiple Endocrine Neoplasia, Type 2 (MEN2) (MEN2-1)
- Medullary thyroid carcinoma (Also see NCCN Guidelines for Thyroid Carcinoma)
- Parathyroid
- PCC

Merkel Cell Carcinoma (See NCCN Guidelines for Merkel Cell Carcinoma)

[a] Principles of Pathology for the Diagnosis of Neuroendocrine Neoplasms (NE-A).
[b] Includes adrenocortical tumors and incidentalomas.

Note: All recommendations are category 2A unless otherwise indicated.

Version 3.2025, 10/01/2025 © 2025 National Comprehensive Cancer Network® (NCCN®), All rights reserved. NCCN Guidelines® and this illustration may not be reproduced in any form without the express written permission of NCCN.

PLEASE NOTE that use of this NCCN Content is governed by the End-User License Agreement, and you MAY NOT distribute this Content or use it with any artificial intelligence model or tool.
Printed by Galia Basovich-Gendler on 10/10/2025 15:52:57 © 2025 National Comprehensive Cancer Network, Inc. All Rights Reserved.

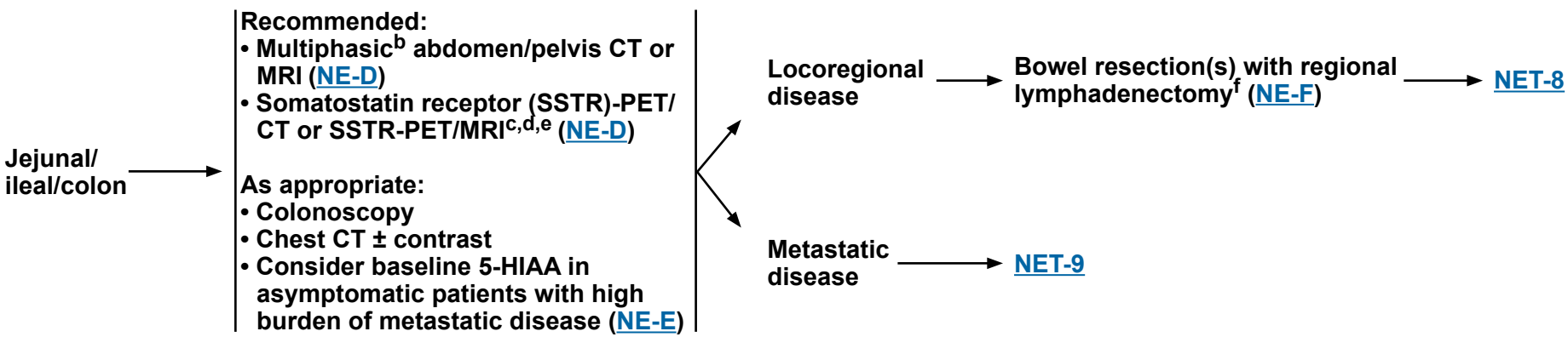

[a] Principles of Pathology for the Diagnosis of Neuroendocrine Neoplasms (NE-A).
[b] Multiphasic imaging studies are performed with intravenous (IV) contrast in arterial and portal venous phases.
[c] SSTR-PET/CT or SSTR-PET/MRI of skull vertex to mid-thigh with multiphase IV contrast when possible. Data are limited on the optimal timing of scans following administration of somatostatin analogs (SSAs).
[d] SSTR-PET tracers (eg, 68Ga-DOTATATE, 64Cu-DOTATATE, and 68Ga-DOTATOC).
[e] SSTR-PET/CT or SSTR-PET/MRI should not be used to limit the extent of lymphadenectomy or small bowel resection as sensitivity may not be adequate.
[f] Should include:
- Manual palpation of the entire bowel, as synchronous tumors may be present.
- Assess for proximity to or involvement of the superior mesenteric artery and vein.

Note: All recommendations are category 2A unless otherwise indicated.

Version 3.2025, 10/01/2025 © 2025 National Comprehensive Cancer Network® (NCCN®), All rights reserved. NCCN Guidelines® and this illustration may not be reproduced in any form without the express written permission of NCCN.

PLEASE NOTE that use of this NCCN Content is governed by the End-User License Agreement, and you MAY NOT distribute this Content or use it with any artificial intelligence model or tool.
Printed by Galia Rasgoniokar on 10/29/2025 15:52 EDT. Copyright © 2025 National Comprehensive Cancer Network, Inc. All Rights Reserved.

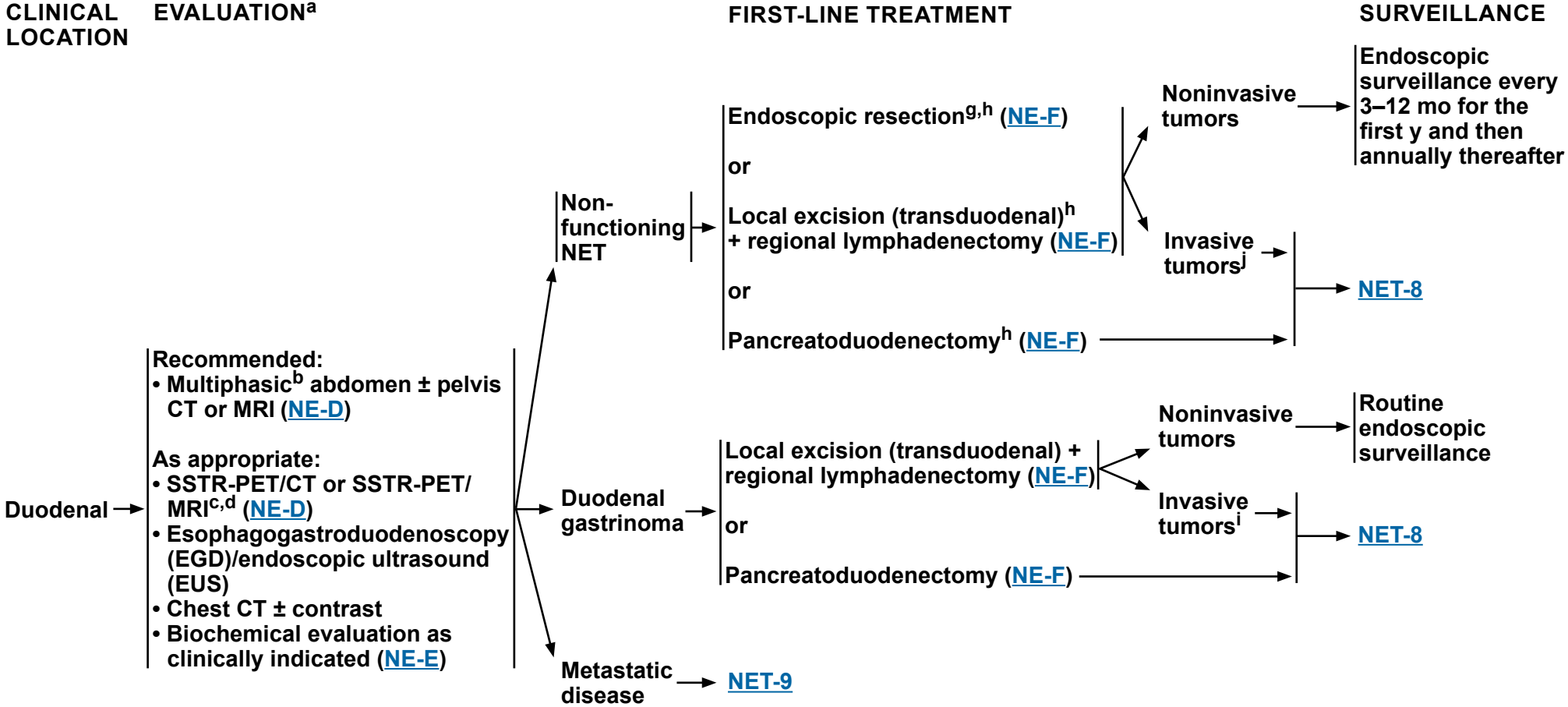

[a] Principles of Pathology for the Diagnosis of Neuroendocrine Neoplasms (NE-A).
[b] Multiphasic imaging studies are performed with IV contrast in arterial and portal venous phases.
[c] SSTR-PET/CT or SSTR-PET/MRI of skull vertex to mid-thigh with multiphase IV contrast when possible. Data are limited on the optimal timing of scans following administration of SSAs.
[d] SSTR-PET tracers (eg, 68Ga-DOTATATE, 64Cu-DOTATATE, and 68Ga-DOTATOC).
[g] If endoscopic resection performed, follow-up EGD as appropriate.
[h] For non-ampullary tumors, endoscopic or local excision is preferred. Pancreatoduodenectomy should be considered for ampullary tumors not amenable to endoscopic or local excision.
[i] Invasion into muscle (Staging, ST-2).

Note: All recommendations are category 2A unless otherwise indicated.

Version 3.2025, 10/01/2025 © 2025 National Comprehensive Cancer Network® (NCCN®), All rights reserved. NCCN Guidelines® and this illustration may not be reproduced in any form without the express written permission of NCCN.

PLEASE NOTE that use of this NCCN Content is governed by the End-User License Agreement, and you MAY NOT distribute this Content or use it with any artificial intelligence model or tool.
Printed by Galia Bassochman on 10/09/2025 15:52 EDT. Copyright © 2025 National Comprehensive Cancer Network, Inc. All Rights Reserved.

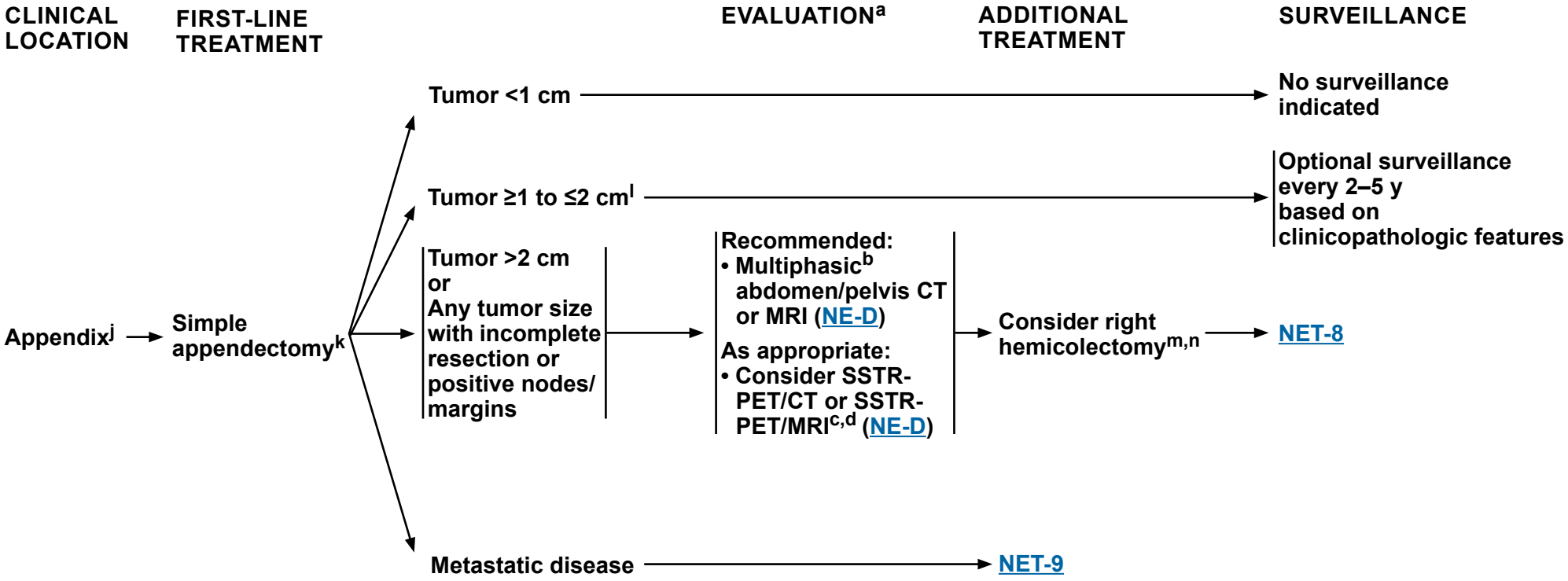

[a] Principles of Pathology for the Diagnosis of Neuroendocrine Neoplasms (NE-A).
[b] Multiphasic imaging studies are performed with IV contrast in arterial and portal venous phases.
[c] SSTR-PET/CT or SSTR-PET/MRI of skull vertex to mid-thigh with multiphase IV contrast when possible. Data are limited on the optimal timing of scans following administration of SSAs.
[d] SSTR-PET tracers (eg, 68Ga-DOTATATE, 64Cu-DOTATATE, and 68Ga-DOTATOC).
[j] Some appendiceal NETs will have mixed histology, including elements of adenocarcinoma. Such tumors should be managed according to colon cancer guidelines. See NCCN Guidelines for Colon Cancer.
[k] See Staging (ST-3). Some NCCN Member Institutions consider right hemicolectomy for 1- to 2-cm tumors with poor prognostic features. See Discussion for details.
[l] Ahmed FA, et al. Surgery 2024;175:251-257; Nesti C, et al. Lancet Oncol 2023;24:187-194.
[m] Greater than 12 lymph nodes should be retrieved.
[n] Data are limited on survival benefit from right hemicolectomy.

Note: All recommendations are category 2A unless otherwise indicated.

Version 3.2025, 10/01/2025 © 2025 National Comprehensive Cancer Network® (NCCN®), All rights reserved. NCCN Guidelines® and this illustration may not be reproduced in any form without the express written permission of NCCN.

PLEASE NOTE that use of this NCCN Content is governed by the End-User License Agreement, and you MAY NOT distribute this Content or use it with any artificial intelligence model or tool.
Printed by Galia Basso Moreno on 10/09/2025 15:52 EDT. Copyright © 2025 National Comprehensive Cancer Network, Inc. All Rights Reserved.

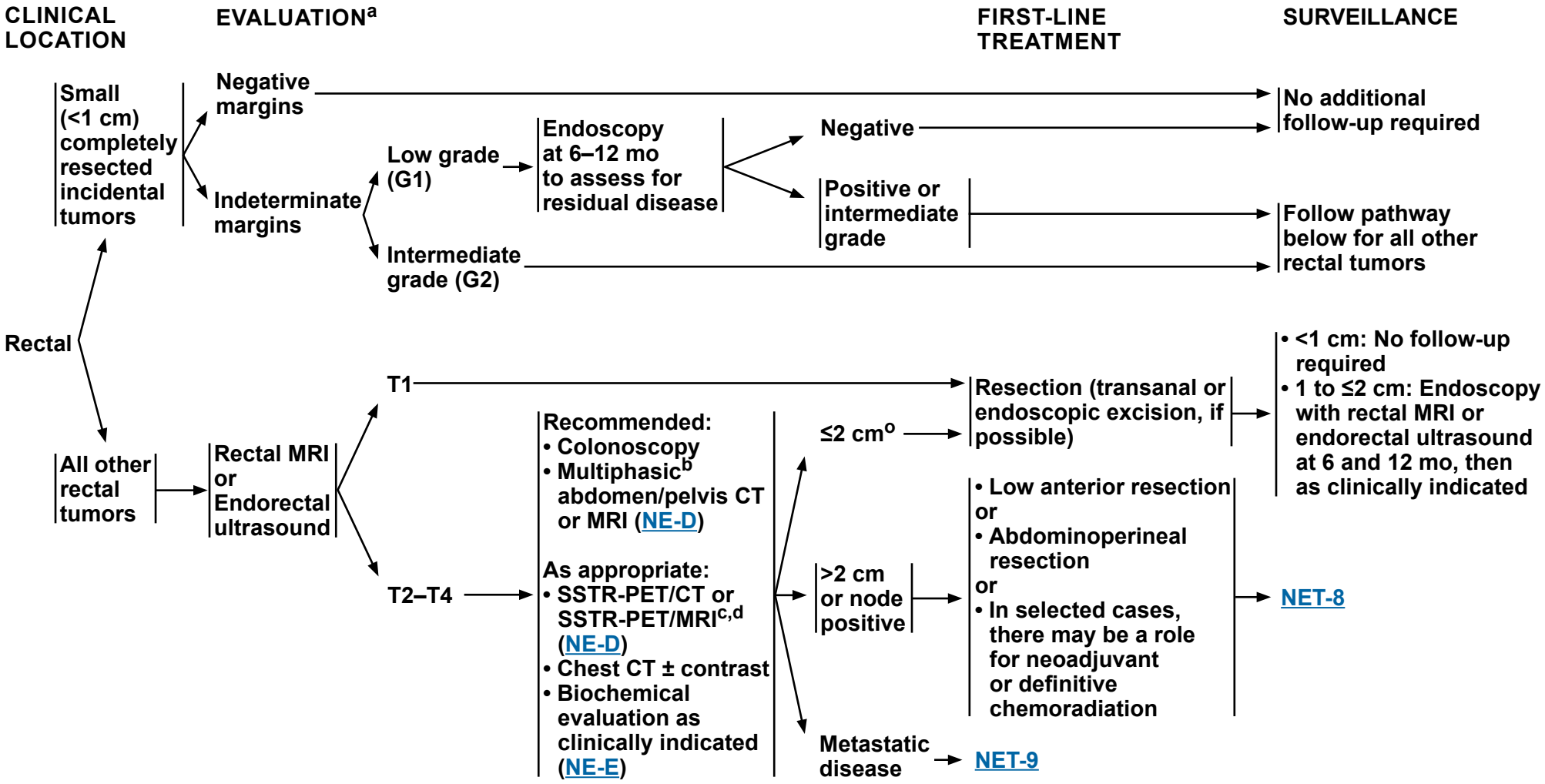

[a] Principles of Pathology for the Diagnosis of Neuroendocrine Neoplasms (NE-A).
[b] Multiphasic imaging studies are performed with IV contrast in arterial and portal venous phases.
[c] SSTR-PET/CT or SSTR-PET/MRI of skull vertex to mid-thigh with multiphase IV contrast when possible. Data are limited on the optimal timing of scans following administration of SSAs.
[d] SSTR-PET tracers (eg, 68Ga-DOTATATE, 64Cu-DOTATATE, and 68Ga-DOTATOC).
[o] For 1- to 2-cm tumors, consider examination under anesthesia and/or EUS with radical resection if muscularis propria invasion or node positive.

Note: All recommendations are category 2A unless otherwise indicated.

Version 3.2025, 10/01/2025 © 2025 National Comprehensive Cancer Network® (NCCN®), All rights reserved. NCCN Guidelines® and this illustration may not be reproduced in any form without the express written permission of NCCN.

PLEASE NOTE that use of this NCCN Content is governed by the End-User License Agreement, and you MAY NOT distribute this Content or use it with any artificial intelligence model or tool.
Printed by Galia Basovich-Gendler on 10/29/2025 5:52 PM. Copyright © 2025 National Comprehensive Cancer Network, Inc. All Rights Reserved.

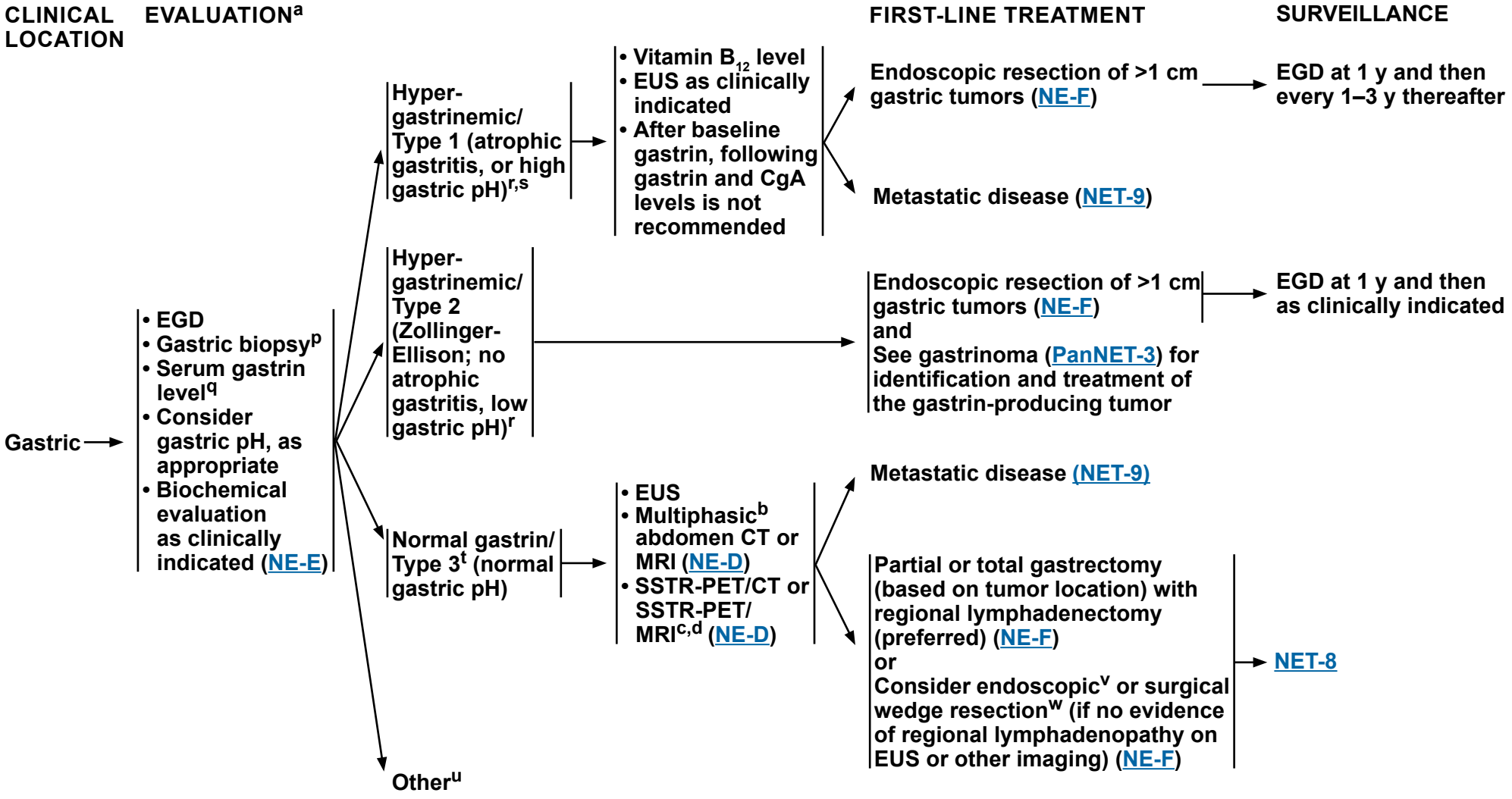

Footnotes on NET-5A

Note: All recommendations are category 2A unless otherwise indicated.

Version 3.2025, 10/01/2025 © 2025 National Comprehensive Cancer Network® (NCCN®), All rights reserved. NCCN Guidelines® and this illustration may not be reproduced in any form without the express written permission of NCCN.

PLEASE NOTE that use of this NCCN Content is governed by the End-User License Agreement, and you MAY NOT distribute this Content or use it with any artificial intelligence model or tool.
Printed by Galia Basovich-Gendler on 10/10/2025 15:52:57. Copyright © 2025 National Comprehensive Cancer Network, Inc. All Rights Reserved.

FOOTNOTES

[a] Principles of Pathology for the Diagnosis of Neuroendocrine Neoplasms (NE-A).
[b] Multiphasic imaging studies are performed with IV contrast in arterial and portal venous phases.
[c] SSTR-PET/CT or SSTR-PET/MRI of skull vertex to mid-thigh with multiphase IV contrast when possible. Data are limited on the optimal timing of scans following administration of SSAs.
[d] SSTR-PET tracers (eg, 68Ga-DOTATATE, 64Cu-DOTATATE, and 68Ga-DOTATOC).
[p] May need multiple biopsies throughout the entire stomach.
[q] Serum gastrin can be falsely elevated with proton pump inhibitor (PPI) use. To confirm diagnosis, it should ideally be checked when fasting and off PPI for >1 week. However, PPI should be continued in patients with overt clinical symptoms of gastrinoma and/or risks of complications.
[r] Elevated gastrin levels are usually suggestive of type 1 or type 2 tumors.
[s] For rare, >2 cm, type 1 gastric tumors, workup should include multiphasic CT or MRI of the abdomen. For metastatic disease, see NET-12.
[t] Type 3 gNETs are sporadic and unifocal.
[u] There is increasing evidence that patients who have been on long-term PPI therapy may be at an increased risk of developing gastric NETs (gNETs), which appear to have a much lower propensity to metastasize than sporadic type 3 tumors.
[v] Hirasawa T, et al. Dig Endosc 2021;33:408-417.
[w] Endoscopic resection should be reserved for small (<1 cm), superficial, low-grade tumors.

Note: All recommendations are category 2A unless otherwise indicated.

Version 3.2025, 10/01/2025 © 2025 National Comprehensive Cancer Network® (NCCN®), All rights reserved. NCCN Guidelines® and this illustration may not be reproduced in any form without the express written permission of NCCN.

PLEASE NOTE that use of this NCCN Content is governed by the End-User License Agreement, and you MAY NOT distribute this Content or use it with any artificial intelligence model or tool.
Printed by Galia Bassochkin on 10/29/2025 15:52 EDT. Copyright © 2025 National Comprehensive Cancer Network, Inc. All Rights Reserved.

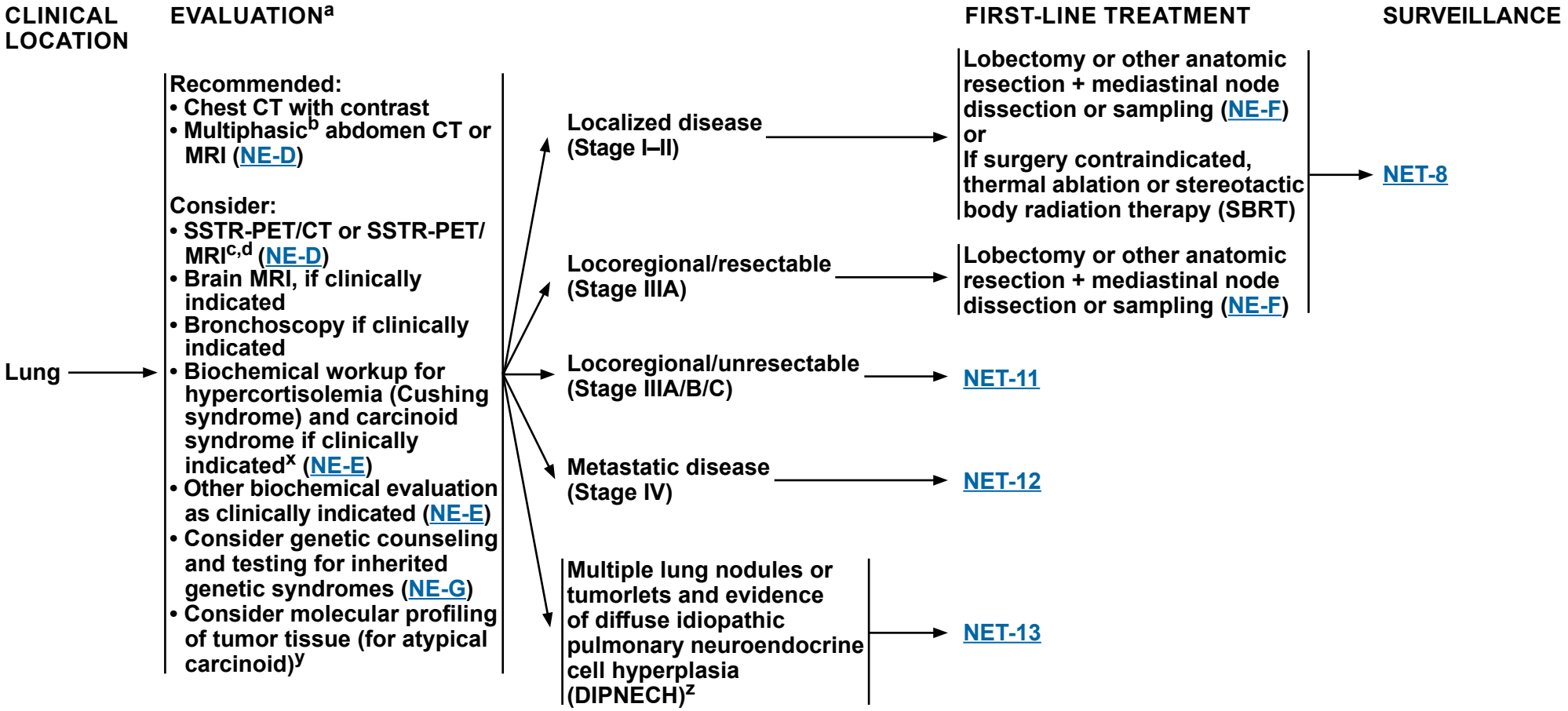

[a] Principles of Pathology for the Diagnosis of Neuroendocrine Neoplasms (NE-A).
[b] Multiphasic imaging studies are performed with IV contrast in arterial and portal venous phases.
[c] SSTR-PET/CT or SSTR-PET/MRI of skull vertex to mid-thigh with multiphase IV contrast when possible. Data are limited on the optimal timing of scans following administration of SSAs.
[d] SSTR-PET tracers (eg, 68Ga-DOTATATE, 64Cu-DOTATATE, and 68Ga-DOTATOC).
[x] If hypercortisolemia (Cushing syndrome) is suspected, assess for and treat ectopic sources of adrenocorticotropic hormone (ACTH) production.
[y] Tumor/somatic molecular profiling should be considered for patients with locoregional unresectable/metastatic disease who are candidates for anticancer therapy to identify actionable alterations. Testing on tumor tissue is preferred; however, liquid biopsy can be considered if tumor tissue testing is not feasible.
[z] Discussion.

Note: All recommendations are category 2A unless otherwise indicated.

Version 3.2025, 10/01/2025 © 2025 National Comprehensive Cancer Network® (NCCN®), All rights reserved. NCCN Guidelines® and this illustration may not be reproduced in any form without the express written permission of NCCN.

PLEASE NOTE that use of this NCCN Content is governed by the End-User License Agreement, and you MAY NOT distribute this Content or use it with any artificial intelligence model or tool.
Printed by Galia Basovich-Gendler on 10/29/2025 15:52 EDT. Copyright © 2025 National Comprehensive Cancer Network, Inc. All Rights Reserved.

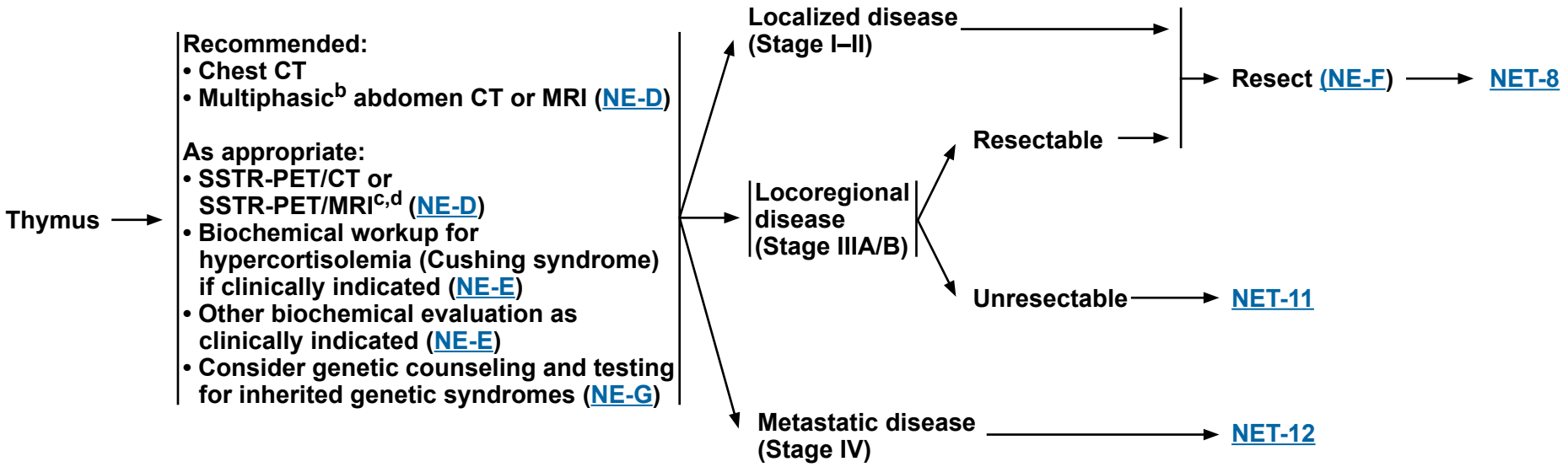

[a] Principles of Pathology for the Diagnosis of Neuroendocrine Neoplasms (NE-A).
[b] Multiphasic imaging studies are performed with IV contrast in arterial and portal venous phases.
[c] SSTR-PET/CT or SSTR-PET/MRI of skull vertex to mid-thigh with multiphase IV contrast when possible. Data are limited on the optimal timing of scans following administration of SSAs.
[d] SSTR-PET tracers (eg, 68Ga-DOTATATE, 64Cu-DOTATATE, and 68Ga-DOTATOC).

Note: All recommendations are category 2A unless otherwise indicated.

Version 3.2025, 10/01/2025 © 2025 National Comprehensive Cancer Network® (NCCN®), All rights reserved. NCCN Guidelines® and this illustration may not be reproduced in any form without the express written permission of NCCN.

PLEASE NOTE that use of this NCCN Content is governed by the End-User License Agreement, and you MAY NOT distribute this Content or use it with any artificial intelligence model or tool.
Printed by Galia Basovich-Gendler on 10/29/2025 15:52 EDT. Copyright © 2025 National Comprehensive Cancer Network, Inc. All Rights Reserved.

SURVEILLANCE[aa,bb,cc] GI TRACT, LUNG, AND THYMUS

12 wk–12 mo post-resection:
- History and physical (H&P)
- For functional tumors, follow-up with biochemical markers as clinically indicated (NE-E)
- Multiphasic[b] abdomen ± pelvis CT or MRI for primary GI NETs (as clinically indicated for lung and thymic NETs) (NE-D)
- Chest CT + CT or MRI abdomen with contrast for primary lung/thymic NETs (as clinically indicated for primary GI tumors)

>1 y post-resection to 10 y:
- Every 12–24 mo
  - H&P
  - For functional tumors, follow-up with biochemical markers as clinically indicated (NE-E)
  - Multiphasic[b] abdomen ± pelvis CT or MRI for primary GI NETs (as clinically indicated for lung and thymic NETs) (NE-D)
  - Chest/abdomen CT with contrast for primary lung/thymic NETs (as clinically indicated for primary GI tumors)

>10 y:
- Consider surveillance as clinically indicated[dd] (NE-D)

RECURRENT DISEASE

Disease recurrence[ee]

- GI tract → NET-9
- Lung/thymus → Locoregional unresectable (NET-11) or Distant metastases (NET-12)
- Carcinoid syndrome → NET-14

MANAGEMENT OF RECURRENT DISEASE[ff]

[b] Multiphasic imaging studies are performed with IV contrast in arterial and portal venous phases.
[aa] Earlier, if symptoms. If initial scans are negative, the frequency of follow-up scans may decrease.
[bb] SSTR-based imaging and fluorodeoxyglucose (FDG)-PET/CT scan are not recommended for routine surveillance.
[cc] NCCN Guidelines for Survivorship.
[dd] Singh S, et al. JAMA Oncol 2018;4:1597-1604.
[ee] In select cases, resection may be considered.
[ff] Principles of Surgical Management of Neuroendocrine Tumors (NE-F).

Note: All recommendations are category 2A unless otherwise indicated.

Version 3.2025, 10/01/2025 © 2025 National Comprehensive Cancer Network® (NCCN®), All rights reserved. NCCN Guidelines® and this illustration may not be reproduced in any form without the express written permission of NCCN.

PLEASE NOTE that use of this NCCN Content is governed by the End-User License Agreement, and you MAY NOT distribute this Content or use it with any artificial intelligence model or tool.
Printed by Galia Basso Moreira on 10/02/2025 15:52 EDT. Copyright © 2025 National Comprehensive Cancer Network, Inc. All Rights Reserved.

MANAGEMENT OF LOCOREGIONAL ADVANCED DISEASE AND/OR DISTANT METASTASES OF THE GASTROINTESTINAL TRACT

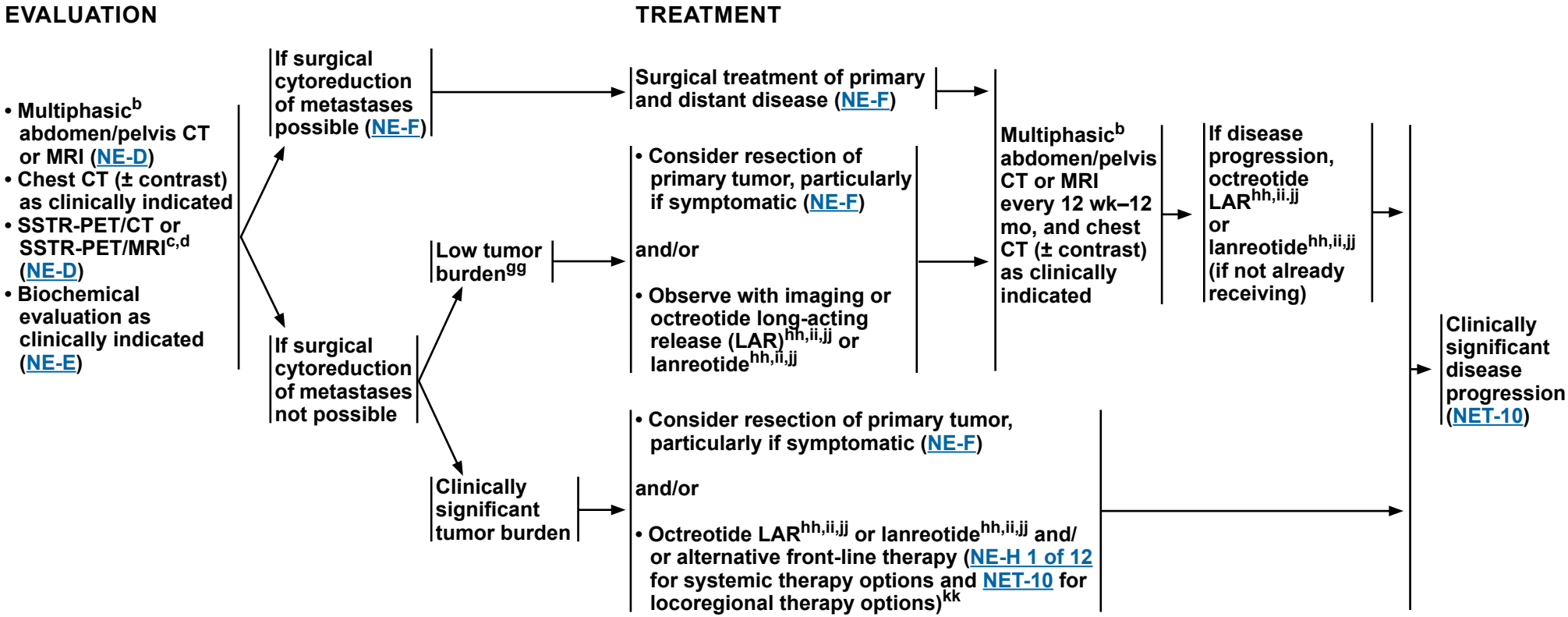

[b] Multiphasic imaging studies are performed with IV contrast in arterial and portal venous phases.
[c] SSTR-PET/CT or SSTR-PET/MRI of skull vertex to mid-thigh with multiphase IV contrast when possible. Data are limited on the optimal timing of scans following administration of SSAs.
[d] SSTR-PET tracers (eg, 68Ga-DOTATATE, 64Cu-DOTATATE, and 68Ga-DOTATOC).
[gg] Primary + regional lymph node resection should be considered to reduce future obstruction, mesenteric ischemia, bleeding, or perforation.
[hh] For symptom and/or tumor control, octreotide LAR 20–30 mg IM or lanreotide 120 mg SC every 4 weeks. Higher doses have been shown to be safe. For breakthrough symptoms, octreotide 100–250 mcg SC TID can be considered.
[ii] If injection site-related complications occur, consider switching to another SSA.
[jj] Treatment with octreotide LAR or lanreotide will likely be of greatest benefit in patients with SSTR-positive tumors.
[kk] In select cases, it may be appropriate to proceed to front-line systemic therapy or locoregional therapy prior to or concurrently with octreotide LAR or lanreotide.

Note: All recommendations are category 2A unless otherwise indicated.

Version 3.2025, 10/01/2025 © 2025 National Comprehensive Cancer Network® (NCCN®), All rights reserved. NCCN Guidelines® and this illustration may not be reproduced in any form without the express written permission of NCCN.

PLEASE NOTE that use of this NCCN Content is governed by the End-User License Agreement, and you MAY NOT distribute this Content or use it with any artificial intelligence model or tool.
Printed by Galia Rasouli-Ibarra on 10/29/2025 15:52 EDT. Copyright © 2025 National Comprehensive Cancer Network, Inc. All Rights Reserved.

MANAGEMENT OF LOCOREGIONAL ADVANCED DISEASE AND/OR DISTANT METASTASES OF THE GASTROINTESTINAL TRACT

SUBSEQUENT THERAPY

Clinically significant disease progression[ll] →

Systemic therapy (NE-H 1 of 12)

or

Locoregional therapy options
- **Liver-directed therapy for liver-predominant disease (NE-K)**
- **Consider radiation therapy (RT) (NE-I) ± concurrent fluoropyrimidine-based chemotherapy for locally advanced unresectable disease (excluding small bowel mesenteric)**
- **Palliative RT for oligometastatic disease and/or symptomatic metastases (excluding mesenteric masses) (NE-I)**

[ll] If clinically significant disease progression, treatment with octreotide LAR or lanreotide should be discontinued for non-functional tumors and continued in patients with functional tumors; these regimens may be used in combination with any of the subsequent options.

Note: All recommendations are category 2A unless otherwise indicated.

Version 3.2025, 10/01/2025 © 2025 National Comprehensive Cancer Network® (NCCN®), All rights reserved. NCCN Guidelines® and this illustration may not be reproduced in any form without the express written permission of NCCN.

PLEASE NOTE that use of this NCCN Content is governed by the End-User License Agreement, and you MAY NOT distribute this Content or use it with any artificial intelligence model or tool.
Printed by Galia Basso Moreno on 10/29/2025 15:52 EDT. Copyright © 2025 National Comprehensive Cancer Network, Inc. All Rights Reserved.

MANAGEMENT OF LOCOREGIONAL UNRESECTABLE DISEASE: LUNG OR THYMUS

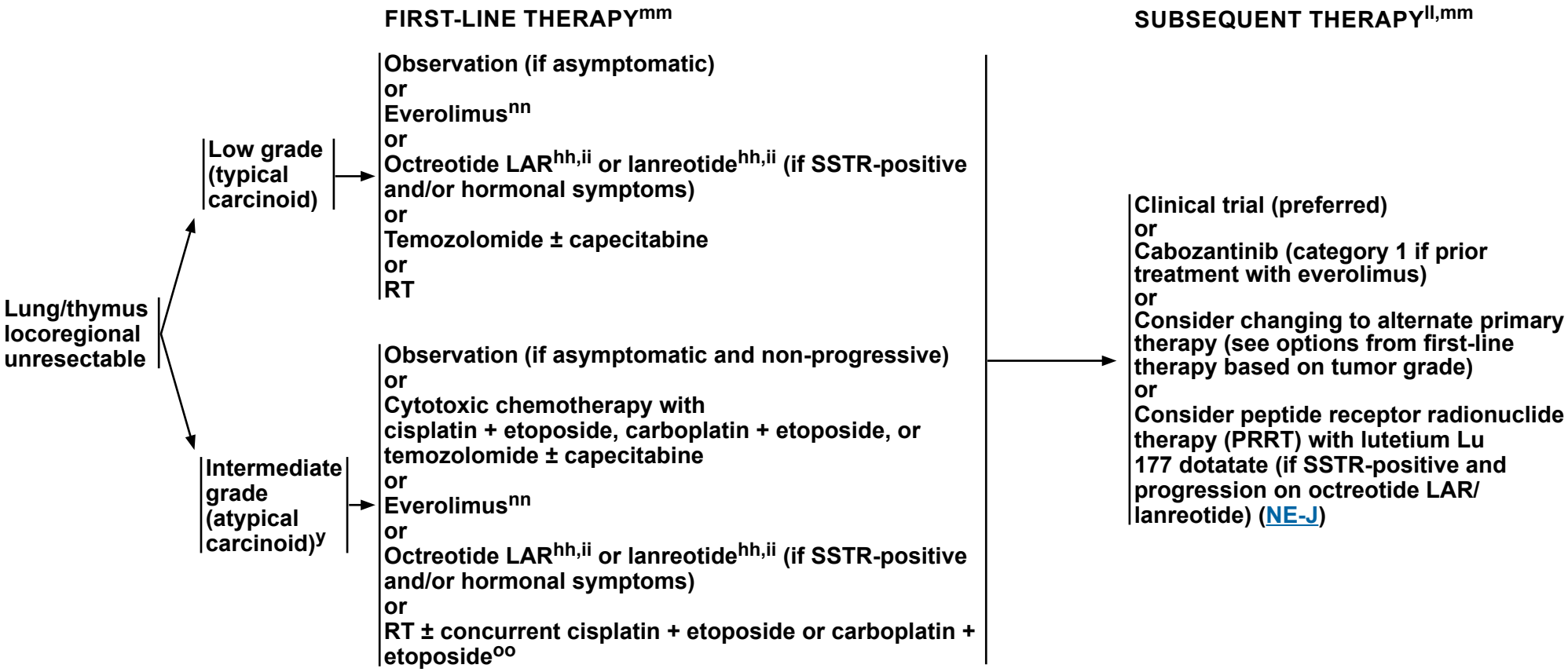

[y] Tumor/somatic molecular profiling should be considered for patients with locoregional unresectable/metastatic disease who are candidates for anticancer therapy to identify actionable alterations. Testing on tumor tissue is preferred; however, liquid biopsy can be considered if tumor tissue testing is not feasible.

[hh] For symptom and/or tumor control, octreotide LAR 20–30 mg IM or lanreotide 120 mg SC every 4 weeks. Higher doses have been shown to be safe. For breakthrough symptoms, octreotide 100–250 mcg SC TID can be considered.

[ii] If injection site-related complications occur, consider switching to another SSA.

[ll] If clinically significant disease progression, treatment with octreotide LAR or lanreotide should be discontinued for non-functional tumors and continued in patients with functional tumors; these regimens may be used in combination with any of the subsequent options.

[mm] For symptom control, consider addition of focal therapy (eg, endobronchial therapy, ablation).

[nn] Phase III study done in non-functional tumors.

[oo] Chemoradiation is thought to have greatest efficacy in tumors with atypical histology or tumors with higher mitotic and proliferative indices (eg, Ki-67).

Note: All recommendations are category 2A unless otherwise indicated.

Version 3.2025, 10/01/2025 © 2025 National Comprehensive Cancer Network® (NCCN®), All rights reserved. NCCN Guidelines® and this illustration may not be reproduced in any form without the express written permission of NCCN.

PLEASE NOTE that use of this NCCN Content is governed by the End-User License Agreement, and you MAY NOT distribute this Content or use it with any artificial intelligence model or tool.
Printed by Galia Basovich-Gendler on 10/29/2025 15:52 EDT. Copyright © 2025 National Comprehensive Cancer Network, Inc. All Rights Reserved.

MANAGEMENT OF DISTANT METASTASES (LUNG OR THYMUS)

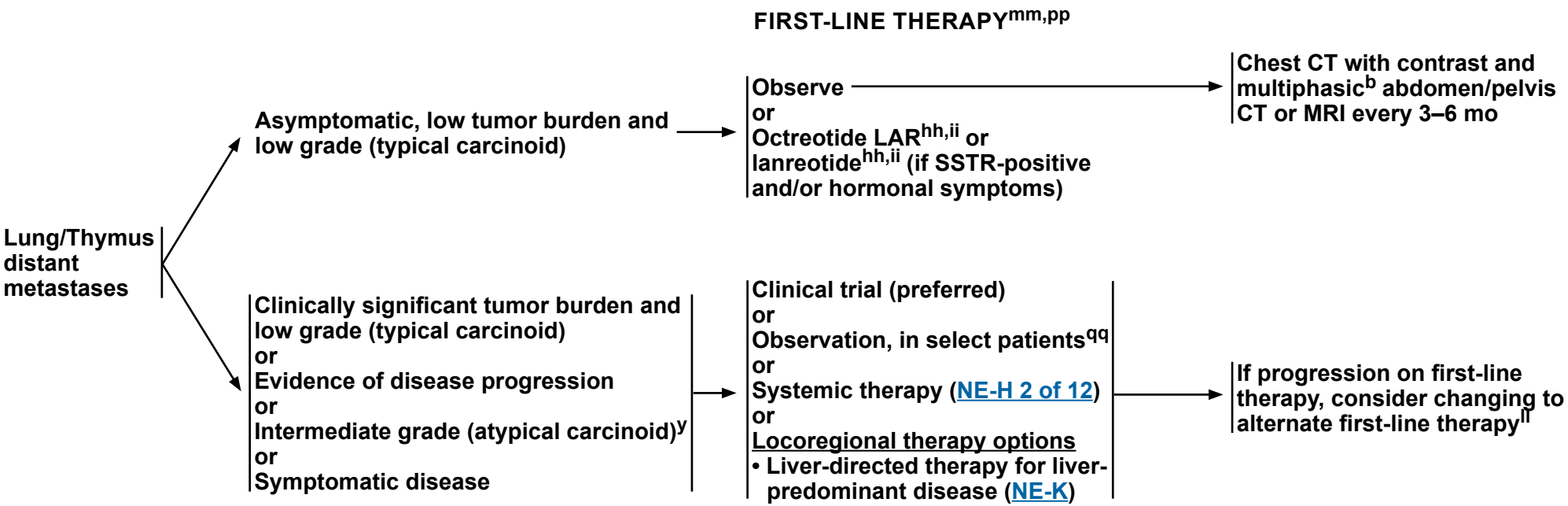

[b] Multiphasic imaging studies are performed with IV contrast in arterial and portal venous phases.
[y] Tumor/somatic molecular profiling should be considered for patients with locoregional unresectable/metastatic disease who are candidates for anticancer therapy to identify actionable alterations. Testing on tumor tissue is preferred; however, liquid biopsy can be considered if tumor tissue testing is not feasible.
[hh] For symptom and/or tumor control, octreotide LAR 20–30 mg IM or lanreotide 120 mg SC every 4 weeks. Higher doses have been shown to be safe. For breakthrough symptoms, octreotide 100–250 mcg SC TID can be considered.
[ii] If injection site-related complications occur, consider switching to another SSA.
[ll] If clinically significant disease progression, treatment with octreotide LAR or lanreotide should be discontinued for non-functional tumors and continued in patients with functional tumors; these regimens may be used in combination with any of the subsequent options.
[mm] For symptom control, consider addition of focal therapy (eg, endobronchial therapy, ablation).
[pp] NETs are highly heterogeneous and all elements need to be considered (eg, burden of disease, symptoms, histopathology, rate of growth) when determining the best course of treatment.
[qq] Observation can be considered in select patients with low burden of disease and favorable prognostic features.

Note: All recommendations are category 2A unless otherwise indicated.

Version 3.2025, 10/01/2025 © 2025 National Comprehensive Cancer Network® (NCCN®), All rights reserved. NCCN Guidelines® and this illustration may not be reproduced in any form without the express written permission of NCCN.

PLEASE NOTE that use of this NCCN Content is governed by the End-User License Agreement, and you MAY NOT distribute this Content or use it with any artificial intelligence model or tool.
Printed by Galia Rasgo Moreno on 10/10/2025 15:52 EDT. Copyright © 2025 National Comprehensive Cancer Network, Inc. All Rights Reserved.

MULTIPLE LUNG NODULES OR TUMORLETS AND EVIDENCE OF DIPNECH

FIRST-LINE TREATMENT

SURVEILLANCE

Multiple lung nodules or tumorlets and evidence of DIPNECH[rr] →

Observe
or
A trial of octreotide LAR[hh,ii] or lanreotide[hh,ii] for symptom control (if chronic cough/dyspnea is not responsive to inhalers or conventional treatment)[ss]

→ **Chest CT (without contrast) every 12–24 mo or as clinically indicated**

[hh] For symptom control, octreotide LAR 20–30 mg IM or lanreotide 120 mg SC every 4 weeks. Higher doses have been shown to be safe. For breakthrough symptoms, octreotide 100–250 mcg SC TID can be considered.
[ii] If injection site-related complications occur, consider switching to another SSA.
[rr] Consider referral to pulmonary medicine for symptom management.
[ss] Almquist D, et al. J Clin Oncol 2019;37:Abstract e20029; Al-Toubah T, et al. Chest 2020;158:401-405.

Note: All recommendations are category 2A unless otherwise indicated.

Version 3.2025, 10/01/2025 © 2025 National Comprehensive Cancer Network® (NCCN®), All rights reserved. NCCN Guidelines® and this illustration may not be reproduced in any form without the express written permission of NCCN.

PLEASE NOTE that use of this NCCN Content is governed by the End-User License Agreement, and you MAY NOT distribute this Content or use it with any artificial intelligence model or tool.
Printed by Galia Basgoudian on 10/29/2025 15:52 EDT. Copyright © 2025 National Comprehensive Cancer Network, Inc. All Rights Reserved.

CARCINOID SYNDROME[tt]

EVALUATION

Recommended:
- Routine biochemical evaluation with 24-hour urine or plasma 5-HIAA (NE-E)
- Baseline echocardiogram
- Imaging to assess disease progression (see NET-8 or NET-9)

TREATMENT

Octreotide LAR[uu,vv] or Lanreotide[uu]

Carcinoid syndrome well controlled → SURVEILLANCE

Carcinoid syndrome poorly controlled →
- If any persistent symptoms (ie, flushing, diarrhea), rule out non-carcinoid syndrome causes[ww]

and
- Consider additional therapy for symptom control:
  - Telotristat for diarrhea (250 mg, by mouth 3 times a day)
  - SC octreotide[vv]

and
- Consider additional therapy for tumor control:
  - Hepatic arterial embolization or cytoreductive surgery for liver-predominant disease

or
  - Other systemic therapy based on disease site[xx] (NE-H)

SURVEILLANCE

- Echocardiogram every 1–3 y or as clinically indicated for patients without carcinoid heart disease (CHD) and at least annually for patients with established CHD (NE-D)
- Multiphasic[b] abdomen/pelvis CT or MRI (NE-D) every 12 wk–12 mo, and chest CT (± contrast) as clinically indicated

ADDITIONAL THERAPY[ll]

If disease progression, see Management of Locoregional Advanced Disease and/or Distant Metastases:
- GI Tract (NET-9)
- Lung/Thymus (NET-11 and NET-12)

[b] Multiphasic imaging studies are performed with IV contrast in arterial and portal venous phases.
[ll] If clinically significant disease progression, treatment with octreotide LAR or lanreotide should be discontinued for non-functional tumors and continued in patients with functional tumors; these regimens may be used in combination with any of the subsequent options.
[tt] Principles of Hormone Control (NE-L).

[uu] For symptom control, octreotide 100–250 mcg SC TID or octreotide LAR 20–30 mg IM or lanreotide 120 mg SC every 4 weeks. Dose and frequency may be further increased for symptom control as needed. Higher doses have been shown to be safe.
[vv] Therapeutic levels of octreotide would not be expected to be reached for 10–14 days after LAR injection. Short-acting octreotide can be added to octreotide LAR or lanreotide for rapid relief of symptoms or for breakthrough symptoms.
[ww] Evaluate for pancreatic exocrine deficiency and bile acid diarrhea.
[xx] Effectiveness of everolimus in the treatment of patients with carcinoid syndrome has not been established.

Note: All recommendations are category 2A unless otherwise indicated.

Version 3.2025, 10/01/2025 © 2025 National Comprehensive Cancer Network® (NCCN®), All rights reserved. NCCN Guidelines® and this illustration may not be reproduced in any form without the express written permission of NCCN.

PLEASE NOTE that use of this NCCN Content is governed by the End-User License Agreement, and you MAY NOT distribute this Content or use it with any artificial intelligence model or tool.
Printed by Galia Basovich-Gendler on 10/10/2025 15:52 EDT. Copyright © 2025 National Comprehensive Cancer Network, Inc. All Rights Reserved.

CLINICAL LOCATION | **EVALUATION[a]**

Nonfunctioning pancreatic tumors (without symptoms secondary to hormone production whether or not hormone levels are elevated)

→

Recommended:
- **Multiphasic[b] abdomen ± pelvis CT or MRI (NE-D)**

As appropriate:
- **SSTR-PET/CT or SSTR-PET/MRI[c,d] (NE-D)**
- **Chest CT ± contrast**
- **EUS + biopsy**
- **Consider genetic counseling and testing for inherited genetic syndromes (NE-G)**

→ **Locoregional disease[e]** → **PanNET-2**

→ **Metastatic disease** → **PanNET-12**

[a] Principles of Pathology for the Diagnosis of Neuroendocrine Neoplasms (NE-A).
[b] Multiphasic imaging studies are performed with IV contrast in arterial and portal venous phases.
[c] SSTR-PET/CT or SSTR-PET/MRI of skull vertex to mid-thigh with multiphase IV contrast when possible. Data are limited on the optimal timing of scans following administration of SSAs.
[d] SSTR-PET tracers (eg, 68Ga-DOTATATE, 64Cu-DOTATATE, and 68Ga-DOTATOC).
[e] Observation can be considered for small (≤2 cm), low-grade, incidentally discovered, non-functional tumors. Decision based on estimated surgical risk, site of tumor, and patient comorbidities (Sadot E, et al. Ann Surg Oncol 2016;23:1361-1370; Partelli S, et al. Br J Surg 2022;109:1186-1190; Heidsma CM, et al. Br J Surg 2021;108:888-891). Follow surveillance recommendations on PanNET-11.

Note: All recommendations are category 2A unless otherwise indicated.

Version 3.2025, 10/01/2025 © 2025 National Comprehensive Cancer Network® (NCCN®), All rights reserved. NCCN Guidelines® and this illustration may not be reproduced in any form without the express written permission of NCCN.

PLEASE NOTE that use of this NCCN Content is governed by the End-User License Agreement, and you MAY NOT distribute this Content or use it with any artificial intelligence model or tool.
Printed by Galia Rasgoniokar on 10/29/2025 15:52 EDT. Copyright © 2025 National Comprehensive Cancer Network, Inc. All Rights Reserved.

MANAGEMENT OF PRIMARY NON-METASTATIC DISEASE

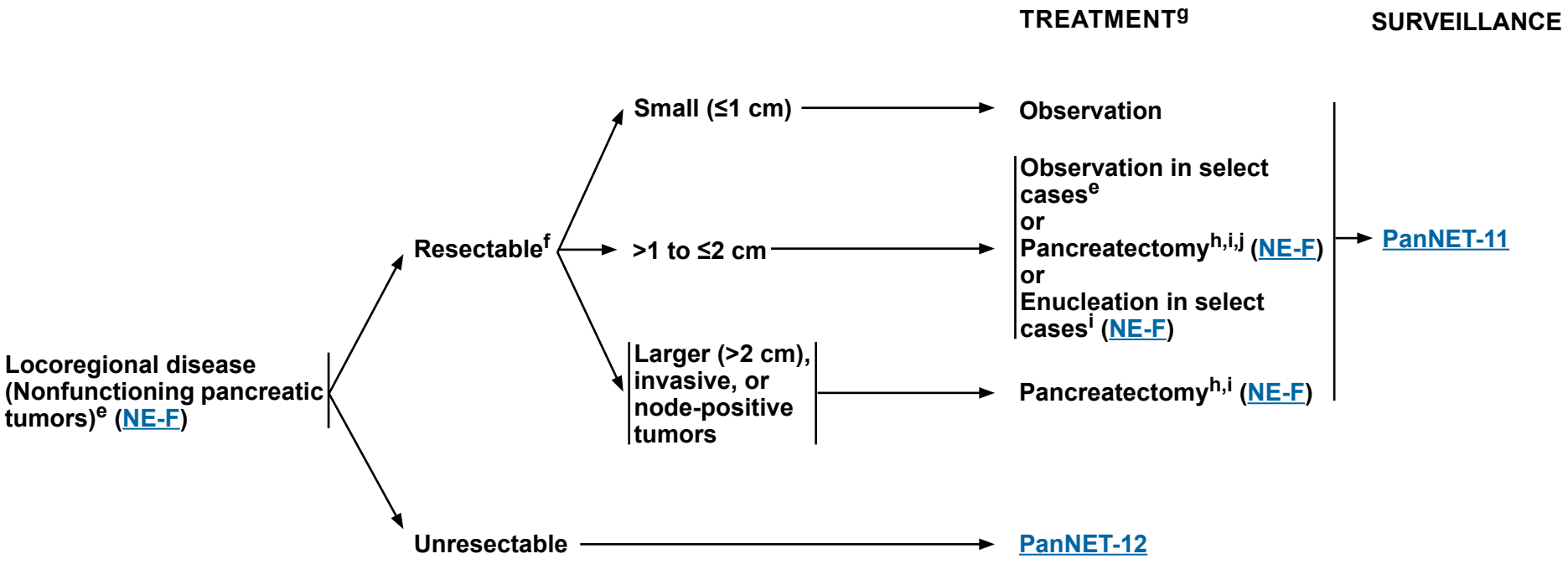

[e] Observation can be considered for small (≤2 cm), low-grade, incidentally discovered, non-functional tumors. Decision based on estimated surgical risk, site of tumor, and patient comorbidities (Sadot E, et al. Ann Surg Oncol 2016;23:1361-1370; Partelli S, et al. Br J Surg 2022;109:1186-1190; Heidsma CM, et al. Br J Surg 2021;108:888-891). Follow surveillance recommendations on PanNET-11.

[f] Patients with germline mutations are treated based on any tumors of a concerning size.

[g] Consider belzutifan for resectable tumors in the setting of germline *VHL* alteration.The decision to use belzutifan in small resectable tumors needs to be individualized. Data for the use of belzutifan for larger tumors, locally advanced unresectable tumors, and distant disease are extremely limited. Clinical trials are ongoing.

[h] Preoperative vaccination against encapsulated bacterium (ie, pneumococcus, haemophilus influenzae b, meningococcal group C), if considering surgery with possible splenectomy. See Principles of Surgical Management of Neuroendocrine Tumors (NE-F 2 of 3).

[i] As appropriate, central pancreatectomy or spleen-preserving surgery should be considered.

[j] PanNETs that are 1–2 cm have a small, but real risk of lymph node metastases. Therefore, lymph node resection should be considered.

Note: All recommendations are category 2A unless otherwise indicated.

Version 3.2025, 10/01/2025 © 2025 National Comprehensive Cancer Network® (NCCN®), All rights reserved. NCCN Guidelines® and this illustration may not be reproduced in any form without the express written permission of NCCN.

PLEASE NOTE that use of this NCCN Content is governed by the End-User License Agreement, and you MAY NOT distribute this Content or use it with any artificial intelligence model or tool.
Printed by Galia Basgoudian on 10/29/2025 15:52:57. Copyright © 2025 National Comprehensive Cancer Network, Inc. All Rights Reserved.

CLINICAL LOCATION | **EVALUATION[a]**

Gastrinoma (usually duodenum or head of pancreas) →

Recommended:
- **Serum gastrin level[k] (NE-E)**
- **Multiphasic[b] abdomen ± pelvis CT or MRI (NE-D)**
- **Genetic counseling and testing for inherited genetic syndromes (NE-G)**

As appropriate:
- **SSTR-PET/CT or SSTR-PET/MRI[c,d] (NE-D)**
- **Chest CT ± contrast**
- **EUS ± biopsy[l]**
- **Other biochemical evaluation as clinically indicated (NE-E)**

→ **Locoregional disease (NE-L)** → **PanNET-4**

→ **Metastatic disease** → **PanNET-12**

[a] Principles of Pathology for the Diagnosis of Neuroendocrine Neoplasms (NE-A).
[b] Multiphasic imaging studies are performed with IV contrast in arterial and portal venous phases.
[c] SSTR-PET/CT or SSTR-PET/MRI of skull vertex to mid-thigh with multiphase IV contrast when possible. Data are limited on the optimal timing of scans following administration of SSAs.
[d] SSTR-PET tracers (eg, 68Ga-DOTATATE, 64Cu-DOTATATE, and 68Ga-DOTATOC).
[k] Serum gastrin can be falsely elevated with PPI use. To confirm diagnosis, it should ideally be checked when fasting and off PPI for >1 week. However, PPI or H2 blocker should be continued in patients with overt clinical symptoms of gastrinoma and/or risks of complications.
[l] Multidisciplinary discussion prior to biopsy.

Note: All recommendations are category 2A unless otherwise indicated.

Version 3.2025, 10/01/2025 © 2025 National Comprehensive Cancer Network® (NCCN®), All rights reserved. NCCN Guidelines® and this illustration may not be reproduced in any form without the express written permission of NCCN.

PLEASE NOTE that use of this NCCN Content is governed by the End-User License Agreement, and you MAY NOT distribute this Content or use it with any artificial intelligence model or tool.
Printed by Galia Basovich-Gendler on 10/29/2025 15:52 EDT. Copyright © 2025 National Comprehensive Cancer Network, Inc. All Rights Reserved.

MANAGEMENT OF PRIMARY NON-METASTATIC DISEASE

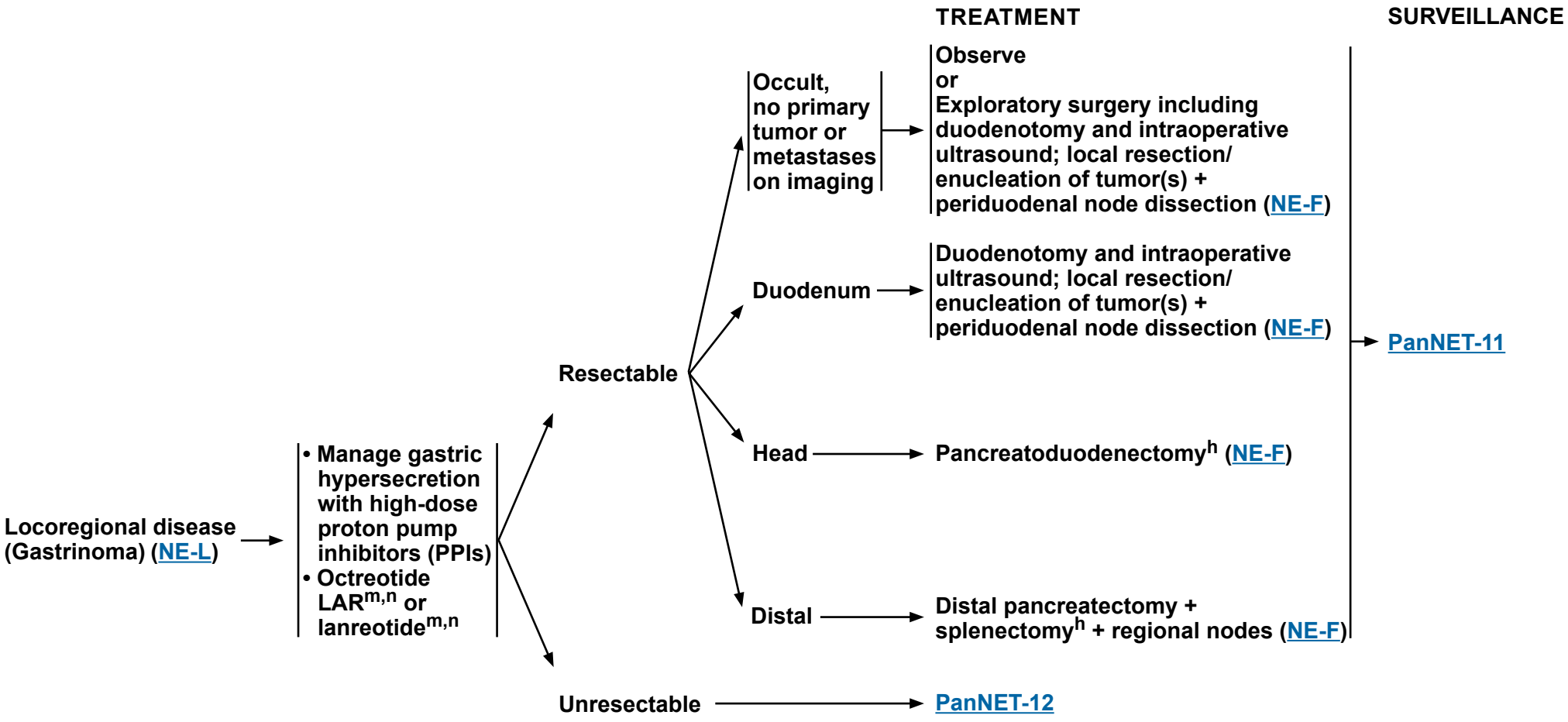

[h] Preoperative vaccination against encapsulated bacterium (ie, pneumococcus, haemophilus influenzae b, meningococcal group C), if considering surgery with possible splenectomy. See Principles of Surgical Management of Neuroendocrine Tumors (NE-F 2 of 3).

[m] For symptom and/or tumor control, octreotide LAR 20–30 mg IM or lanreotide 120 mg SC every 4 weeks. Higher doses have been shown to be safe. For breakthrough symptoms, octreotide 100–250 mcg SC TID can be considered.

[n] If injection site-related complications occur, consider switching to another SSA.

Note: All recommendations are category 2A unless otherwise indicated.

Version 3.2025, 10/01/2025 © 2025 National Comprehensive Cancer Network® (NCCN®), All rights reserved. NCCN Guidelines® and this illustration may not be reproduced in any form without the express written permission of NCCN.

PLEASE NOTE that use of this NCCN Content is governed by the End-User License Agreement, and you MAY NOT distribute this Content or use it with any artificial intelligence model or tool.
Printed by Galia Basgoudian on 10/7/2025 11:55:52 PM. Copyright © 2025 National Comprehensive Cancer Network, Inc. All Rights Reserved.

CLINICAL LOCATION	EVALUATION[a]		
Insulinoma →	**Recommended:** • Serum insulin, pro-insulin, and c-peptide levels during concurrent hypoglycemia (NE-E) • Fasting blood glucose • Multiphasic[b] abdomen ± pelvis CT or MRI (NE-D) **As appropriate:** • EUS • Other biochemical evaluation as clinically indicated (NE-E) • SSTR-PET/CT or SSTR-PET/MRI[c,d,o] (NE-D) • Chest CT ± contrast • Selective arterial calcium stimulation test for localization of insulinoma • Consider genetic counseling and testing for inherited genetic syndromes (NE-G)	Locoregional disease (NE-L) →	PanNET-6
		Metastatic disease →	PanNET-12

[a] Principles of Pathology for the Diagnosis of Neuroendocrine Neoplasms (NE-A).
[b] Multiphasic imaging studies are performed with IV contrast in arterial and portal venous phases.
[c] SSTR-PET/CT or SSTR-PET/MRI of skull vertex to mid-thigh with multiphase IV contrast when possible. Data are limited on the optimal timing of scans following administration of SSAs.
[d] SSTR-PET tracers (eg, 68Ga-DOTATATE, 64Cu-DOTATATE, and 68Ga-DOTATOC).
[o] Two-thirds of insulinomas are SSTR-PET negative and therefore may impact subsequent therapy and surveillance recommendations.

Note: All recommendations are category 2A unless otherwise indicated.

Version 3.2025, 10/01/2025 © 2025 National Comprehensive Cancer Network® (NCCN®), All rights reserved. NCCN Guidelines® and this illustration may not be reproduced in any form without the express written permission of NCCN.

PLEASE NOTE that use of this NCCN Content is governed by the End-User License Agreement, and you MAY NOT distribute this Content or use it with any artificial intelligence model or tool.
Printed by Galina Bagrodia-Bagrodia on 10/29/2025 15:52 EDT. Copyright © 2025 National Comprehensive Cancer Network, Inc. All Rights Reserved.

MANAGEMENT OF PRIMARY NON-METASTATIC DISEASE

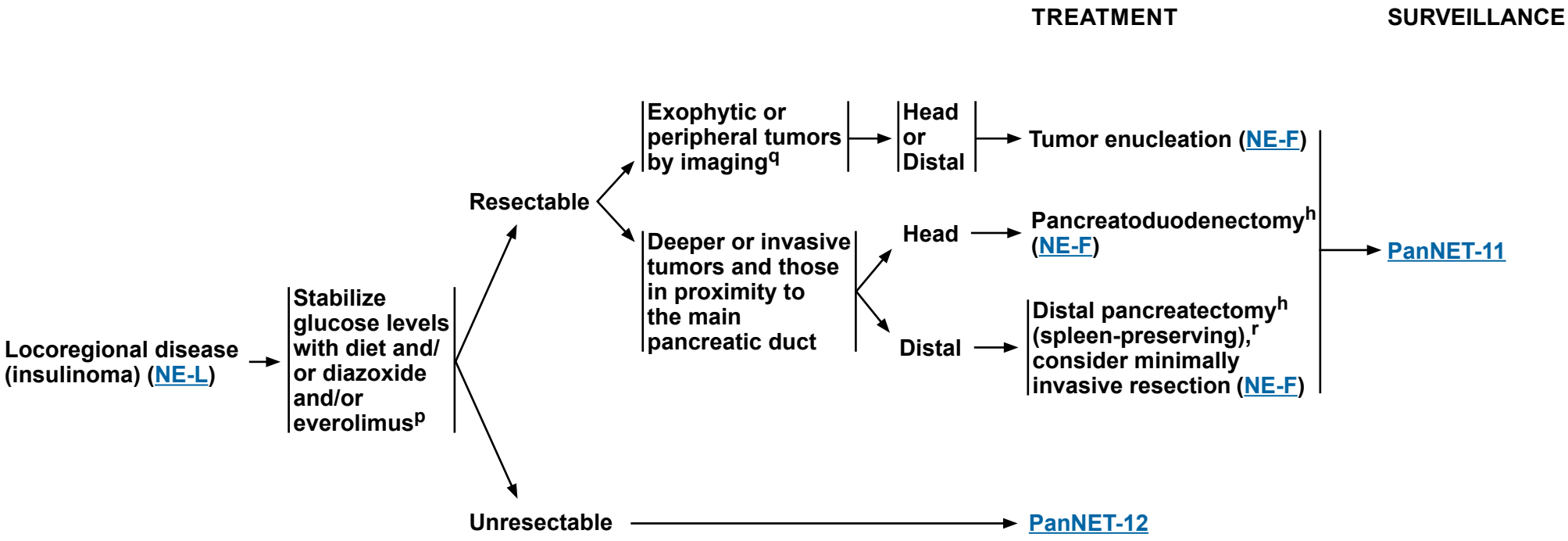

[h] Preoperative vaccination against encapsulated bacterium (ie, pneumococcus, haemophilus influenzae b, meningococcal group C), if considering surgery with possible splenectomy. See Principles of Surgical Management of Neuroendocrine Tumors (NE-F 2 of 3).

[p] Octreotide LAR or lanreotide can be considered but only if tumor expresses SSTRs. In the absence of SSTRs, octreotide LAR or lanreotide can profoundly worsen hypoglycemia. See Discussion for details.

[q] Not adjacent to the main pancreatic duct.

[r] Splenectomy should be performed for larger tumors involving splenic vessels.

Note: All recommendations are category 2A unless otherwise indicated.

Version 3.2025, 10/01/2025 © 2025 National Comprehensive Cancer Network® (NCCN®), All rights reserved. NCCN Guidelines® and this illustration may not be reproduced in any form without the express written permission of NCCN.

PLEASE NOTE that use of this NCCN Content is governed by the End-User License Agreement, and you MAY NOT distribute this Content or use it with any artificial intelligence model or tool.
Printed by Galia Basso Moreno on 10/29/2025 15:52 EDT. Copyright © 2025 National Comprehensive Cancer Network, Inc. All Rights Reserved.

CLINICAL LOCATION | **EVALUATION[a]**

Glucagonoma (usually tail) →

Recommended:
- **Glucagon and blood glucose**
- **Multiphasic[b] abdomen ± pelvis CT or MRI (NE-D)**

As appropriate:
- **SSTR-PET/CT or SSTR-PET/MRI[c,d] (NE-D)**
- **Chest CT ± contrast**
- **EUS**
- **Biochemical evaluation as clinically indicated (NE-E)**
- **Consider genetic counseling and testing for inherited genetic syndromes (NE-G)**

→ **Locoregional disease (NE-L)** → **PanNET-8**

→ **Metastatic disease** → **PanNET-12**

[a] Principles of Pathology for the Diagnosis of Neuroendocrine Neoplasms (NE-A).
[b] Multiphasic imaging studies are performed with IV contrast in arterial and portal venous phases.
[c] SSTR-PET/CT or SSTR-PET/MRI of skull vertex to mid-thigh with multiphase IV contrast when possible. Data are limited on the optimal timing of scans following administration of SSAs.
[d] SSTR-PET tracers (eg, 68Ga-DOTATATE, 64Cu-DOTATATE, and 68Ga-DOTATOC).

Note: All recommendations are category 2A unless otherwise indicated.

Version 3.2025, 10/01/2025 © 2025 National Comprehensive Cancer Network® (NCCN®), All rights reserved. NCCN Guidelines® and this illustration may not be reproduced in any form without the express written permission of NCCN.

PLEASE NOTE that use of this NCCN Content is governed by the End-User License Agreement, and you MAY NOT distribute this Content or use it with any artificial intelligence model or tool.
Printed by Galina Bagrodia on 10/7/2025 10:55:52 PM. Copyright © 2025 National Comprehensive Cancer Network, Inc. All Rights Reserved.

MANAGEMENT OF PRIMARY NON-METASTATIC DISEASE

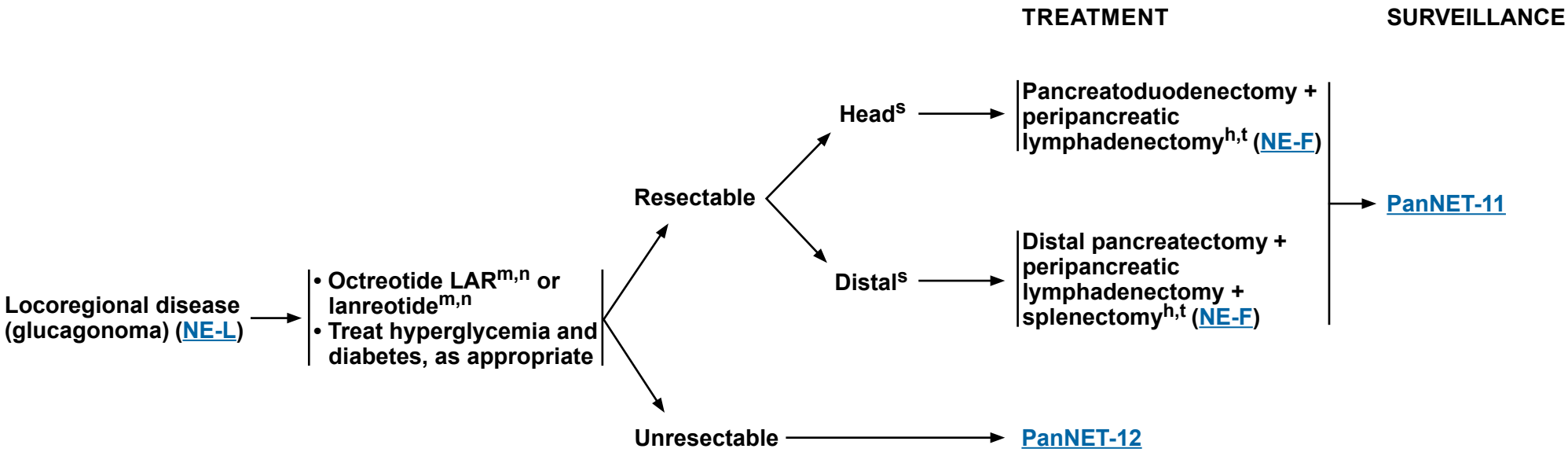

[h] Preoperative vaccination against encapsulated bacterium (ie, pneumococcus, haemophilus influenzae b, meningococcal group C), if considering surgery with possible splenectomy. See Principles of Surgical Management of Neuroendocrine Tumors (NE-F 2 of 3).

[m] For symptom and/or tumor control, octreotide LAR 20–30 mg IM or lanreotide 120 mg SC every 4 weeks. Higher doses have been shown to be safe. For breakthrough symptoms, octreotide 100–250 mcg SC TID can be considered.

[n] If injection site-related complications occur, consider switching to another SSA.

[s] Small (<2 cm), peripheral glucagonomas are rare; enucleation/local excision + peripancreatic lymph dissection may be considered.

[t] Hypercoagulable state has been described. Perioperative anticoagulation can be considered.

Note: All recommendations are category 2A unless otherwise indicated.

Version 3.2025, 10/01/2025 © 2025 National Comprehensive Cancer Network® (NCCN®), All rights reserved. NCCN Guidelines® and this illustration may not be reproduced in any form without the express written permission of NCCN.

PLEASE NOTE that use of this NCCN Content is governed by the End-User License Agreement, and you MAY NOT distribute this Content or use it with any artificial intelligence model or tool.
Printed by Galina Bagnolini on 10/10/2025 15:52 EDT. Copyright © 2025 National Comprehensive Cancer Network, Inc. All Rights Reserved.

CLINICAL LOCATION | **EVALUATION[a]**

VIPoma →

Recommended:
- **Electrolytes**
- **VIP levels**
- **Multiphasic[b] abdomen ± pelvis CT or MRI (NE-D)**

As appropriate:
- **SSTR-PET/CT or SSTR-PET/MRI[c,d] (NE-D)**
- **Chest CT ± contrast**
- **EUS**
- **Biochemical evaluation as clinically indicated (NE-E)**
- **Consider genetic counseling and testing for inherited genetic syndromes (NE-G)**

→ **Locoregional disease (NE-L)** → **PanNET-10**

→ **Metastatic disease** → **PanNET-12**

[a] Principles of Pathology for the Diagnosis of Neuroendocrine Neoplasms (NE-A).
[b] Multiphasic imaging studies are performed with IV contrast in arterial and portal venous phases.
[c] SSTR-PET/CT or SSTR-PET/MRI of skull vertex to mid-thigh with multiphase IV contrast when possible. Data are limited on the optimal timing of scans following administration of SSAs.
[d] SSTR-PET tracers (eg, 68Ga-DOTATATE, 64Cu-DOTATATE, and 68Ga-DOTATOC).

Note: All recommendations are category 2A unless otherwise indicated.

Version 3.2025, 10/01/2025 © 2025 National Comprehensive Cancer Network® (NCCN®), All rights reserved. NCCN Guidelines® and this illustration may not be reproduced in any form without the express written permission of NCCN.

PLEASE NOTE that use of this NCCN Content is governed by the End-User License Agreement, and you MAY NOT distribute this Content or use it with any artificial intelligence model or tool.
Printed by Galia Basovich-Gendler on 10/28/2025 15:52 EDT. Copyright © 2025 National Comprehensive Cancer Network, Inc. All Rights Reserved.

MANAGEMENT OF PRIMARY NON-METASTATIC DISEASE

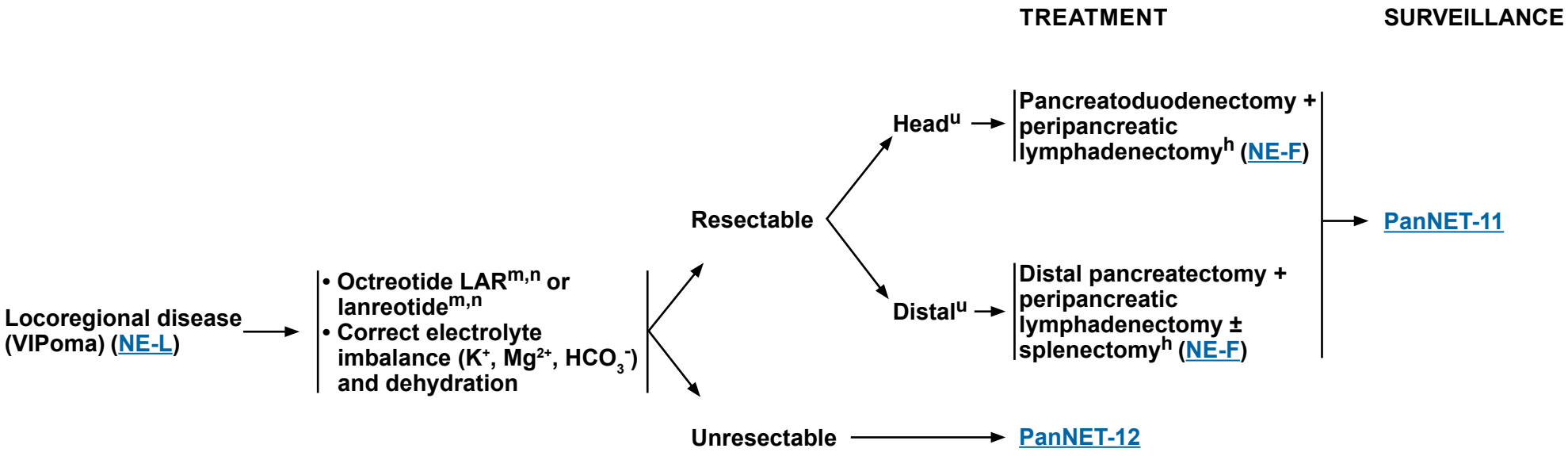

[h] Preoperative vaccination against encapsulated bacterium (ie, pneumococcus, haemophilus influenzae b, meningococcal group C), if considering surgery with possible splenectomy. See Principles of Surgical Management of Neuroendocrine Tumors (NE-F 2 of 3).
[m] For symptom and/or tumor control, octreotide LAR 20–30 mg IM or lanreotide 120 mg SC every 4 weeks. Higher doses have been shown to be safe. For breakthrough symptoms, octreotide 100–250 mcg SC TID can be considered.
[n] If injection site-related complications occur, consider switching to another SSA.
[u] Small (<2 cm), peripheral VIPomas are rare; enucleation/local excision + peripancreatic lymph dissection may be considered.

Note: All recommendations are category 2A unless otherwise indicated.

Version 3.2025, 10/01/2025 © 2025 National Comprehensive Cancer Network® (NCCN®), All rights reserved. NCCN Guidelines® and this illustration may not be reproduced in any form without the express written permission of NCCN.

PLEASE NOTE that use of this NCCN Content is governed by the End-User License Agreement, and you MAY NOT distribute this Content or use it with any artificial intelligence model or tool.
Printed by Galia Basovich-Gendler on 10/10/2025 15:52 EDT. Copyright © 2025 National Comprehensive Cancer Network, Inc. All Rights Reserved.

SURVEILLANCE[v-y]

12 wk–12 mo post-resection:
- **H&P**
- **For functional tumors, follow-up with biochemical markers as clinically indicated (NE-E)**
- **Multiphasic[b] abdomen ± pelvis CT or MRI (NE-D)**
- **Chest CT (± contrast) as clinically indicated**

>1 y post-resection to a maximum of 10 y:
- **Every 6–12 mo**
  - **H&P**
  - **For functional tumors, follow-up with biochemical markers as clinically indicated (NE-E)**
  - **Multiphasic[b] abdomen ± pelvis CT or MRI (NE-D)**
  - **Chest CT (± contrast) as clinically indicated**

>10 y:
- **Consider surveillance as clinically indicated[z]**

→ **Disease recurrence[aa]** → **PanNET-12**

RECURRENT DISEASE

MANAGEMENT OF RECURRENT DISEASE[bb]

[b] Multiphasic imaging studies are performed with IV contrast in arterial and portal venous phases.
[v] Earlier, if symptoms.
[w] SSTR-based imaging and FDG-PET/CT scan are not recommended for routine surveillance.
[x] Surveillance recommendations also apply to cases where observation has been chosen.
[y] NCCN Guidelines for Survivorship.
[z] Singh S, et al. JAMA Oncol 2018;4:1597-1604.
[aa] In select cases, resection may be considered.
[bb] Principles of Surgical Management of Neuroendocrine Tumors (NE-F).

Note: All recommendations are category 2A unless otherwise indicated.

Version 3.2025, 10/01/2025 © 2025 National Comprehensive Cancer Network® (NCCN®), All rights reserved. NCCN Guidelines® and this illustration may not be reproduced in any form without the express written permission of NCCN.

PLEASE NOTE that use of this NCCN Content is governed by the End-User License Agreement, and you MAY NOT distribute this Content or use it with any artificial intelligence model or tool.
Printed by Galia Basa-Hooker on 10/09/2025 15:52 EDT. Copyright © 2025 National Comprehensive Cancer Network, Inc. All Rights Reserved.

MANAGEMENT OF LOCOREGIONAL ADVANCED DISEASE AND/OR DISTANT METASTASES

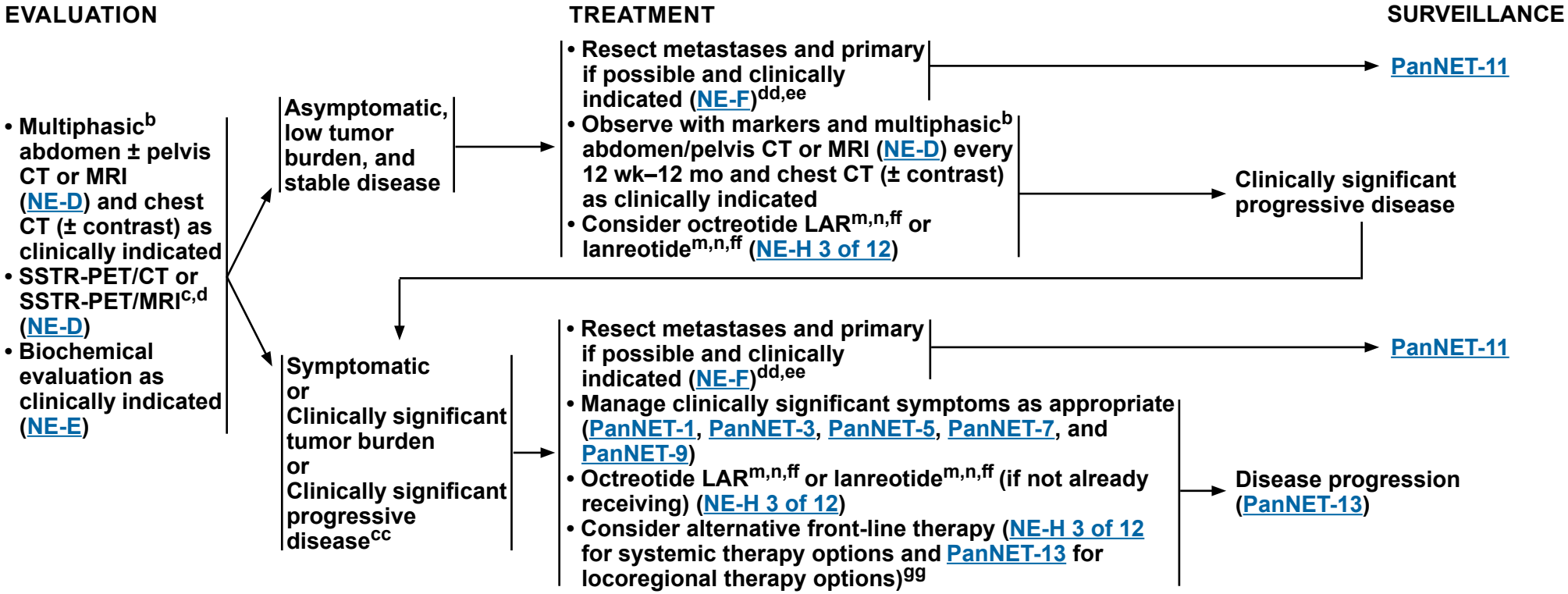

[b] Multiphasic imaging studies are performed with IV contrast in arterial and portal venous phases.
[c] SSTR-PET/CT or SSTR-PET/MRI of skull vertex to mid-thigh with multiphase IV contrast when possible. Data are limited on the optimal timing of scans following administration of SSAs.
[d] SSTR-PET tracers (eg, 68Ga-DOTATATE, 64Cu-DOTATATE, and 68Ga-DOTATOC).
[m] For symptom and/or tumor control, octreotide LAR 20–30 mg IM or lanreotide 120 mg SC every 4 weeks. Higher doses have been shown to be safe. For breakthrough symptoms, octreotide 100–250 mcg SC TID can be considered.
[n] If injection site-related complications occur, consider switching to another SSA.
[cc] If clinically significant disease progression, treatment with octreotide LAR or lanreotide should be discontinued for non-functional tumors and continued in patients with functional tumors; these regimens may be used in combination with any of the subsequent options.
[dd] Staged or synchronous resection when possible. When performing staged pancreatoduodenectomy and liver resection, consider hepatectomy prior to pancreatic resection in order to reduce risk of perihepatic sepsis. De Jong MC, et al. Ann Surg 2010;252:142-148.
[ee] Use of belzutifan in the setting of germline *VHL* alteration needs to be individualized (category 2B). Data for the use of belzutifan for larger tumors, locally advanced unresectable tumors, and distant disease are extremely limited. Clinical trials are ongoing.
[ff] For patients with insulinoma, octreotide LAR or lanreotide should be used only if SSTR-based imaging is positive. If used, they should be used with caution in patients with insulinoma as they may transiently worsen hypoglycemia (see Discussion for details).
[gg] In select cases, it may be appropriate to proceed to front-line systemic therapy or locoregional therapy prior to or concurrently with octreotide LAR or lanreotide.

Note: All recommendations are category 2A unless otherwise indicated.

Version 3.2025, 10/01/2025 © 2025 National Comprehensive Cancer Network® (NCCN®), All rights reserved. NCCN Guidelines® and this illustration may not be reproduced in any form without the express written permission of NCCN.

PLEASE NOTE that use of this NCCN Content is governed by the End-User License Agreement, and you MAY NOT distribute this Content or use it with any artificial intelligence model or tool.
Printed by Galia Basco Moreno on 10/10/2025 15:52 EDT. Copyright © 2025 National Comprehensive Cancer Network, Inc. All Rights Reserved.

MANAGEMENT OF LOCOREGIONAL ADVANCED DISEASE AND/OR DISTANT METASTASES

SUBSEQUENT THERAPY

Disease progression[cc] →

Clinical trial
or
Systemic therapy (NE-H 3 of 12)
or
Locoregional therapy options
- **Consider liver-directed therapy for liver-predominant disease[hh] (NE-K)**
- **Consider RT (NE-I) ± concurrent fluoropyrimidine-based chemotherapy for locally advanced unresectable disease (excluding small bowel mesenteric)**
- **Palliative RT for oligometastatic disease and/or symptomatic metastases (excluding mesenteric masses) (NE-I)**

[cc] If clinically significant disease progression, treatment with octreotide LAR or lanreotide should be discontinued for non-functional tumors and continued in patients with functional tumors; these regimens may be used in combination with any of the subsequent options.
[hh] After any prior biliary instrumentation, there are increased risks of infectious complications associated with liver-directed therapies.

Note: All recommendations are category 2A unless otherwise indicated.

Version 3.2025, 10/01/2025 © 2025 National Comprehensive Cancer Network® (NCCN®), All rights reserved. NCCN Guidelines® and this illustration may not be reproduced in any form without the express written permission of NCCN.

PLEASE NOTE that use of this NCCN Content is governed by the End-User License Agreement, and you MAY NOT distribute this Content or use it with any artificial intelligence model or tool.
Printed by Galya Basol Kochav on 1/7/2026 1:55:52 PM. Copyright © 2026 National Comprehensive Cancer Network, Inc. All Rights Reserved.

INITIAL WORKUP[c]

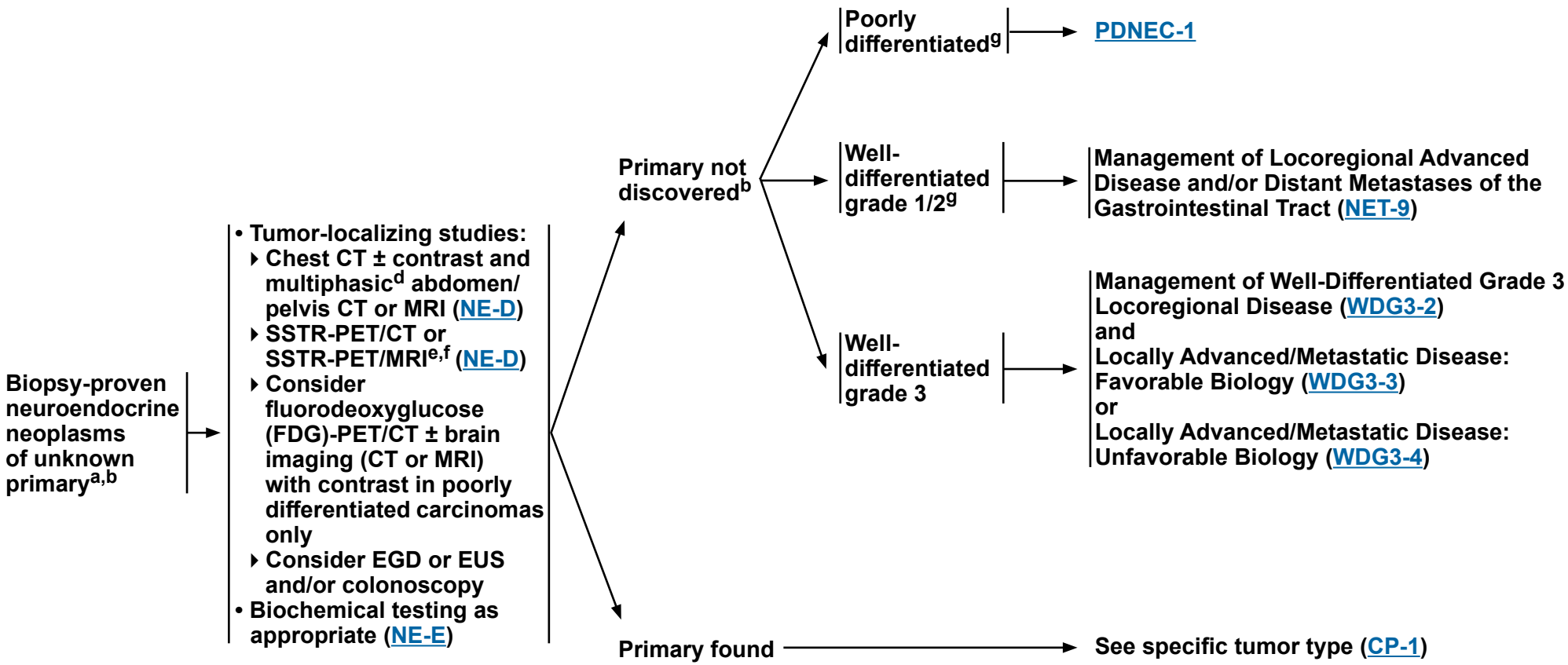

[a] Treat presumptively as gastroenteropancreatic (GEP) NETs if it is unknown primary.
[b] Consider small bowel primary tumor based on symptoms and associated radiologic findings.
[c] Principles of Pathology for the Diagnosis of Neuroendocrine Neoplasms (NE-A).
[d] Multiphasic imaging studies are performed with IV contrast in arterial and portal venous phases.
[e] SSTR-PET/CT or SSTR-PET/MRI of skull vertex to mid-thigh with multiphase IV contrast when possible. Data are limited on the optimal timing of scans following administration of SSAs.
[f] SSTR-PET tracers (eg, 68Ga-DOTATATE, 64Cu-DOTATATE, and 68Ga-DOTATOC).
[g] Indicate well- or poorly differentiated. Klimstra DS, et al. Pancreas 2010;39:707-712.

Note: All recommendations are category 2A unless otherwise indicated.

Version 3.2025, 10/01/2025 © 2025 National Comprehensive Cancer Network® (NCCN®), All rights reserved. NCCN Guidelines® and this illustration may not be reproduced in any form without the express written permission of NCCN.

PLEASE NOTE that use of this NCCN Content is governed by the End-User License Agreement, and you MAY NOT distribute this Content or use it with any artificial intelligence model or tool.
Printed by Galya Basol Kochav on 1/7/2026 1:55:52 PM. Copyright © 2026 National Comprehensive Cancer Network, Inc. All Rights Reserved.

TUMOR TYPE | **EVALUATION[a]**

Well-differentiated Grade 3 NETs

Recommended:
- **Multiphasic[b] abdomen/pelvis CT or MRI with contrast (NE-D)**
- **Chest CT as clinically indicated**
- **Pathology review**
- **SSTR-PET/CT or SSTR-PET/MRI[c,d] (NE-D)**

As appropriate
- **FDG-PET/CT[e]**
- **Biochemical evaluation as clinically indicated (NE-E)**
- **Consider molecular profiling of tumor tissue[f]**
- **Consider assessment of p53, Rb, p16 by histopathologic analysis or molecular profiling if uncertain about differentiation**
- **Genetic counseling and testing for inherited genetic syndromes (only for duodenal NET or PanNET) (NE-G)**

→ **Locoregional (Resectable)** → **WDG3-2**

→ **Locally advanced/ Metastatic**
- → **Favorable biology (eg, relatively low Ki-67[g] [<55%], slow growing, positive SSTR-based PET imaging)** → **WDG3-3**
- → **Unfavorable biology (eg, relatively high Ki-67[g] [≥55%], faster growing, negative SSTR-based PET imaging)** → **WDG3-4**

[a] Principles of Pathology for the Diagnosis of Neuroendocrine Neoplasms (NE-A).
[b] Multiphasic imaging studies are performed with IV contrast in arterial and portal venous phases.
[c] SSTR-PET/CT or SSTR-PET/MRI of skull vertex to mid-thigh with multiphase IV contrast when possible. Data are limited on the optimal timing of scans following administration of SSAs.
[d] SSTR-PET tracers (eg, 68Ga-DOTATATE, 64Cu-DOTATATE, and 68Ga-DOTATOC).
[e] Consider both FDG-PET and DOTATATE-PET if considering PRRT.
[f] Tumor/somatic molecular profiling should be considered for patients with locoregional unresectable/metastatic disease who are candidates for anticancer therapy to identify actionable alterations. Testing on tumor tissue is preferred; however, liquid biopsy can be considered if tumor tissue testing is not feasible.
[g] There are limitations in terms of the data for what the appropriate cutoff should be, as well as variability/heterogeneity of Ki-67 in a given tumor and over time in serial biopsies. The clinical course can be heterogeneous and treatment considerations need to account for both pathologic and clinical features.

Note: All recommendations are category 2A unless otherwise indicated.

Version 3.2025, 10/01/2025 © 2025 National Comprehensive Cancer Network® (NCCN®), All rights reserved. NCCN Guidelines® and this illustration may not be reproduced in any form without the express written permission of NCCN.

PLEASE NOTE that use of this NCCN Content is governed by the End-User License Agreement, and you MAY NOT distribute this Content or use it with any artificial intelligence model or tool.
Printed by Galya Basol Kochav on 1/7/2026 1:55:52 PM. Copyright © 2026 National Comprehensive Cancer Network, Inc. All Rights Reserved.

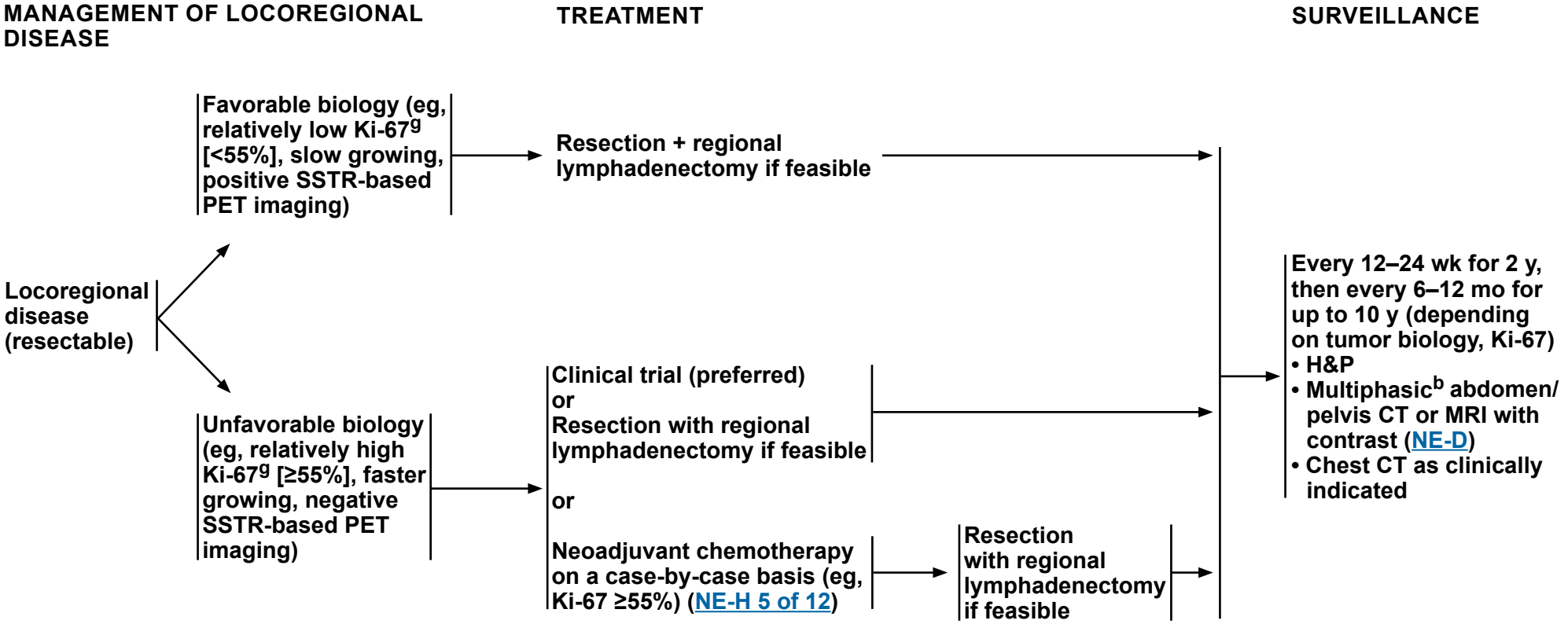

[b] Multiphasic imaging studies are performed with IV contrast in arterial and portal venous phases.
[g] There are limitations in terms of the data for what the appropriate cutoff should be, as well as variability/heterogeneity of Ki-67 in a given tumor and over time in serial biopsies. The clinical course can be heterogeneous and treatment considerations need to account for both pathologic and clinical features.

Note: All recommendations are category 2A unless otherwise indicated.

Version 3.2025, 10/01/2025 © 2025 National Comprehensive Cancer Network® (NCCN®), All rights reserved. NCCN Guidelines® and this illustration may not be reproduced in any form without the express written permission of NCCN.

PLEASE NOTE that use of this NCCN Content is governed by the End-User License Agreement, and you MAY NOT distribute this Content or use it with any artificial intelligence model or tool.
Printed by Galya Basol Kochav on 1/7/2026 1:55:52 PM. Copyright © 2026 National Comprehensive Cancer Network, Inc. All Rights Reserved.

MANAGEMENT OF LOCALLY ADVANCED/METASTATIC DISEASE: FAVORABLE BIOLOGY

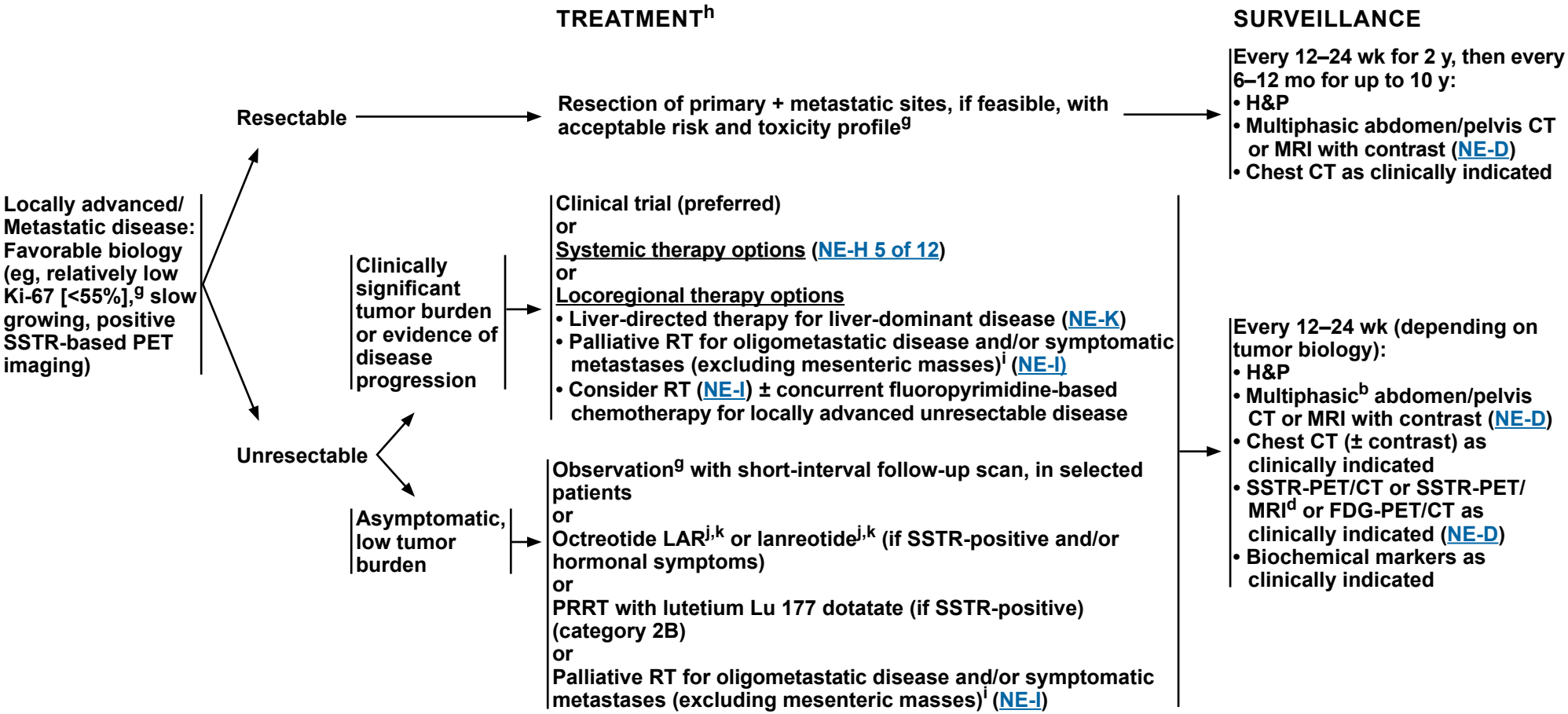

[b] Multiphasic imaging studies are performed with IV contrast in arterial and portal venous phases.
[d] SSTR-PET tracers (eg, 68Ga-DOTATATE, 64Cu-DOTATATE, and 68Ga-DOTATOC).
[g] There are limitations in terms of the data for what the appropriate cutoff should be, as well as variability/heterogeneity of Ki-67 in a given tumor and over time in serial biopsies. The clinical course can be heterogeneous and treatment considerations need to account for both pathologic and clinical features.
[h] Clinical trials are preferred due to a lack of data from prospective clinical trials to guide therapy.
[i] Krug S, et al. BMC 2019;19:362.
[j] For symptom and/or tumor control, octreotide LAR 20–30 mg IM or lanreotide 120 mg SC every 4 weeks. Higher doses have been shown to be safe. For breakthrough symptoms, octreotide 100–250 mcg SC TID can be considered.
[k] If injection site-related complications occur, consider switching to another SSA.

Note: All recommendations are category 2A unless otherwise indicated.

Version 3.2025, 10/01/2025 © 2025 National Comprehensive Cancer Network® (NCCN®), All rights reserved. NCCN Guidelines® and this illustration may not be reproduced in any form without the express written permission of NCCN.

PLEASE NOTE that use of this NCCN Content is governed by the End-User License Agreement, and you MAY NOT distribute this Content or use it with any artificial intelligence model or tool.
Printed by Galya Basol Kochav on 1/7/2026 1:55:52 PM. Copyright © 2026 National Comprehensive Cancer Network, Inc. All Rights Reserved.

MANAGEMENT OF LOCALLY ADVANCED/METASTATIC DISEASE: UNFAVORABLE BIOLOGY

	TREATMENT	SURVEILLANCE
Locally advanced/Metastatic disease: Unfavorable biology (relatively high Ki-67 [≥55%],[g] rapid growth rate, FDG-avid tumors, negative SSTR-based PET imaging) →	**Clinical trial (preferred)** **or** **Systemic therapy options (NE-H 5 of 12)** **or** **Locoregional therapy options** • **Consider RT (NE-I) ± concurrent fluoropyrimidine-based chemotherapy for locally advanced unresectable disease** • **Consider addition of liver-directed therapy[l] (NE-K)** • **Palliative RT for oligometastatic disease and/or symptomatic metastases (excluding mesenteric masses)[i] (NE-I)** →	**Every 8–12 wk (depending on tumor biology)** • **H&P** • **Multiphasic[b] abdomen/pelvis CT or MRI with contrast (NE-D)** • **Chest CT (± contrast) as clinically indicated** • **FDG-PET/CT as clinically indicated (NE-D)** • **Biochemical markers as clinically indicated (NE-E)**

[b] Multiphasic imaging studies are performed with IV contrast in arterial and portal venous phases.
[g] There are limitations in terms of the data for what the appropriate cutoff should be, as well as variability/heterogeneity of Ki-67 in a given tumor and over time in serial biopsies. The clinical course can be heterogeneous and treatment considerations need to account for both pathologic and clinical features.
[i] Krug S, et al. BMC 2019;19:362.
[l] Consider liver-directed therapy in selected cases with residual liver-predominant disease after systemic therapy.

Note: All recommendations are category 2A unless otherwise indicated.

Version 3.2025, 10/01/2025 © 2025 National Comprehensive Cancer Network® (NCCN®), All rights reserved. NCCN Guidelines® and this illustration may not be reproduced in any form without the express written permission of NCCN.

PLEASE NOTE that use of the NCCN Content is governed by the End-User License Agreement, and you MAY NOT distribute this Content or use it with any artificial intelligence model or tool.
Printed by Galyna Segeda [redacted] on 11/12/2025 5:52 AM. Copyright © 2025 National Comprehensive Cancer Network, Inc. All Rights Reserved.

Extrapulmonary Poorly Differentiated: Neuroendocrine Carcinoma/ Large or Small Cell Carcinoma/Mixed Neuroendocrine-Non-Neuroendocrine Neoplasm

TUMOR TYPE

Extrapulmonary poorly differentiated:[a,b]
- Neuroendocrine carcinoma (NEC)[c,d] (NE-A)
- Large or small cell carcinoma
- Mixed neuroendocrine-non-neuroendocrine neoplasm (MiNEN)

EVALUATION[c,e]

Recommended:
- Multiphasic[f] chest/abdomen/pelvis CT (NE-D)

or
- Chest CT and abdomen/pelvis MRI[e] (NE-D)

As appropriate:
- Brain MRI or CT with contrast
- FDG-PET/CT (NE-D)
- Biochemical evaluation as clinically indicated (NE-E)
- Consider molecular profiling of tumor tissue[g]

TREATMENT[h]

Resectable

Therapy options depend on sites of disease. Options may include:
- Resection (NE-F) + adjuvant chemotherapy (NE-H 6 of 12) ± RT (NE-I)
- Neoadjuvant chemotherapy (NE-H 6 of 12) ± RT (NE-I) + resection (NE-F)
- Chemotherapy alone (NE-H 6 of 12)
- Definitive chemoradiation with cisplatin + etoposide or carboplatin + etoposide

Locoregional, unresectable

Concurrent or sequential RT (NE-I) + chemotherapy (NE-H 6 of 12)

or

Chemotherapy (NE-H 6 of 12)

Metastatic

Chemotherapy (NE-H 6 of 12)

If progression (NE-H 6 of 12):
- Chemotherapy
- Immunotherapy[i]
- Targeted therapy

SURVEILLANCE[j,k]

Every 12 wk for 1 y, then every 6 mo:
- H&P
- Appropriate imaging studies:
  - Chest CT ± contrast and abdomen/pelvis MRI with contrast

    or
  - Multiphasic[f] chest/abdomen/pelvis CT (NE-D)

Every 6–16 wk:
- H&P
- Appropriate imaging studies:
  - Chest CT ± contrast and abdomen/pelvis MRI with contrast

    or
  - Multiphasic[f] chest/abdomen/pelvis CT (NE-D)

Footnotes on PDNEC-1A

Note: All recommendations are category 2A unless otherwise indicated.

Version 3.2025, 10/01/2025 © 2025 National Comprehensive Cancer Network® (NCCN®), All rights reserved. NCCN Guidelines® and this illustration may not be reproduced in any form without the express written permission of NCCN.

PLEASE NOTE that use of the NCCN Content is governed by the End-User License Agreement, and you MAY NOT distribute this Content or use it with any artificial intelligence model or tool.
Printed by NGallagher@ncccn.org 11/7/2025 5:52 PM. Copyright © 2025 National Comprehensive Cancer Network, Inc. All Rights Reserved.

FOOTNOTES

[a] Eads JR, et al. Endocr Relat Cancer 2023;30:e220206.
[b] Sorbye H, et al. J Neuroendocrinol 2023;35:e13249.
[c] This page is for poorly differentiated neuroendocrine carcinoma (PDNEC) and not high-grade NET. Not all high-grade (Ki-67 >20%) neuroendocrine neoplasms are poorly differentiated. See WDG3-1.
[d] PDNECs are often associated with non-neuroendocrine components such as adeno or squamous cell carcinoma. Management of these tumors is controversial. Often, chemotherapy regimens for non-neuroendocrine components may be considered.
[e] SSTR-based imaging (SSTR-PET/CT or SSTR-PET/MRI) is not part of the routine evaluation of PDNECs.
[f] Multiphasic imaging studies are performed with IV contrast in arterial and portal venous phases.
[g] Tumor/somatic molecular profiling should be considered for patients with locoregional unresectable/metastatic disease who are candidates for anticancer therapy to identify actionable alterations. Consider specifically testing for potentially actionable somatic findings including, but not limited to: *NTRK* fusions, *RET* fusions, *BRAF* V600E mutations, microsatellite instability-high (MSI-H), mismatch repair deficiency (dMMR), and tumor mutational burden-high (TMB-H). Testing on tumor tissue is preferred; however, liquid biopsy can be considered if tumor tissue testing is not feasible.
[h] Combination of immune checkpoint inhibitors + chemotherapy is investigational for all patients with extrapulmonary PDNECs.
[i] Pembrolizumab can be considered for patients with MSI-H, dMMR, or advanced TMB-H (≥10 mut/Mb) tumors (as determined by an FDA-approved test) that have progressed following prior treatment and have no satisfactory alternative treatment options.
[j] Earlier, if symptoms.
[k] NCCN Guidelines for Survivorship.

Note: All recommendations are category 2A unless otherwise indicated.

Version 3.2025, 10/01/2025 © 2025 National Comprehensive Cancer Network® (NCCN®), All rights reserved. NCCN Guidelines® and this illustration may not be reproduced in any form without the express written permission of NCCN.

PLEASE NOTE that use of this NCCN Content is governed by the End-User License Agreement, and you MAY NOT distribute this Content or use it with any artificial intelligence model or tool.
Printed by Galya Basol Kochav on 1/7/2026 1:55:52 PM. Copyright © 2026 National Comprehensive Cancer Network, Inc. All Rights Reserved.

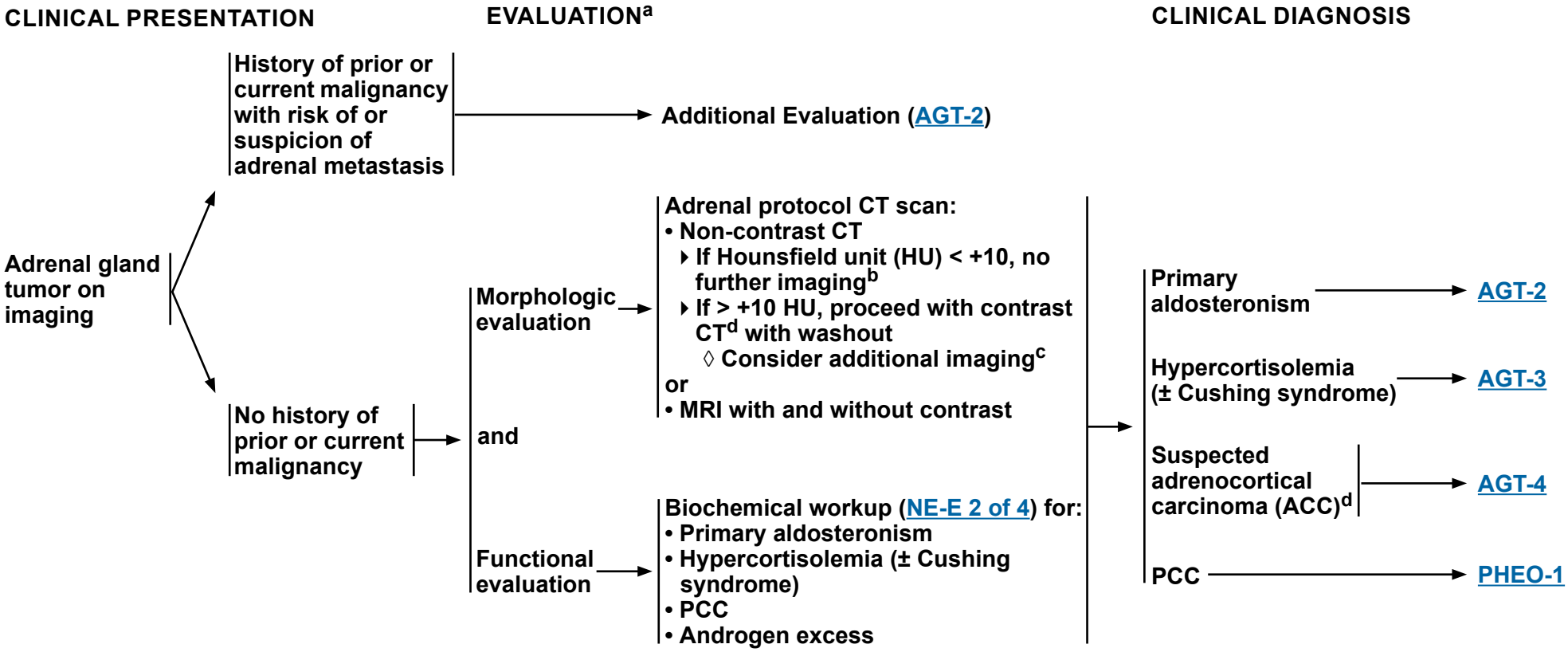

[a] Principles of Pathology for the Diagnosis of Adrenocortical Carcinoma (NE-B).
[b] If HU < +10, no PCC screening is needed.
[c] Depending on HU and imaging characteristics, additional imaging and workup may be indicated. Fassnacht M, et al. Eur J Endocrinol 2023;189:G1-G42.
[d] ACC can oftentimes secrete multiple hormones.

Note: All recommendations are category 2A unless otherwise indicated.

Version 3.2025, 10/01/2025 © 2025 National Comprehensive Cancer Network® (NCCN®), All rights reserved. NCCN Guidelines® and this illustration may not be reproduced in any form without the express written permission of NCCN.

PLEASE NOTE that use of this NCCN Content is governed by the End-User License Agreement, and you MAY NOT distribute this Content or use it with any artificial intelligence model or tool.
Printed by Galya Basol Kochav on 1/7/2026 1:55:52 PM. Copyright © 2026 National Comprehensive Cancer Network, Inc. All Rights Reserved.

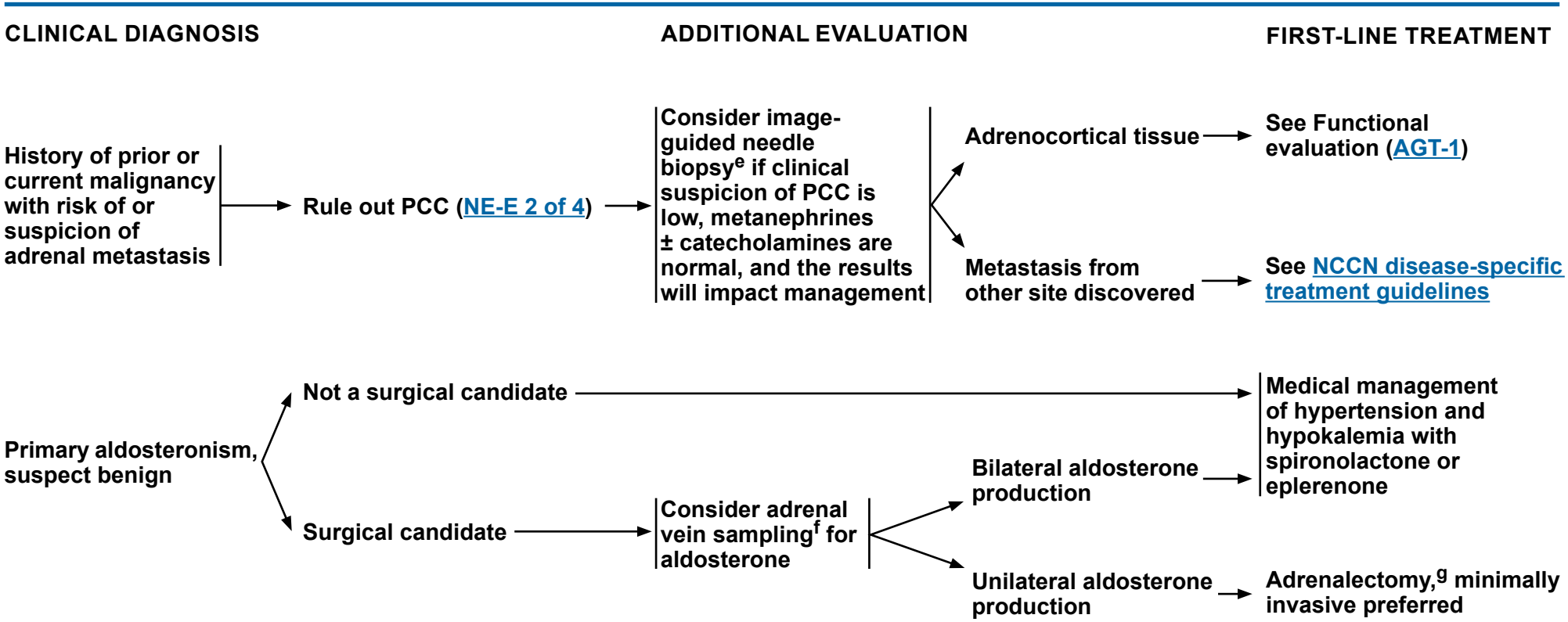

[e] False negatives are possible; may consider proceeding directly to surgery in selected cases.
[f] Adrenal vein sampling can be considered for distinguishing single unilateral adenomas from bilateral hyperplasia. CT imaging is not always reliable. Some NCCN Member Institutions recommend sampling in all cases of primary aldosteronism. However, it may be reasonable to exclude adrenal vein sampling in patients <40 years. Cortisol measurement in the catheterization samples is used to confirm proper catheter placement.
[g] Yip L, et al. JAMA Surg 2022;157:870-877.

Note: All recommendations are category 2A unless otherwise indicated.

Version 3.2025, 10/01/2025 © 2025 National Comprehensive Cancer Network® (NCCN®), All rights reserved. NCCN Guidelines® and this illustration may not be reproduced in any form without the express written permission of NCCN.

PLEASE NOTE that use of this NCCN Content is governed by the End-User License Agreement, and you MAY NOT distribute this Content or use it with any artificial intelligence model or tool.
Printed by Galya Basol Kochav on 1/7/2026 1:55:52 PM. Copyright © 2026 National Comprehensive Cancer Network, Inc. All Rights Reserved.

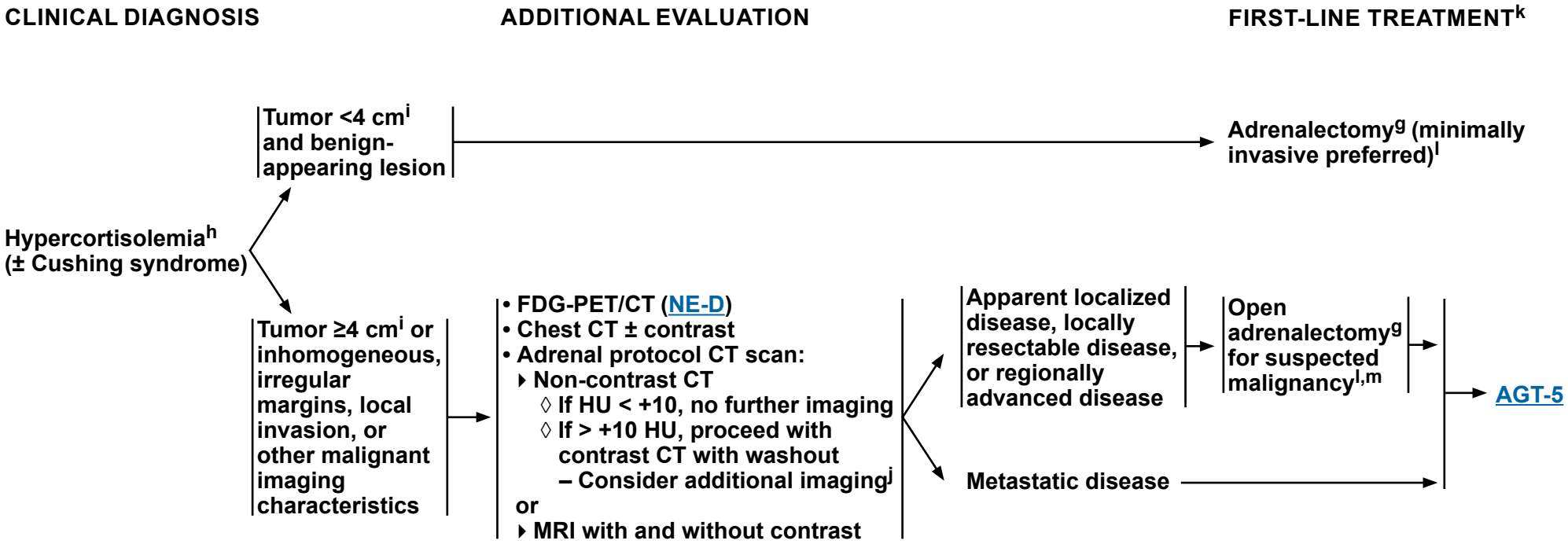

[g] Yip L, et al. JAMA Surg 2022;157:870-877.
[h] Endocrinology evaluation is recommended.
[i] Some centers may use 6 cm as cutoff.
[j] Depending on HU and imaging characteristics, additional imaging and workup may be indicated. Fassnacht M, et al. Eur J Endocrinol
[k] For benign-appearing lesions, refer to the Endocrine Society's Clinical Practice Guidelines for the Treatment of Cushing's Syndrome (Fleseriu M, et al. Lancet Diabetes Endocrinol 2021;9:847-875).2023;189:G1-G42.
[l] Perioperative management should include stress-dose steroids (eg, methylprednisolone or hydrocortisone).
[m] May require removal of adjacent structures (ie, liver, kidney, pancreas, spleen, diaphragm) for complete resection.

Note: All recommendations are category 2A unless otherwise indicated.

Version 3.2025, 10/01/2025 © 2025 National Comprehensive Cancer Network® (NCCN®), All rights reserved. NCCN Guidelines® and this illustration may not be reproduced in any form without the express written permission of NCCN.

PLEASE NOTE that use of this NCCN Content is governed by the End-User License Agreement, and you MAY NOT distribute this Content or use it with any artificial intelligence model or tool.
Printed by Galya Basol Kochav on 1/7/2026 1:55:52 PM. Copyright © 2026 National Comprehensive Cancer Network, Inc. All Rights Reserved.

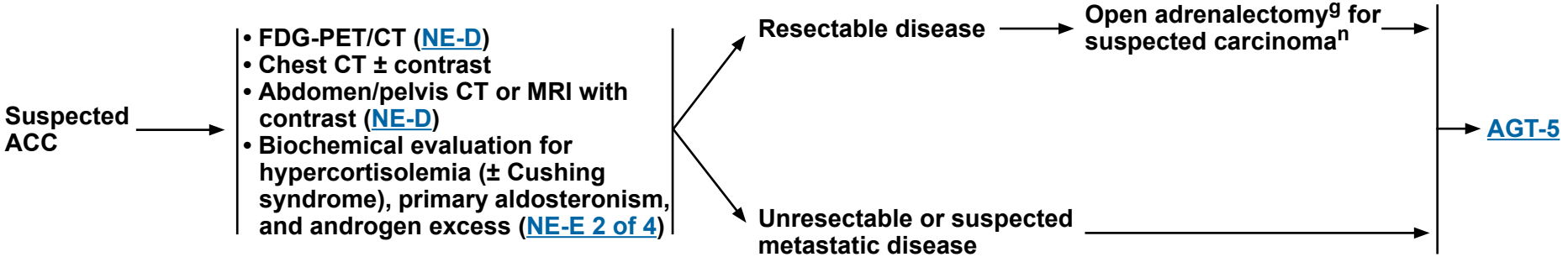

[g] Yip L, et al. JAMA Surg 2022;157:870-877.
[n] If size is resectable by laparoscopy, may explore with a minimally invasive approach with planned conversion for evidence of local invasion. The decision for open versus minimally invasive surgery is based on tumor size and degree of concern regarding potential malignancy, and local surgical expertise.

Note: All recommendations are category 2A unless otherwise indicated.

Version 3.2025, 10/01/2025 © 2025 National Comprehensive Cancer Network® (NCCN®), All rights reserved. NCCN Guidelines® and this illustration may not be reproduced in any form without the express written permission of NCCN.

PLEASE NOTE that use of this NCCN Content is governed by the End-User License Agreement, and you MAY NOT distribute this Content or use it with any artificial intelligence model or tool.
Printed by Galya Basol Kochav on 1/7/2026 1:55:52 PM. Copyright © 2026 National Comprehensive Cancer Network, Inc. All Rights Reserved.

WORKUP

ACC, additional workup (NE-E 2 of 4):
- **Genetic counseling and testing for inherited genetic syndromes (NE-G)**
- **Consider tumor microsatellite instability (MSI), mismatch repair (MMR), and tumor mutational burden (TMB) testing[o]**

TREATMENT

Localized disease →

Resect tumor and radiographically or clinically evident lymph nodes (open adrenalectomy[g] recommended)[p,q] →

If high risk for local recurrence[s]:
- **Clinical trial (if available)**
- **Consider external beam RT (EBRT) to tumor bed**
- **Consider adjuvant mitotane therapy[t,u,v] (category 3)**

→

FOLLOW-UP

Every 12 wk–12 mo up to 5 y (after 5 y as clinically indicated):
- **Consider chest CT ± contrast, and abdomen CT or MRI with contrast**
- **Consider biomarkers, if tumor initially functional**

Locoregional unresectable or Metastatic disease →

- **Consider observation with chest CT ± contrast and abdomen/pelvis CT or MRI with contrast for clinically indolent disease every 12 wk and biomarkers (if tumor initially functional)**
- **Consider resection of primary tumor and metastases if >90% removable, particularly if functional[r]**
- **Consider local therapy (ie, SBRT, thermal ablative therapies, liver-directed therapy) (NE-K)**
- **Consider systemic therapy preferably in clinical trial (NE-H 8 of 12)**

→

Every 12 wk–12 mo up to 5 y (after 5 y as clinically indicated):
- **Chest CT ± contrast and**
- **Abdomen/pelvis CT or MRI with contrast or FDG-PET/CT (NE-D)**

[g] Yip L, et al. JAMA Surg 2022;157:870-877.
[o] FDA-approved test recommended for determination of TMB.
[p] May require removal of adjacent structures (ie, liver, kidney, pancreas, spleen, diaphragm) for complete resection.
[q] It is important to achieve negative margins and avoid breaching the tumor capsule. There may be an increased risk for local recurrence and peritoneal spread when done with a minimally invasive approach.
[r] If bulky disease, or <90% is removable, surgery can be reconsidered following response to systemic therapy.
[s] High-risk local recurrence features include: positive margins, Ki-67 >10%, rupture of capsule, large size, and high grade.
[t] Monitor mitotane blood levels. Some institutions recommend target levels of 14–20 mcg/mL if tolerated. Steady-state levels may be reached several months after initiation of mitotane. Life-long hydrocortisone ± fludrocortisone replacement usually is required with mitotane.
[u] Mitotane may have more benefit for control of hormone symptoms than control of tumor.
[v] Optimal duration is unknown. The role of adjuvant chemotherapy is under investigation.

Note: All recommendations are category 2A unless otherwise indicated.

Version 3.2025, 10/01/2025 © 2025 National Comprehensive Cancer Network® (NCCN®), All rights reserved. NCCN Guidelines® and this illustration may not be reproduced in any form without the express written permission of NCCN.

PLEASE NOTE that use of this NCCN Content is governed by the End-User License Agreement, and you MAY NOT distribute this Content or use it with any artificial intelligence model or tool.
Printed by Galya Basol Kochav on 1/7/2026 1:55:52 PM. Copyright © 2026 National Comprehensive Cancer Network, Inc. All Rights Reserved.

TUMOR TYPE	EVALUATION[a,b]	FIRST-LINE TREATMENT
PCC/PGL →	**Recommended:** • Plasma free or 24-hour urine fractionated metanephrines and normetanephrines[c,d,e] (NE-E 2 of 4) • Adrenal protocol CT or MRI if not already done (AGT-1) • Genetic counseling and testing for inherited genetic syndromes (NE-G) **As appropriate, if metastatic or multifocal disease suspected[f]:** • Multiphasic[g] abdomen/pelvis CT or MRI (NE-D) • SSTR-PET/CT or SSTR-PET/MRI[d,h,i] (NE-D) • FDG-PET/CT (skull base to mid-thigh) (NE-D) • Chest CT ± contrast • Meta-iodobenzylguanidine (MIBG) scan with single-photon emission CT (SPECT)/CT[j] • Consider molecular profiling of tumor tissue[k]	→ PHEO-2

[a] Principles of Pathology for the Diagnosis of Pheochromocytoma/Paraganglioma (NE-C).
[b] Consider medical alert ID for hormonally secreting PCCs and PGLs in situ or metastatic disease.
[c] Review concurrent medication(s) for those that may interfere with plasma metanephrines evaluation. Elevations that are 3 times above the upper limit of normal are diagnostic.
[d] For cervical PGL, measuring serum and/or 24-hour urine fractionated catecholamines (for dopamine) or methoxytyramine (if available) may be appropriate. Methoxytyramine is helpful as the metabolite of dopamine in cervical tumors but it is not commercially available in many places.
[e] Both catecholamines and metanephrines/normetanephrines can represent false-positive results. Some investigators support the use of fractionated urinary and/or plasma catecholamines as a way to differentiate false-positive results and to differentiate epinephrine-secreting PCC.
[f] Data on the role of functional imaging in PCC/PGL are evolving and the preferred method remains unclear.
[g] Multiphasic imaging studies are performed with IV contrast in arterial and portal venous phases.
[h] SSTR-PET/CT or SSTR-PET/MRI of skull vertex to mid-thigh with multiphase IV contrast when possible.
[i] SSTR-PET tracers (eg, 68Ga-DOTATATE, 64Cu-DOTATATE, and 68Ga-DOTATOC).
[j] MIBG scans are less sensitive than FDG-PET and 68Ga-DOTATATE for metastatic and multifocal PCCs/PGLs (in patients with von Hippel Lindau [VHL] and succinate dehydrogenase [SDH] syndromes but not patients with MEN1 or NF1 syndromes or some patients with sporadic PCC). SPECT/CT imaging of involved sites is recommended. Obtain MIBG scan if considering treatment with I131-MIBG. Timmers HJLM, et al. J Natl Cancer Inst 2012;104:700-708.
[k] Tumor/somatic molecular profiling should be considered for patients with locoregional unresectable/metastatic disease who are candidates for anticancer therapy to identify actionable alterations. Testing on tumor tissue is preferred; however, liquid biopsy can be considered if tumor tissue testing is not feasible.

Note: All recommendations are category 2A unless otherwise indicated.

Version 3.2025, 10/01/2025 © 2025 National Comprehensive Cancer Network® (NCCN®), All rights reserved. NCCN Guidelines® and this illustration may not be reproduced in any form without the express written permission of NCCN.

PLEASE NOTE that use of this NCCN Content is governed by the End-User License Agreement, and you MAY NOT distribute this Content or use it with any artificial intelligence model or tool.
Printed by Galya Basol Kochav on 1/7/2026 1:55:52 PM. Copyright © 2026 National Comprehensive Cancer Network, Inc. All Rights Reserved.

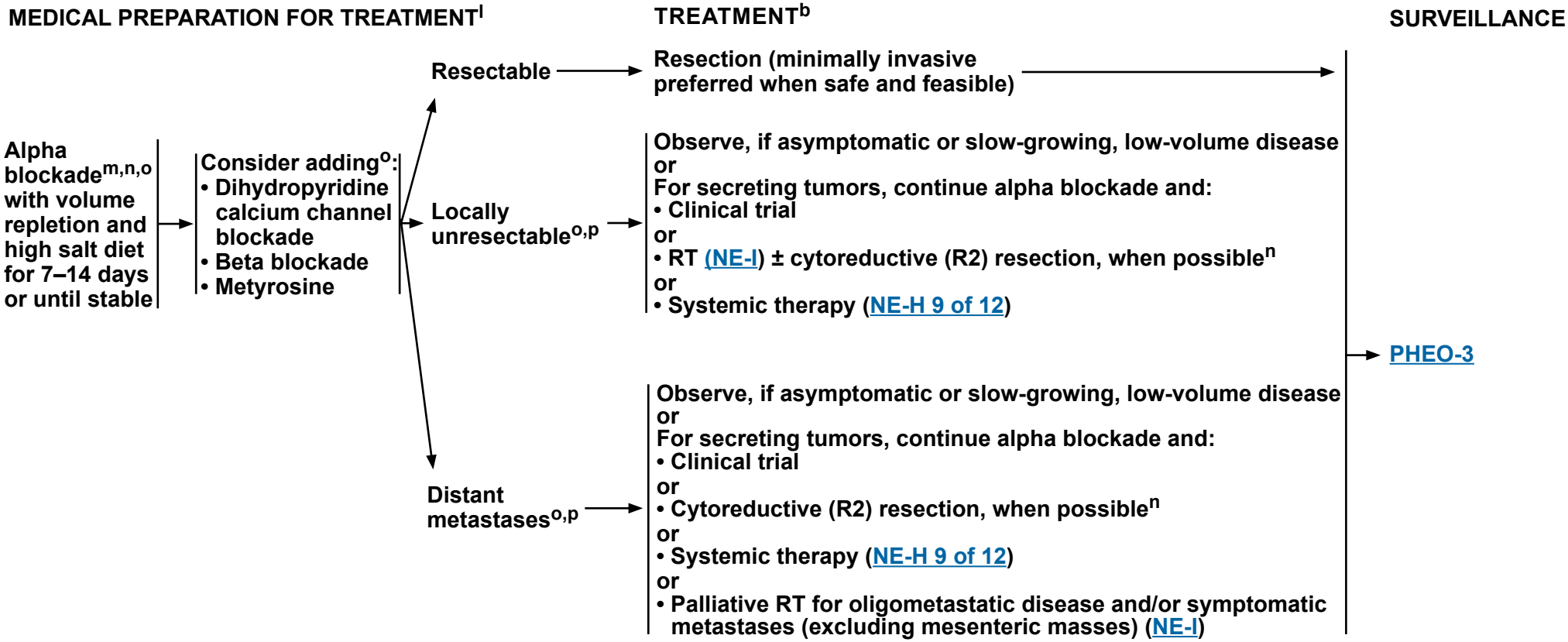

[b] Consider medical alert ID for hormonally secreting PCCs and PGLs in situ or metastatic disease.

[l] Avoid medications that will precipitate hormone-mediated crisis.

[m] If the patient has a hypertensive crisis, consider addition of nitroprusside, phentolamine, or nicardipine for treatment of hypertension. Cardiac arrhythmias can be managed with esmolol or lidocaine. Hypoglycemia and hypotension can be seen post-op. Treat with IV fluids for volume expansion and include dextrose for glucose levels.

[n] Alpha 1 selective receptor blockers include terazosin, doxazosin, and prazosin, and non-selective receptor blockers include phenoxybenzamine. Therapy for 7–14 days is recommended prior to surgical therapy. Nonselective alpha blockade phentolamine (IV) can be used intraoperatively. Doxazosin has a longer half-life and is oftentimes more available than some of the other agents.

[o] Alpha blockade is necessary treatment for all hormonally secreting PCCs and PGLs regardless of clinical symptoms. If additional treatments are planned, patients may need medication adjustments. After alpha blockade, if additional blood pressure support is needed, the addition of dihydropyridine calcium channel blockers can be used. This is not recommended as monotherapy unless the patient cannot tolerate alpha blockade. Metyrosine can also be used in addition to alpha blockade to stabilize blood pressure. Beta blockade can be added to alpha blockade for tachycardia. B1 selective blockers or nonselective beta blockers can be used. Combination beta/alpha blockers are not recommended.

[p] Fishbein L, et al. Pancreas 2021;50:469-493.

Note: All recommendations are category 2A unless otherwise indicated.

Version 3.2025, 10/01/2025 © 2025 National Comprehensive Cancer Network® (NCCN®), All rights reserved. NCCN Guidelines® and this illustration may not be reproduced in any form without the express written permission of NCCN.

PLEASE NOTE that use of this NCCN Content is governed by the End-User License Agreement, and you MAY NOT distribute this Content or use it with any artificial intelligence model or tool.
Printed by Galya Basol Kochav on 1/7/2026 1:55:52 PM. Copyright © 2026 National Comprehensive Cancer Network, Inc. All Rights Reserved.

SURVEILLANCE[q]

Resectable disease (post-resection) →

12 wk–12 mo post-resection[r]:
- H&P, blood pressure, and plasma free or 24-hour urine fractionated metanephrines and normetanephrines[c,d,e] (NE-E 2 of 4)
- Consider chest CT (± contrast) and abdomen/pelvis CT or MRI with contrast

>1 y post-resection up to 10 y:
- H&P, blood pressure, and markers (NE-E 2 of 4)
  - Years 1–3: every 6–12 mo[q]
  - Years 4+ up to 10 y: annually[q]
- Consider chest CT (± contrast) and abdomen/pelvis CT or MRI with contrast

>10 y:
- Consider surveillance as clinically indicated

Locally unresectable disease or Distant metastases →

Every 12 wk–12 mo[r]:
- H&P, blood pressure, and plasma free or 24-hour urine fractionated metanephrines and normetanephrines[c,d,e] (NE-E 2 of 4)
- Consider imaging:
  - Chest/abdomen/pelvis CT with contrast
    or
  - Chest CT (± contrast) and abdomen/pelvis MRI without contrast (if risk for hypertensive episode)
    or
  - MIBG with SPECT/CT (if previous MIBG-positive or concern for disease progression) prior to considering radionuclide therapy
    or
  - FDG-PET/CT for bone-dominant disease (NE-D)
    or
  - SSTR-PET/CT or SSTR-PET/MRI[h,i] (if previous SSTR-positive or concern for disease progression) prior to considering radionuclide therapy (NE-D)

[c] Review concurrent medication(s) for those that may interfere with plasma metanephrines evaluation. Elevations that are 3 times above the upper limit of normal are diagnostic.
[d] For cervical PGL, measuring serum and/or 24-hour urine fractionated catecholamines (for dopamine) or methoxytyramine (if available) may be appropriate. Methoxytyramine is helpful as the metabolite of dopamine in cervical tumors but it is not commercially available in many places.
[e] Both catecholamines and metanephrines/normetanephrines can represent false-positive results. Some investigators support the use of fractionated urinary and/or plasma catecholamines as a way to differentiate false-positive results and to differentiate epinephrine-secreting PCC.
[h] SSTR-PET/CT or SSTR-PET/MRI of skull vertex to mid-thigh with multiphase IV contrast when possible.
[i] SSTR-PET tracers (eg, 68Ga-DOTATATE, 64Cu-DOTATATE, and 68Ga-DOTATOC).
[q] NCCN Guidelines for Survivorship.
[r] Earlier, if symptoms; less frequently if stable disease and no new symptoms.

Note: All recommendations are category 2A unless otherwise indicated.

Version 3.2025, 10/01/2025 © 2025 National Comprehensive Cancer Network® (NCCN®), All rights reserved. NCCN Guidelines® and this illustration may not be reproduced in any form without the express written permission of NCCN.

PLEASE NOTE that use of this NCCN Content is governed by the End-User License Agreement, and you MAY NOT distribute this Content or use it with any artificial intelligence model or tool.
Printed by Galya Basol Kochav on 1/7/2026 1:55:52 PM. Copyright © 2026 National Comprehensive Cancer Network, Inc. All Rights Reserved.

NCCN Guidelines Version 3.2025
Multiple Endocrine Neoplasia, Type 1

Clinical diagnosis of MEN1
- Genetic counseling and testing for inherited genetic syndromes (NE-G)

CLINICAL EVALUATION

Parathyroid:
- Serum calcium
- If calcium elevated:
  - Parathyroid hormone (PTH), 25-OH vitamin D, inorganic phosphate, 24-hour urine calcium and creatinine (NE-E 2 of 4)
  - Imaging[a] (neck ultrasound, parathyroid sestamibi with SPECT scan, or four-dimensional computed tomography [4D-CT]) (NE-D)

PanNET[b]:
- Recommended
  - Biochemical evaluation as clinically indicated (NE-E)
  - Multiphasic[c] abdomen ± pelvis CT or MRI (NE-D)
- As appropriate
  - EUS
  - SSTR-PET/CT or SSTR-PET/MRI[d,e] (NE-D)

Pituitary:
- Recommended
  - Pituitary or sella MRI with contrast
  - Biochemical evaluation as clinically indicated (NE-E 2 of 4)

Lung/Thymic NETs:
- Chest CT with contrast and multiphasic[c] abdomen/pelvis CT or MRI (NE-D)
- Biochemical evaluation as clinically indicated (NE-E)

TREATMENT

Subtotal parathyroidectomy ± cryopreservation of parathyroids ± thymectomy
or
Total parathyroidectomy with autotransplantation ± cryopreservation of parathyroids ± thymectomy

Treatment of PanNETs specific to patients with MEN1 (MEN1-A)
and
See appropriate sporadic PanNET workup and treatment (PanNET-1 through PanNET-10)

Consider referral to endocrinology for further workup

See appropriate workup and treatment for lung (NET-6) or thymic (NET-7) NETs

SURVEILLANCE

MEN1-2

[a] Preference of scan will depend on institutional practice/protocol. Sestamibi may not be as sensitive since often the patient has hyperplasia.
[b] van Treijen MJC, et al. J Endocr Soc 2018;2:1067-1088.
[c] Multiphasic imaging studies are performed with IV contrast in arterial and portal venous phases.
[d] SSTR-PET/CT or SSTR-PET/MRI of skull vertex to mid-thigh with multiphase IV contrast when possible. Data are limited on the optimal timing of scans following administration of SSAs.
[e] SSTR-PET tracers (eg, 68Ga-DOTATATE, 64Cu-DOTATATE, and 68Ga-DOTATOC).

Note: All recommendations are category 2A unless otherwise indicated.

Version 3.2025, 10/01/2025 © 2025 National Comprehensive Cancer Network® (NCCN®), All rights reserved. NCCN Guidelines® and this illustration may not be reproduced in any form without the express written permission of NCCN.

PLEASE NOTE that use of this NCCN Content is governed by the End-User License Agreement, and you MAY NOT distribute this Content or use it with any artificial intelligence model or tool.
Printed by Galya Basol Kochav on 1/7/2026 1:55:52 PM. Copyright © 2026 National Comprehensive Cancer Network, Inc. All Rights Reserved.

MEN1 SURVEILLANCE[f,g]
Patients with MEN1 should be screened for all of the following tumor types, starting at 8–15 years of age[h]:

Parathyroid:
- **Calcium annually** → **If calcium rises:**
  - **PTH**
  - **25-OH vitamin D**
  - **Re-image with neck ultrasound and/or parathyroid sestamibi with SPECT scan (SPECT-CT preferred) or 4D-CT[a,g] (NE-D)**

PanNET:
- **Follow previously elevated serum hormones or as symptoms indicate**
- **Consider abdomen/pelvis CT or MRI[g] with contrast every 1–3 y**
- **Consider serial EUS**

→ **See appropriate sporadic PanNET workup and treatment (PanNET-1 through PanNET-10)**

Pituitary:
- **Pituitary or sella MRI with contrast of pituitary every 3–5 y**
- **Prolactin, insulin-like growth factor 1 (IGF-1), and other previously abnormal pituitary hormones every 3–5 y or as symptoms indicate**

Lung/Thymic NETs:
- **Consider chest CT or MRI[g] with contrast every 1–3 y** → **See appropriate workup and treatment for lung (NET-6) or thymic (NET-7) NETs**

[a] Preference of scan will depend on institutional practice/protocol. Sestamibi may not be as sensitive since often the patient has hyperplasia.
[f] Consider referral to an endocrinologist.
[g] For prolonged surveillance, studies without radiation are preferred.
[h] Newey PJ, et al. J Endocr Soc 2022;6:bvac001; Kamilaris CDC, et al. Front Endocrinol (Lausanne) 2019;10:339; Klein Haneveld MJ, et al. J Clin Endocrinol Metab 2021;106:3515-3525; Goudet P, et al. J Clin Endocrinol Metab 2015;100:1568-1577; Gonçalves TD, et al. J Clin Endocrinol Metab 2014;99:E89-96.

Note: All recommendations are category 2A unless otherwise indicated.

Version 3.2025, 10/01/2025 © 2025 National Comprehensive Cancer Network® (NCCN®), All rights reserved. NCCN Guidelines® and this illustration may not be reproduced in any form without the express written permission of NCCN.

PLEASE NOTE that use of this NCCN Content is governed by the End-User License Agreement, and you MAY NOT distribute this Content or use it with any artificial intelligence model or tool.
Printed by Galya Basol Kochav on 1/7/2026 1:55:52 PM. Copyright © 2026 National Comprehensive Cancer Network, Inc. All Rights Reserved.

TREATMENT OF PanNETs SPECIFIC TO PATIENTS WITH MEN1[1-4]

- **In general, surgical treatment of patients with MEN1 is similar to those with sporadic tumors. Refer to the relevant site-specific recommendations for PanNETs earlier in these guidelines (PanNET-1 through PanNET-10).**
- **However, one notable exception is the multifocality of pancreatoduodenal NETs in patients with MEN1. The role of surgery remains controversial in patients with multifocal tumors.**
- **Decision to resect a pancreatic or duodenal NET in the setting of multifocal disease is complex. If surgery is performed to resect hormonally functional tumor(s), attempts should be made to preoperatively localize the site of the functional tumor. Surgical resection can be considered in the following scenarios:**
  - **Symptomatic functional tumors refractory to medical management**
  - **Tumor >2 cm in size**
  - **Tumor with relatively rapid rate of growth over 6–12 months**
- **Endoscopy with EUS is recommended prior to pancreatic surgery in order to preoperatively assess and localize tumors.**
- **MEN1-associated metastatic PanNETs are often slower growing than metastatic sporadic tumors. Observation can be considered for non-functioning indolent tumors.**

[1] Yates CJ, Newey PJ, Thakker RV. Challenges and controversies in management of pancreatic neuroendocrine tumours in patients with MEN1. Lancet Diabetes Endocrinol 2015;3:895-905.
[2] Frost M, Lines KE, Thakker RV. Current and emerging therapies for PNETs in patients with or without MEN1. Nat Rev Endocrinol 2018;14:216-227.
[3] Faggiano A, Modica R, Lo Calzo F, et al. Lanreotide therapy vs active surveillance in MEN1-related pancreatic neuroendocrine tumors < 2 centimeters. J Clin Endocrinol Metab 2020;105:dgz007.
[4] Niederle B, Selberherr A, Bartsch DK, et al. Multiple endocrine neoplasia type 1 (MEN1) and the pancreas: Diagnosis and treatment of functioning and non-functioning pancreatic and duodenal neuroendocrine neoplasia within the MEN1 syndrome - An International Consensus Statement. Neuroendocrinology 2021;111:609-630.

Note: All recommendations are category 2A unless otherwise indicated.

Version 3.2025, 10/01/2025 © 2025 National Comprehensive Cancer Network® (NCCN®), All rights reserved. NCCN Guidelines® and this illustration may not be reproduced in any form without the express written permission of NCCN.

PLEASE NOTE that use of this NCCN Content is governed by the End-User License Agreement, and you MAY NOT distribute this Content or use it with any artificial intelligence model or tool.
Printed by Galya Basol Kochav on 1/7/2026 1:55:52 PM. Copyright © 2026 National Comprehensive Cancer Network, Inc. All Rights Reserved.

NCCN Guidelines Version 3.2025
Multiple Endocrine Neoplasia, Type 2

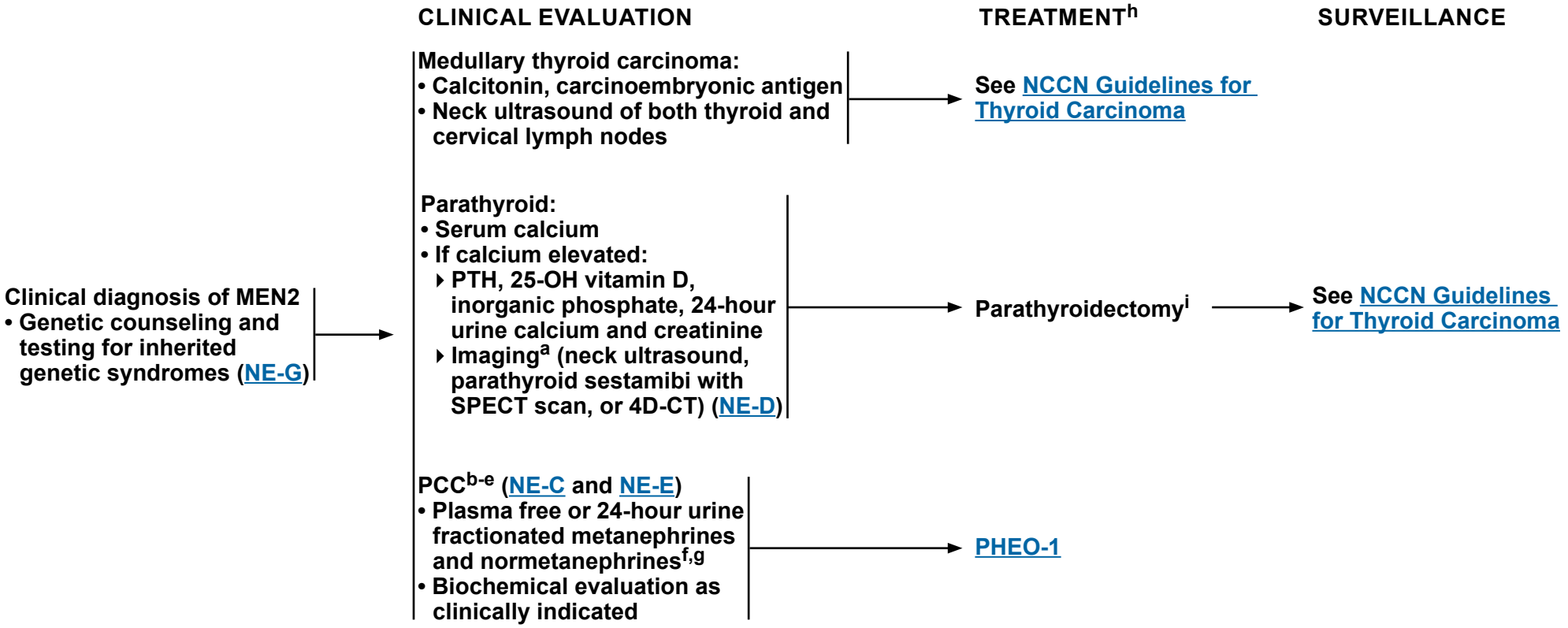

[a] Preference of scan will depend on institutional practice/protocol. Sestamibi scan may not be as sensitive as other imaging options since often the patient has hyperplasia.
[b] Evaluation of PCC should be done before the administration of any anesthetic or invasive procedure.
[c] More likely to be multifocal.
[d] For synchronous bilateral PCCs, a bilateral adrenalectomy is recommended.
[e] Consider medical alert ID for hormonally secreting PCCs in situ or metastatic disease.
[f] Review concurrent medication(s) for those that may interfere with plasma metanephrines evaluation. Elevations that are 3 times above the upper limit of normal are diagnostic.
[g] Both catecholamines and metanephrines/normetanephrines can represent false-positive results. Some investigators support the use of fractionated urinary and/or plasma catecholamines as a way to differentiate false-positive results and to differentiate epinephrine-secreting PCC.
[h] For the treatment of synchronous tumors, surgical resection of PCC should take priority over thyroidectomy for medullary thyroid carcinoma.
[i] Subtotal parathyroidectomy is recommended when all the parathyroid glands are abnormal. Some thyroid surgeons recommend total parathyroidectomy with parathyroid autotransplantation, but others believe the risk of hypoparathyroidism (~6%) is too high to warrant this procedure.

Note: All recommendations are category 2A unless otherwise indicated.

Version 3.2025, 10/01/2025 © 2025 National Comprehensive Cancer Network® (NCCN®), All rights reserved. NCCN Guidelines® and this illustration may not be reproduced in any form without the express written permission of NCCN.

PLEASE NOTE that use of this NCCN Content is governed by the End-User License Agreement, and you MAY NOT distribute this Content or use it with any artificial intelligence model or tool.
Printed by Galya Basol Kochav on 1/7/2026 1:55:52 PM. Copyright © 2026 National Comprehensive Cancer Network, Inc. All Rights Reserved.

PRINCIPLES OF PATHOLOGY FOR THE DIAGNOSIS OF NEUROENDOCRINE NEOPLASMS[1]

Required Information:

- **Diagnosis and differentiation:**
  - **Broad-spectrum keratin marker (to distinguish PCC/PGL)**
  - **2 of 3 immunohistochemistry (IHC) markers (synaptophysin, chromogranin A, and INSM1)**
  - **In cases of mixed neuroendocrine neoplasms (with the smaller tumor component at least 30% of the total tumor mass), each component must be diagnosed and graded based on AJCC tumor nomenclature and following the criteria of tumor differentiation.**
- **Grade (for well-differentiated NETs):**
  - **Ki-67 proliferative index (preferred, unless there is insufficient tissue) and/or mitotic rate**
- **Site of origin:**
  - **Clinical (including radiologic/endoscopic) information is used to determine if it is primary or metastatic, and if metastatic, the possible site of primary.**
- **For resected specimens (surgical/endoscopic):**
  - **Tumor foci (unifocal/presence of multicentric disease)**
  - **Tumor size and extent (tumor node metastasis [TNM] stage per the AJCC TNM system [ST-1])**
  - **Presence of lymphovascular invasion**
  - **Presence of perineural invasion**
  - **Margin status (report as positive or negative)**
  - **Lymph node status (including presence and size of mesenteric masses in gross report for jejunal and ileal NETs) (ST-1)**
    - **Include the number of positive nodes and total number of nodes examined**
- **Background mucosal pathology for clinicopathologic subtyping of gastric NETs (gNETs):**
  - **Secondary: Arising in gastric body mucosa linked to an underlying etiology:**
    - **Type 1: Hypergastrinemia with histologic evidence of background atrophy (either autoimmune or chronic *H. pylori* infection) associated with enterochromaffin-like (ECL)-cell hyperplasia.**
    - **Type 2: Hypergastrinemia from underlying gastrinoma with histologic evidence of parietal cell hyperplasia and ECL-cell hyperplasia.**
    - **Other: Hypergastrinemia (other than type 2) without evidence of underlying gastrinoma but with histologic evidence of parietal cell hyperplasia and ECL-cell hyperplasia, consider PPI-associated gNET.[2] Other rare causes include insufficient proton pump activity due to underlying mutation.[3]**
  - **Primary: No underlying etiology identified and arising in normal background mucosa (either from gastric body or antrum):**
    - **Type 3: sporadic.**
- **Presence of other pathologic components (eg, non-neuroendocrine components)**

References

Note: All recommendations are category 2A unless otherwise indicated.

Version 3.2025, 10/01/2025 © 2025 National Comprehensive Cancer Network® (NCCN®), All rights reserved. NCCN Guidelines® and this illustration may not be reproduced in any form without the express written permission of NCCN.

PLEASE NOTE that use of this NCCN Content is governed by the End-User License Agreement, and you MAY NOT distribute this Content or use it with any artificial intelligence model or tool.
Printed by Galya Basol Kochav on 1/7/2026 1:55:52 PM. Copyright © 2026 National Comprehensive Cancer Network, Inc. All Rights Reserved.

PRINCIPLES OF PATHOLOGY FOR THE DIAGNOSIS OF NEUROENDOCRINE NEOPLASMS[1]

Optional Information:

- **IHC staining[4,5]**
  - **Site-specific markers (eg, TTF-1, CDX2, SATB2) can be used as indicated in well-differentiated NET.[6]**
  - **In challenging cases of high-grade neuroendocrine neoplasm, especially for pancreatic neuroendocrine neoplasm, Rb, p53,[7] p16, ATRX, and DAXX may be used as a panel to help distinguish grade 3 NETs from NECs.[a]**
  - **If there is a clinical suspicion of Merkel cell carcinoma, CK20 and Merkel cell polyomavirus stains may be used.**
  - **Additional stains (eg, trypsin, chymotrypsin, BCL10) may be used in higher grade pancreatic neoplasms to exclude acinar cell carcinoma expressing neuroendocrine markers.**
  - **Hormone staining with IHC is not helpful and, if positive, it does not mean there is a functional tumor.**
- **Additional workup may be used as indicated if the morphology or staining characteristics are unusual.**

Functional Status

- **Functioning NETs should have the same pathologic diagnosis as the non-functioning NETs at the same anatomic site, since the functional status is based upon clinical symptoms and should not alter the pathologic diagnosis.**

Classification and Grade[8]

- **Many classification schemes have been proposed for NETs.[9-16] The most recent WHO classification system is suggested for gastroenteropancreatic (GEP) NETs and represents an attempt to unify European and American approaches.[15] Multiple site-specific grading systems also exist.**
  - **Ki-67 Index:**
    - **Follow College of American Pathologists guidelines for assessment and specify exact Ki-67 proliferative index in report, not a range.**
      - **Ki-67 index is reported as the percentage of positive tumor cells in the area of highest nuclear labeling (referred to as hot spots).**
      - **Ki-67 should be performed on all types of specimens, primary or metastatic, biopsy or resection (as long as there are at least 500 tumor cells present and the specimen is assessable without crush artifact or significant intermixed inflammatory cells).**
      - **Ki-67 proliferative index should also be assessed for every specimen sampled metachronously. For multiple sections sampled from a single tumor, Ki-67 stain should be performed on the block(s) of tumor with the highest mitotic index. Multiple tumor blocks may be used for this staining, and the tumor grade would be based on the highest proliferative index (specific example: Ki-67 proliferative index assessed for every focus of multifocal ileal NET as well as from mesenteric mass). When there are synchronous specimens from multiple primary tumors(s) and/or metastases, Ki-67 should be performed on at least 1 block from each of the primary and metastatic locations.**

[a] Clinical, functional imaging, and molecular features should be taken into account as well.

References

Note: All recommendations are category 2A unless otherwise indicated.

Version 3.2025, 10/01/2025 © 2025 National Comprehensive Cancer Network® (NCCN®), All rights reserved. NCCN Guidelines® and this illustration may not be reproduced in any form without the express written permission of NCCN.

PLEASE NOTE that use of this NCCN Content is governed by the End-User License Agreement, and you MAY NOT distribute this Content or use it with any artificial intelligence model or tool.
Printed by Galya Basol Kochav on 1/7/2026 1:55:52 PM. Copyright © 2026 National Comprehensive Cancer Network, Inc. All Rights Reserved.

PRINCIPLES OF PATHOLOGY FOR THE DIAGNOSIS OF NEUROENDOCRINE NEOPLASMS[1]

Classification and Grade[8] (continued)

- **Mitotic Rate:**
  - ◊ **Mitotic rate should be based on counting mitoses in the areas of highest mitotic density, and should be reported as the number of mitoses per 2 mm^2.**
  - ◊ **Note that in cases where an accurate mitotic rate is precluded by inadequate tissue, such as in small biopsy samples including fine-needle aspiration, the Ki-67 index is the preferred method of establishing the proliferative rate.**
- **If both mitotic rate and Ki-67 index are used and these are discordant, it is currently recommended that the higher grade be used to assign classification.[17]**
- **The pathologist should report the actual parameters used to assign grade (ie, mitotic rate, proliferation index) so clinicians have the necessary information to make informed treatment decisions.**
- **Specific classification and grading scheme being utilized should be reported in parentheses after the diagnosis to avoid confusion with overlapping terminology and criteria used in other systems.**
- **The raw data used to derive the grade should be reported.**
- **Regardless of the system used, it is most important to realize that the term "neuroendocrine tumor" or "neuroendocrine carcinoma" without any further qualification as to grade is inadequate for prognostication and therapy and is inappropriate for pathology reporting.[6,18]**

Special Considerations:

- **Keratin and neuroendocrine markers can be positive in certain neoplasms that may morphologically resemble, but are not classic neuroendocrine neoplasms. They are treated differently; therefore, correct identification or exclusion of these neoplasms in the appropriate clinical context is necessary. These include (but are not limited to) pancreatic acinar cell carcinomas, Merkel cell carcinomas, Ewing sarcoma, and desmoplastic round cell tumor. The terminology "carcinoma with neuroendocrine features" or "adenocarcinoma with neuroendocrine features" should be avoided, and a definite WHO-recommended tumor classification should be attempted (adenocarcinomas in the GI tract can often express neuroendocrine markers patchily, without any survival or management significance).[19] In case of ambiguous histology and challenges in interpreting the neoplasm, this should be stated clearly in the report, indicating the importance of clinical correlation, and recommending molecular testing (broad next-generation sequencing [NGS] panel).**

References

Note: All recommendations are category 2A unless otherwise indicated.

Version 3.2025, 10/01/2025 © 2025 National Comprehensive Cancer Network® (NCCN®), All rights reserved. NCCN Guidelines® and this illustration may not be reproduced in any form without the express written permission of NCCN.

PLEASE NOTE that use of this NCCN Content is governed by the End-User License Agreement, and you MAY NOT distribute this Content or use it with any artificial intelligence model or tool.
Printed by Galya Basol Kochav on 1/7/2026 1:55:52 PM. Copyright © 2026 National Comprehensive Cancer Network, Inc. All Rights Reserved.

PRINCIPLES OF PATHOLOGY FOR THE DIAGNOSIS OF NEUROENDOCRINE NEOPLASMS[1]

2019 WHO Classification and Grading Criteria for Neuroendocrine Neoplasms of the Gastrointestinal Tract and Hepatopancreatobiliary Organs

Terminology	Differentiation	Grade	Mitotic Rate[b] (mitoses/2 mm^2)	Ki-67 Index[b] (percent)
NET, G1	Well-differentiated	Low	<2	<3
NET, G2	Well-differentiated	Intermediate	2 to 20	3 to 20
NET, G3	Well-differentiated	High	>20	>20
Neuroendocrine carcinoma (NEC), small cell type (SCNEC)	Poorly differentiated	High[c]	>20	>20
NEC, large cell type (LCNEC)	Poorly differentiated	High[c]	>20	>20
MiNEN	Well or poorly differentiated[d]	Variable[d]	Variable[d]	Variable[d]

Adapted with permission from: Klimstra DS, Klöppel G, La Rosa S, et al. Classification of neuroendocrine neoplasms of the digestive system. In: WHO Classification of Tumours Editorial Board. Digestive system tumours [Internet]. Lyon (France): International Agency for Research on Cancer; 2019 [cited 2023 July 24]. (WHO classification of tumours series, 5th ed.; vol. 1). Available from: https://tumourclassification.iarc.who.int/chapters/31.

[b] Mitotic rates are to be expressed as the number of mitoses/2 mm^2 (equaling 10 high-power fields at 40x magnification and an ocular field diameter of 0.5 mm) as determined by counting in 50 fields of 0.2 mm^2 (ie, in a total area of 10 mm^2); the Ki-67 proliferation index value is determined by counting at least 500 cells in the regions of highest labeling (hot spots), which are identified at scanning magnification; the final grade is based on whichever of the two proliferation indexes places the neoplasm in the higher grade category.
[c] PDNECs are not formally graded but are considered high grade by definition.
[d] In most MiNENs, both the neuroendocrine and non-neuroendocrine components are poorly differentiated, and the neuroendocrine component has proliferation indexes in the same range as other NECs, but this conceptual category allows for the possibility that one or both components may be well differentiated; when feasible, each component should therefore be graded separately.

Note: All recommendations are category 2A unless otherwise indicated.

References

Version 3.2025, 10/01/2025 © 2025 National Comprehensive Cancer Network® (NCCN®), All rights reserved. NCCN Guidelines® and this illustration may not be reproduced in any form without the express written permission of NCCN.

PLEASE NOTE that use of this NCCN Content is governed by the End-User License Agreement, and you MAY NOT distribute this Content or use it with any artificial intelligence model or tool.
Printed by Galya Basol Kochav on 1/7/2026 1:55:52 PM. Copyright © 2026 National Comprehensive Cancer Network, Inc. All Rights Reserved.

PRINCIPLES OF PATHOLOGY FOR THE DIAGNOSIS OF NEUROENDOCRINE NEOPLASMS[1]

2021 WHO Criteria for the Diagnosis of Lung Neuroendocrine Tumors

Tumor Type	Criteria
Typical carcinoid	A tumour ≥5 mm with carcinoid morphology and <2 mitoses/2 mm^2, lacking necrosis
Atypical carcinoid	A tumour with carcinoid morphology and 2–10 mitoses/2 mm^2 and/or necrosis (often punctuate) or both
Large cell neuroendocrine carcinoma	• A tumour with neuroendocrine morphology (organoid nesting, palisading, rosettes, trabeculae) • High mitotic count: >10 mitoses/2 mm^2, median of 70 mitoses/2 mm^2 • Necrosis (often in large zones) • Cytologic features of a non-small cell carcinoma, as well as large cell size; low N:C ratio; vesicular, coarse, or fine chromatin; and/or frequent nucleoli; some tumors have fine nuclear chromatin and lack nucleoli but qualify as non-small cell carcinoma because of large cell size and abundant cytoplasm • Positive immunohistochemical staining for one or more neuroendocrine markers (other than NSE)
Small cell lung carcinoma	• Small size (generally less than the diameter of 3 small resting lymphocytes) • Scant cytoplasm • Nuclei: finely granular nuclear chromatin, absent or faint nucleoli • High mitotic count: >10 mitoses/2 mm^2, median of 80 mitoses/2 mm^2 • Frequent necrosis (often in large zones)

N:C = nucleus to cytoplasm
NSE = neuron-specific enolase

Adapted with permission from: Travis WD, Cree IA, Papotti M, et al. Lung neuroendocrine neoplasms: Introduction. In: WHO Classification of Tumours Editorial Board. Thoracic Tumours [Internet]. Lyon (France): International Agency for Research on Cancer; 2021 [cited 2023 July 24]. (WHO classification of tumours series, 5th ed.; vol. 5). Available from: https://tumourclassification.iarc.who.int/chapters/35.

References

Note: All recommendations are category 2A unless otherwise indicated.

Version 3.2025, 10/01/2025 © 2025 National Comprehensive Cancer Network® (NCCN®), All rights reserved. NCCN Guidelines® and this illustration may not be reproduced in any form without the express written permission of NCCN.

PLEASE NOTE that use of this NCCN Content is governed by the End-User License Agreement, and you MAY NOT distribute this Content or use it with any artificial intelligence model or tool.
Printed by Galya Basol Kochav on 1/7/2026 1:55:52 PM. Copyright © 2026 National Comprehensive Cancer Network, Inc. All Rights Reserved.

PRINCIPLES OF PATHOLOGY FOR THE DIAGNOSIS OF NEUROENDOCRINE NEOPLASMS[1]

2021 WHO Classification for Neuroendocrine Neoplasms of the Thymus

Current Classification of Tumours with Neuroendocrine Morphology			
Low-Grade	**Intermediate-Grade**	**High-Grade**	
Typical carcinoid • No necrosis • <2 mitoses/2 mm^2 (mean: 1 mitosis/2 mm^2)	Atypical carcinoid • Necrosis present (any) and/or • 2–10 mitoses/2 mm^2 (mean: 6.5 mitoses/2 mm^2)	Large cell neuroendocrine carcinoma • Non-small cell cytology • Neuroendocrine markers • >10 mitoses/2 mm^2 (mean: 45 mitoses/2 mm^2) • Frequent necrosis	Small cell carcinoma • Small cell cytology • >10 mitoses/2 mm^2 (mean: 110 mitoses/2 mm^2)

Adapted with permission from: Ströbel P, Marchevsky AM, Marom EM, et al. Thymic neuroendocrine neoplasms: Introduction. In: WHO Classification of Tumours Editorial Board. Thoracic Tumours. Lyon (France): International Agency for Research on Cancer; 2021 [cited 2023 July 24]. (WHO classification of tumours series, 5th ed.; vol. 5). Available from: https://tumourclassification.iarc.who.int/chapters/35.

References

Note: All recommendations are category 2A unless otherwise indicated.

Version 3.2025, 10/01/2025 © 2025 National Comprehensive Cancer Network® (NCCN®), All rights reserved. NCCN Guidelines® and this illustration may not be reproduced in any form without the express written permission of NCCN.

PLEASE NOTE that use of this NCCN Content is governed by the End-User License Agreement, and you MAY NOT distribute this Content or use it with any artificial intelligence model or tool.
Printed by Galya Basol Kochav on 1/7/2026 1:55:52 PM. Copyright © 2026 National Comprehensive Cancer Network, Inc. All Rights Reserved.

PRINCIPLES OF PATHOLOGY FOR THE DIAGNOSIS OF NEUROENDOCRINE NEOPLASMS
REFERENCES

[1] Rindi G, Mete O, Uccella S, et al. Overview of the 2022 WHO classification of neuroendocrine neoplasms. Endocr Pathol 2022;33:115-154.
[2] Rais R, Trikalinos NA, Liu J, Chatterjee D. Enterochromaffin-like cell hyperplasia-associated gastric neuroendocrine tumors may arise in the setting of proton pump inhibitor use. Arch Pathol Lab Med 2022;146:366-371.
[3] Fossmark R, Calvete O, Mjønes P, Benitez J, Waldum HL. ECL-cell carcinoids and carcinoma in patients homozygous for an inactivating mutation in the gastric H(+) K(+) ATPase alpha subunit. APMIS 2016;124:561-566.
[4] Bellizzi AM. Immunohistochemistry in the diagnosis and classification of neuroendocrine neoplasms: What can brown do for you? Hum Pathol 2020;96:8-33.
[5] Duan K, Mete O. Algorithmic approach to neuroendocrine tumors in targeted biopsies: Practical applications of immunohistochemical markers. Cancer Cytopathol 2016;124:871-884.
[6] Klimstra DS, Modlin IR, Coppola D, et al. The pathologic classification of neuroendocrine tumors: a review of nomenclature, grading, and staging systems. Pancreas 2010;39:707-712.
[7] Li J, Wang J, Su D, et al. p53 immunohistochemistry patterns are surrogate biomarkers for *TP53* mutations in gastrointestinal neuroendocrine neoplasms. Gastroenterol Res Pract 2021;2021:2510195.
[8] Rindi G, Klimstra DS, Abedi-Ardekani B, et al. A common classification framework for neuroendocrine neoplasms: an International Agency for Research on Cancer (IARC) and World Health Organization (WHO) expert consensus proposal. Mod Pathol 2018;31:1770-1786.
[9] WHO Classification of Tumours Editorial Board. Endocrine and neuroendocrine tumours [Internet]. Lyon (France): International Agency for Research on Cancer; 2022 [cited 2023 July 24]. (WHO classification of tumours series, 5th ed.; vol. 10). Available from: https://tumourclassification.iarc.who.int/chapters/53.
[10] Rindi G, Kloppel G, Alhman H, et al. TNM staging of foregut (neuro)endocrine tumors: a consensus proposal including a grading system. Virchows Arch 2006;449:395-401.
[11] Washington MK, Tang LH, Berlin J, et al. Protocol for the examination of specimens from patients with neuroendocrine tumors (carcinoid tumors) of the colon and rectum. Arch Pathol Lab Med 2010;134:176-180.
[12] Strosberg JR, Coppola D, Klimstra DS, et al. The NANETS consensus guidelines for the diagnosis and management of poorly differentiated (high-grade) extrapulmonary neuroendocrine carcinomas. Pancreas 2010;39:799-800.
[13] Boudreaux JP, Klimstra DS, Hassan MM, et al. The NANETS consensus guideline for the diagnosis and management of neuroendocrine tumors: well-differentiated neuroendocrine tumors of the jejunum, ileum, appendix, and cecum. Pancreas 2010;39:753-766.
[14] Anthony LB, Strosberg JR, Klimstra DS, et al. The NANETS consensus guidelines for the diagnosis and management of gastrointestinal neuroendocrine tumors (NETs): well-differentiated NETs of the distal colon and rectum. Pancreas 2010;39:767-774.
[15] Klimstra DS, Klöppel G, La Rosa S, et al. WHO classification of tumors: Digestive system tumors, 5th ed. Lyon (France): International Agency for Research on Cancer; 2019.
[16] Oberg K, Castellano D. Current knowledge on diagnosis and staging of neuroendocrine tumors. Cancer Metastasis Rev 2011;30S:S3-S7.
[17] Rindi G, Bordi C, La Rosa S, et al. Gastroenteropancreatic (neuro)endocrine neoplasms: The histology report. Dig Liver Dis 2011;43S:S356-S360.
[18] Klimstra DS, Modlin IR, Adsay NV, et al. Pathology reporting of neuroendocrine tumors: application of the Delphic consensus process to the development of a minimum pathology data set. Am J Surg Pathol 2010;34:300-313.
[19] Konukiewitz B, Kasajima A, Schmitt M, et al. Neuroendocrine differentiation in conventional colorectal adenocarcinomas: Incidental finding or prognostic biomarker? Cancers (Basel) 2021;13:5111.

Note: All recommendations are category 2A unless otherwise indicated.

Version 3.2025, 10/01/2025 © 2025 National Comprehensive Cancer Network® (NCCN®), All rights reserved. NCCN Guidelines® and this illustration may not be reproduced in any form without the express written permission of NCCN.

PLEASE NOTE that use of this NCCN Content is governed by the End-User License Agreement, and you MAY NOT distribute this Content or use it with any artificial intelligence model or tool.
Printed by Galya Basol Kochav on 1/7/2026 1:55:52 PM. Copyright © 2026 National Comprehensive Cancer Network, Inc. All Rights Reserved.

PRINCIPLES OF PATHOLOGY FOR THE DIAGNOSIS OF ADRENOCORTICAL CARCINOMA[1,2]

Required Information:
- Tumor laterality
- Adrenal gland weight
- Size of the tumor
- Extent of tumor invasion
- Histologic subtypes
- Mitotic tumor grade based on mitosis count per 10 mm^2 in the area with the highest mitotic activity (applicable to adult tumor only):
  - Low grade, ≤20 mitoses per 10 mm^2
  - High grade, >20 mitoses per10 mm^2
- Ki-67 proliferation index at hot spots assessed manually on printed images or by validated automated image analysis
- Presence of lymphatic and or vascular invasion
- Margin status
- Regional lymph node status
  - Include number of lymph nodes examined and number of positive lymph nodes
- Distant metastasis, if applicable
- Pathologic staging (ST-13)

Optional Information:
- IHC and special staining:
  - SF1 (the most reliable marker confirming adrenocortical origin)
  - Melan-A, calretinin, synaptophysin, and alpha-inhibin (less specific biomarkers)
  - PHH3 is helpful in highlighting mitosis
  - Reticulin special stain shows loss of nested architecture in carcinoma
  - p53 and beta-catenin may help identify aggressive tumors

Special Considerations:
- Pathology diagnosis of ACC is based on morphologic and/or IHC evidence of differentiation (SF1 is the most specific marker confirming adrenocortical origin) and evidence of malignancy based on one of several applicable multiparameter scoring systems. Histology features assessed in the scoring systems include invasive growth (eg, angioinvasion, capsular invasion, local gross invasion), Ki-67 proliferation index, mitotic count, atypical mitosis, tumor necrosis, and a combination of cytologic and architectural features.
  - The multiparameter scoring systems are Weiss, Modified Weiss, Reticulin algorithm, Helsinki score, and Lin-Weiss-Bisceglia system for adult adrenocortical tumor and Wieneke Criteria for pediatric adrenocortical tumor. Meeting the criteria based on one of the applicable multiparameter scoring systems supports the diagnosis of ACC.

[1] Mete O, Erickson LA, Juhlin CC, et al. Overview of the 2022 WHO classification of adrenal cortical tumors. Endocr Pathol 2022;33:155-196.
[2] Giordano TJ, Berney D, de Krijger RR, et al. Data set for reporting of carcinoma of the adrenal cortex: Explanations and recommendations of the guidelines from the International Collaboration on Cancer Reporting. Hum Pathol 2021;110:50-61.

Note: All recommendations are category 2A unless otherwise indicated.

Version 3.2025, 10/01/2025 © 2025 National Comprehensive Cancer Network® (NCCN®), All rights reserved. NCCN Guidelines® and this illustration may not be reproduced in any form without the express written permission of NCCN.

PLEASE NOTE that use of this NCCN Content is governed by the End-User License Agreement, and you MAY NOT distribute this Content or use it with any artificial intelligence model or tool.
Printed by Galya Basol Kochav on 1/7/2026 1:55:52 PM. Copyright © 2026 National Comprehensive Cancer Network, Inc. All Rights Reserved.

PRINCIPLES OF PATHOLOGY FOR THE DIAGNOSIS OF PHEOCHROMOCYTOMA/PARAGANGLIOMA[1,2]

Required Information:
- Tumor focality
- Anatomic site of tumor
- Size of the tumor
- Extent of tumor invasion
- Margin status
- Regional lymph node status
  - Include number of lymph nodes examined and number of positive lymph nodes
- Distant metastasis, if applicable
- Tumor proliferation rate
  - Assess Ki-67 proliferation index and mitotic count from areas with the highest proliferative activities (hot spots). Ki-67 proliferation index can be done either manually on printed images or by validated automated image analysis.
- Positive for 2 of 3 IHC markers for NETs (synaptophysin, chromogranin A, and INSM1)
- Negative for broad-spectrum keratin marker (to distinguish PCC/PGL from other NETs)
- S100 and SOX10 stains of sustentacular cells
- Morphologic parameters for risk stratification
  - High proliferation rate (mitotic count and Ki-67 proliferation index), comedonecrosis, diffuse growth pattern, and high cellularity

Optional Information:
- IHC stain of tyrosine hydroxylase, dopamine beta-hydroxylase, and GATA3
- Loss of succinate dehydrogenase complex iron sulfur subunit B (SDHB) by IHC can guide genetic testing for *SDHx* gene mutation.
- Loss of fumarate hydratase (FH) together with overexpression of 2-succinocysteine (2SC) by IHC can guide the screening for FH-related tumors.

Special Considerations:
- All PCCs and PGLs should be considered potentially malignant with a lifelong risk of metastasis; the adjectives "benign" and "malignant" should not be used in pathology diagnosis.
- Several systems including Pheochromocytoma of the Adrenal gland Scaled Score (PASS), Grading of Adrenal Pheochromocytoma and Paraganglioma (GAPP), modified GAPP, and Composite Pheochromocytoma/Paraganglioma Prognostic Score (COPPS) have been proposed to predict the risk of metastasis. No individual system is currently endorsed for routine use.

[1] Mete O, Asa SL, Gill AJ, et al. Overview of the 2022 WHO classification of paragangliomas and pheochromocytomas. Endocr Pathol 2022;33:90-114.
[2] Thompson LDR, Gill AJ, Asa SL, et al. Data set for the reporting of pheochromocytoma and paraganglioma: Explanations and recommendations of the guidelines from the International Collaboration on Cancer Reporting. Hum Pathol 2021;110:83-97.

Note: All recommendations are category 2A unless otherwise indicated.

Version 3.2025, 10/01/2025 © 2025 National Comprehensive Cancer Network® (NCCN®), All rights reserved. NCCN Guidelines® and this illustration may not be reproduced in any form without the express written permission of NCCN.

PLEASE NOTE that use of this NCCN Content is governed by the End-User License Agreement, and you MAY NOT distribute this Content or use it with any artificial intelligence model or tool.
Printed by Galya Basol Kochav on 1/7/2026 1:55:52 PM. Copyright © 2026 National Comprehensive Cancer Network, Inc. All Rights Reserved.

PRINCIPLES OF IMAGING

Anatomic Imaging

- **Cross-sectional imaging should include the primary site of disease. Either CT or MRI is appropriate.**
- **The liver is a common metastatic site for NET, and these metastatic lesions are often hypervascular. Multiphase (dual-phase) contrast-enhanced (arterial and portal venous phase) CT is important because NETs frequently enhance in the arterial phase. SSTR-PET/CT should be interpreted in combination with dual-phase CT or MRI to identify both SSTR(+) and SSTR(-) sites of disease. PET/CT and PET/MRI scanners are capable of providing full diagnostic multiphase contrast-enhanced CT and MRI scans. This provides the most accurate correlation of anatomic sites and receptor status. When possible, SSTR-PET/CT and SSTR-PET/MRI should be performed concurrently with diagnostic multiphase CT or MRI.**
- **Without a known tumor or specific clinical concern, imaging should include chest CT ± contrast and imaging of the brain is generally not required for well-differentiated NET.**
- **For metastatic well-differentiated NET, anatomic imaging should generally be performed every 12 weeks–12 months based on clinical or pathologic signs of aggressiveness.**
- **Consider MRI over CT to minimize radiation risk.**

Functional Imaging[a]

- **Evaluation with SSTR imaging to assess receptor status and distant disease is appropriate. This is especially important for determining whether a patient may benefit from SSTR-directed therapy.**
  - **SSTR-based imaging options include SSTR-PET/CT or SSTR-PET/MRI, or octreotide SPECT/CT (only if SSTR-PET is not available).**
  - **Examples of appropriate SSTR-PET tracers: 68Ga-DOTATATE, 68Ga-DOTATOC, or 64Cu-DOTATATE.**
  - **SSTR-positive if uptake in measurable lesions is greater than liver.**
- **Whenever possible, SSTR-PET/CT should be performed in combination with contrast-enhanced CT or MRI (dual-phase hepatic CT or MRI imaging preferred) to minimize the total number of imaging studies. The contrast-enhanced CT or MRI is vital to identify lesions that are SSTR-negative as well as those that are SSTR-positive.**
- **Octreotide SPECT/CT is much less sensitive for defining SSTR-positive disease than SSTR-PET/CT, and typically cannot be done in combination with multiphase CT or MRI. Therefore, SSTR-PET/CT or SSTR-PET/MRI is preferred.**
- **FDG-PET should be considered in select cases where G2 or higher NETs or NECs is documented.**
- **As with SSTR-PET/CT, combining FDG-PET with dual-phase liver CT or MRI is preferred.**
- **Combining FDG-PET and SSTR-PET, even for lower grade tumors, and a combined score of FDG-PET and SSTR-PET gives more prognostic value and outperforms pathologic grading.[1]**

[a] Data on the role of functional imaging in PCC/PGL is evolving and the preferred method remains unclear.

References

Note: All recommendations are category 2A unless otherwise indicated.

Version 3.2025, 10/01/2025 © 2025 National Comprehensive Cancer Network® (NCCN®), All rights reserved. NCCN Guidelines® and this illustration may not be reproduced in any form without the express written permission of NCCN.

PLEASE NOTE that use of this NCCN Content is governed by the End-User License Agreement, and you MAY NOT distribute this Content or use it with any artificial intelligence model or tool.
Printed by Galya Basol Kochav on 1/7/2026 1:55:52 PM. Copyright © 2026 National Comprehensive Cancer Network, Inc. All Rights Reserved.

PRINCIPLES OF IMAGING

Surveillance

- **After potentially curative surgery, surveillance is recommended for at least 10 years for most patients. In certain cases, surveillance may be extended beyond 10 years based on risk factors such as age and risk of recurrence. However, data are limited on the optimal surveillance schedule beyond 10 years.**

Transthoracic Echocardiogram to Assess for Carcinoid (NET-Related) Heart Disease[2,3]

- **Transthoracic echocardiogram (TTE) is important for the evaluation of CHD and should include morphologic evaluation of the valves (especially tricuspid and pulmonary), as well as assessment of the right heart size and function. When valve disease is present, an agitated saline injection should be performed to determine whether there is an atrial level shunt.**
- **Post valve replacement, patients should be followed with serial echocardiograms according to institutional practice. If valves are abnormal by echocardiogram, consider the potential for clots requiring resumption of anticoagulants versus recurrent CHD.**

Repeat TTE Recommendations for Patients with NETs:	
Without known CHD	• Symptoms of dyspnea, fatigue, edema, or ascites • Physical exam findings including elevated jugular venous pressure, edema, or ascites • Prior to planned bowel/liver resection • Reassessment every 1–3 years
Known CHD with or without prior valve surgery	• Decision-making in conjunction with a multidisciplinary care team • Annual reassessment of all valves (native ± prosthetic) in conjunction with specialty cardiology consultation • New symptoms of dyspnea, fatigue, edema, or ascites • Change in physical exam including elevated jugular venous pressure, edema, or ascites • Prior to planned bowel/liver resection

References

Note: All recommendations are category 2A unless otherwise indicated.

Version 3.2025, 10/01/2025 © 2025 National Comprehensive Cancer Network® (NCCN®), All rights reserved. NCCN Guidelines® and this illustration may not be reproduced in any form without the express written permission of NCCN.

PLEASE NOTE that use of this NCCN Content is governed by the End-User License Agreement, and you MAY NOT distribute this Content or use it with any artificial intelligence model or tool.
Printed by Galya Basol Kochav on 1/7/2026 1:55:52 PM. Copyright © 2026 National Comprehensive Cancer Network, Inc. All Rights Reserved.

PRINCIPLES OF IMAGING
REFERENCES

[1] Hope TA, Allen-Auerbach M, Bodei L, et al. SNMMI procedure standard/EANM Practice Guideline for SSTR PET: Imaging neuroendocrine tumors. J Nucl Med 2023;64:204-210.
[2] Castillo JG, Naib T, Zacks JS, Adams DH. Echocardiography in functional midgut neuroendocrine tumors: When and how often. Rev Endocr Metab Disord 2017;18:411-421.
[3] Hofland J, Lamarca A, Steeds R, et al. Synoptic reporting of echocardiography in carcinoid heart disease (ENETS Carcinoid Heart Disease Task Force). J Neuroendocrinol 2022;34:e13060.

Note: All recommendations are category 2A unless otherwise indicated.

Version 3.2025, 10/01/2025 © 2025 National Comprehensive Cancer Network® (NCCN®), All rights reserved. NCCN Guidelines® and this illustration may not be reproduced in any form without the express written permission of NCCN.

PLEASE NOTE that use of this NCCN Content is governed by the End-User License Agreement, and you MAY NOT distribute this Content or use it with any artificial intelligence model or tool.
Printed by Galya Basol Kochav on 1/7/2026 1:55:52 PM. Copyright © 2026 National Comprehensive Cancer Network, Inc. All Rights Reserved.

PRINCIPLES OF BIOCHEMICAL TESTING[1-9]

- **Some NETs can secrete specific neuroendocrine hormones. Hormonal workup should be guided by the presence of symptoms of the excess hormone. Screening for hormones in individuals with asymptomatic disease is not routinely required.**
  - **Patients with functional tumors have clinical symptoms related to tumor-associated hormone excess.**
- **PPIs, other drugs, some medical conditions, and certain foods are known to cause false elevations in serum gastrin and chromogranin A. To confirm diagnosis, serum gastrin should ideally be checked when fasting and off PPI for >1 week. However, PPI should be continued in patients with overt clinical symptoms of gastrinoma and/or risks of complications.**
- **If MEN2 is suspected, patients should be evaluated for PCC/PGL prior to any procedures.[8]**

Syndrome	Location	Clinical Signs or Symptoms	Testing
Carcinoid syndrome (NETs of GI tract)	Primary tumors in small bowel and appendix; rarely in rectum	• Primary tumors in the GI tract usually are not associated with symptoms of hormone hypersecretion unless extensive metastasis. • Symptoms of hormone secretion may include flushing, diarrhea, cardiac valvular fibrosis, and bronchoconstriction	• 24-hour urine or plasma 5-HIAA ▸ Foods to avoid for 48 hours prior to and during testing: avocados, bananas, cantaloupe, eggplant, pineapples, plums, tomatoes, hickory nuts/pecans, plantains, kiwi, dates, grapefruit, honeydew, or walnuts
Carcinoid syndrome (NETs of lung and thymus)	Primary tumors in lung or thymus	• Lung/thymic tumors may be associated with classic carcinoid syndrome as well as hypercortisolemia (± Cushing syndrome)	• 24-hour urine or plasma 5-HIAA ▸ Foods to avoid for 48 hours prior to and during testing: avocados, bananas, cantaloupe, eggplant, pineapples, plums, tomatoes, hickory nuts/pecans, plantains, kiwi, dates, grapefruit, honeydew, or walnuts • Test for hypercortisolemia (± Cushing syndrome) (NE-E 2 of 4)
Insulinoma	Pancreas	Hypoglycemia	• Fasting blood glucose • While hypoglycemic: ▸ Serum insulin ▸ Pro-insulin ▸ C-peptide • See Evaluation for insulinoma (PanNET-5)
VIPoma	Most common in pancreas, rarely extra pancreatic	Severe watery diarrhea, hypokalemia	Serum VIP
Glucagonoma	Pancreas	Flushing, diarrhea, hyperglycemia, dermatitis, hypercoagulable state	Serum glucagon
Gastrinoma	Pancreas or duodenum	Gastric ulcers, duodenal ulcers, diarrhea	Serum gastrin[a]
Somatostatinoma	Pancreas or duodenum	Hyperglycemia, cholelithiasis, diarrhea/ steatorrhea	Serum somatostatin

Footnotes on NE-E 3 of 4
References

Note: All recommendations are category 2A unless otherwise indicated.

Version 3.2025, 10/01/2025 © 2025 National Comprehensive Cancer Network® (NCCN®), All rights reserved. NCCN Guidelines® and this illustration may not be reproduced in any form without the express written permission of NCCN.

PLEASE NOTE that use of this NCCN Content is governed by the End-User License Agreement, and you MAY NOT distribute this Content or use it with any artificial intelligence model or tool.
Printed by Galya Basol Kochav on 1/7/2026 1:55:52 PM. Copyright © 2026 National Comprehensive Cancer Network, Inc. All Rights Reserved.

PRINCIPLES OF BIOCHEMICAL TESTING[1-9]

Syndrome	Location	Clinical Signs or Symptoms	Testing
PCC/PGL	Adrenal or extra-adrenal sympathetic or parasympathetic chain	Hypertension, tachycardia, sweating, syncope	• Plasma free or 24-hour urine fractionated metanephrines[b] and normetanephrines • For cervical PGL, measuring serum and/or 24-hour urine fractionated catecholamines (for dopamine) or methoxytyramine (if available) may be appropriate.[b,c]
Pituitary tumor	Pituitary (part of MEN1)	May be asymptomatic, depends on the hormone secreted	• Serum IGF-1 (category 2B) • Serum prolactin • Luteinizing hormone (LH)/follicle-stimulating hormone (FSH), gonadotrophin with end organ hormone • Alpha subunits • Thyroid-stimulating hormone (TSH) and free T4 • Plasma adrenocorticotropic hormone (ACTH)/random cortisol • Total and free (or bioavailable) testosterone in those assigned male at birth • Estradiol in premenopausal patients who were assigned female at birth • Overnight dexamethasone suppression test • 24-hour urine for free cortisol when there is clinical evidence of Cushing syndrome
Hypercortisolemia[d] (± Cushing syndrome)	Adrenal, pituitary, or ectopic (often lung or thymic)	Cushing syndrome (central weight gain, striae, hypertension, hyperglycemia, depression, hirsutism)	• Screen for hypercortisolemia (± Cushing syndrome) with 1 of the following tests[e]: ▸ 1 mg overnight dexamethasone suppression test ▸ 2–3 midnight salivary cortisols ▸ 24-hour urinary free cortisol • Plasma ACTH in AM if confirmed hypercortisolemia (± Cushing syndrome) to determine if ACTH-dependent or ACTH-independent
Primary aldosteronism	Adrenal	Hypertension or hypokalemia	• Screening: Suppressed renin/renin activity in association with an elevated plasma aldosterone level (>10 ng/dL)[10] • Confirmatory testing if positive[f]
Suspected or confirmed ACC	Adrenal	Symptoms of hypercortisolemia (± Cushing syndrome) or primary aldosteronism (see above) Androgen excess symptoms	• Screen for hypercortisolemia (± Cushing syndrome) and primary aldosteronism • Adrenal androgens (dehydroepiandrosterone sulfate [DHEA-S], androstenedione, testosterone, 17-hydroxyprogesterone) • 24-hour urine for free cortisol when there is clinical evidence of Cushing syndrome

Note: All recommendations are category 2A unless otherwise indicated.

Footnotes on NE-E 3 of 4
References

Version 3.2025, 10/01/2025 © 2025 National Comprehensive Cancer Network® (NCCN®), All rights reserved. NCCN Guidelines® and this illustration may not be reproduced in any form without the express written permission of NCCN.

PLEASE NOTE that use of this NCCN Content is governed by the End-User License Agreement, and you MAY NOT distribute this Content or use it with any artificial intelligence model or tool.
Printed by Galya Basol Kochav on 1/7/2026 1:55:52 PM. Copyright © 2026 National Comprehensive Cancer Network, Inc. All Rights Reserved.

PRINCIPLES OF BIOCHEMICAL TESTING
FOOTNOTES

[a] Basal, stimulated as indicated.
[b] Some drugs may interfere with testing results, including: acetaminophen, labetalol, sotalol, α-methyldopa, tricyclic antidepressants, buspirone, phenoxybenzamine, monoamine oxidase inhibitors (MAOIs), sympathomimetics, cocaine, sulfasalazine, and levodopa.
[c] Methoxytyramine is helpful as the metabolite of dopamine in cervical tumors but it is not commercially available in many places.
[d] For additional information on biochemical testing for hypercortisolemia (± Cushing syndrome), refer to the Endocrine Society's Clinical Practice Guidelines for the Treatment of Cushing's Syndrome: Fleseriu M, Auchus R, Bancos I, et al. Consensus on diagnosis and management of Cushing's disease: a guideline update. Lancet Diabetes Endocrinol 2021;9:847-875.
[e] Petrosal vein sampling can be considered to differentiate adrenal from pituitary and ectopic causes. Petrosal sinus sampling only if ACTH-dependent hypercortisolemia (± Cushing syndrome).
[f] Oral or IV salt loading and measurement of urine or plasma aldosterone to test for adequate suppression.

Note: All recommendations are category 2A unless otherwise indicated.

Version 3.2025, 10/01/2025 © 2025 National Comprehensive Cancer Network® (NCCN®), All rights reserved. NCCN Guidelines® and this illustration may not be reproduced in any form without the express written permission of NCCN.

PLEASE NOTE that use of this NCCN Content is governed by the End-User License Agreement, and you MAY NOT distribute this Content or use it with any artificial intelligence model or tool.
Printed by Galya Basol Kochav on 1/7/2026 1:55:52 PM. Copyright © 2026 National Comprehensive Cancer Network, Inc. All Rights Reserved.

PRINCIPLES OF BIOCHEMICAL TESTING
REFERENCES

[1] Kaltsas G, Androulakis II, de Herder WW, Grossman AB. Paraneoplastic syndromes secondary to neuroendocrine tumours. Endocr Relat Cancer 2010;17:R173-193.
[2] Oberg K. Diagnostic work-up of gastroenteropancreatic neuroendocrine tumors. Clinics (Sao Paulo) 2012;67 Suppl 1:109-112.
[3] Van Der Horst-Schrivers AN, Osinga TE, Kema IP, et al. Dopamine excess in patients with head and neck paragangliomas. Anticancer Res 2010;30:5153-5158.
[4] Raines D, Chester M, Diebold AE, et al. A prospective evaluation of the effect of chronic proton pump inhibitor use on plasma biomarker levels in humans. Pancreas 2012;41:508-511.
[5] Cryer PE, Axelrod L, Grossman AB, et al. Evaluation and management of adult hypoglycemic disorders: an Endocrine Society Clinical Practice Guideline. J Clin Endocrinol Metab 2009;94:709-728.
[6] Fleseriu M, Auchus R, Bancos I, et al. Consensus on diagnosis and management of Cushing's disease: a guideline update. Lancet Diabetes Endocrinol 2021;9:847-875.
[7] Funder JW, Carey RM, Mantero F, et al. Case detection, diagnosis, and treatment of patients with primary aldosteronism: an endocrine society clinical practice guideline. J Clin Endocrinol Metab 2016;101:1889-1916.
[8] Thakker RV, Newey PJ, Walls GV, et al. Clinical practice guidelines for multiple endocrine neoplasia type 1 (MEN1). J Clin Endocrinol Metab 2012;97:2990-3011.
[9] Modlin IM, Oberg K, Taylor A, et al. Neuroendocrine tumor biomarkers: current status and perspectives. Neuroendocrinology 2014;100:265-277.
[10] Young WF Jr. Diagnosis and treatment of primary aldosteronism: practical clinical perspectives. J Intern Med 2019;285:126-148.

Note: All recommendations are category 2A unless otherwise indicated.

Version 3.2025, 10/01/2025 © 2025 National Comprehensive Cancer Network® (NCCN®), All rights reserved. NCCN Guidelines® and this illustration may not be reproduced in any form without the express written permission of NCCN.

PLEASE NOTE that use of this NCCN Content is governed by the End-User License Agreement, and you MAY NOT distribute this Content or use it with any artificial intelligence model or tool.
Printed by Galya Basol Kochav on 1/7/2026 1:55:52 PM. Copyright © 2026 National Comprehensive Cancer Network, Inc. All Rights Reserved.

PRINCIPLES OF SURGICAL MANAGEMENT OF NEUROENDOCRINE TUMORS

- **Standard oncologic surgery (eg, distal pancreatectomy/splenectomy or pancreatoduodenectomy) is appropriate for most resectable, non-metastatic PanNETs. However, there are additional considerations for the following circumstances:**
  - **Tumor enucleation should be considered primarily for insulinomas, which are highly symptomatic (hypoglycemic) but rarely malignant. Peripheral insulinomas should be considered for enucleation/local resection or spleen-preserving distal pancreatectomy, when technically feasible.**
  - **For patients with small (<2 cm) low-grade PanNETs, decisions on surgery versus active surveillance need to be individualized, based on tumor size/characteristics and patient characteristics:**
    - **Tumors <1 cm have a lower malignant potential than tumors measuring 1–2 cm.**
    - **Other radiographic characteristics of small tumors (homogeneous, well-circumscribed) may also correlate with benign behavior.**
    - **Patient characteristics such as age and comorbidities are important when determining whether surveillance is appropriate.**
    - **Black patients with 1–2 cm low-grade PanNETs may have similar risk for lymph node metastases as white patients with >2 cm tumors.[1]**
    - **Calcification is associated with higher tumor grade and increased rate of lymph node metastasis.[2]**
- **Surgical resection of lung tumors is recommended for localized and resectable locoregional disease. There are no randomized data regarding extent of surgical resection but retrospective analyses suggest that if the tumor can be resected completely, a sublobar resection may yield outcomes similar to a lobectomy even for atypical carcinoids.[3]**
- **Resection for larger (>2 cm) or malignant-appearing non-functional and functional PanNETs (ie, glucagonoma, VIPoma, somatostatinoma) should include total removal of the tumor with negative margins (including adjacent organs) and regional lymph nodes. Tumors of the head are generally treated with pancreatoduodenectomy (Whipple procedure); tumors of the body and tail are treated with distal pancreatectomy and splenectomy or spleen-preserving distal pancreatectomy. Generally surgery will include splenectomy, but with benign insulinoma, spleen preservation should be considered.**
  - **Assess implications of pancreatoduodenectomy (Whipple procedure) in metastatic disease. In this setting, such surgery is usually not curative and impacts liver-directed therapy long-term.**
- **Resection of GI NETs should include adequate regional lymph node resection (including all palpable disease where feasible). This is especially important for small bowel NETs were manual palpation of the entire length of bowel is recommended as the rate of synchronous primary tumors is high (15%–30% incidence). Resection of palpated lesions can be performed using a hybrid minimally invasive approach, if feasible.**
- **Resection of recurrent locoregional disease, isolated distant metastases, or a previously unresectable tumor that has regressed should be considered for selected patients with adequate performance status.**
- **In the setting of metastatic disease, resection of ileum/jejunum NETs (primary tumors and mesenteric lymph nodes) should be performed when symptoms arise from the primary tumor. In asymptomatic cases, resection should be considered to reduce future obstruction, mesenteric ischemia, bleeding, or perforation.**

References

Note: All recommendations are category 2A unless otherwise indicated.

Version 3.2025, 10/01/2025 © 2025 National Comprehensive Cancer Network® (NCCN®), All rights reserved. NCCN Guidelines® and this illustration may not be reproduced in any form without the express written permission of NCCN.

PLEASE NOTE that use of this NCCN Content is governed by the End-User License Agreement, and you MAY NOT distribute this Content or use it with any artificial intelligence model or tool.
Printed by Galya Basol Kochav on 1/7/2026 1:55:52 PM. Copyright © 2026 National Comprehensive Cancer Network, Inc. All Rights Reserved.

PRINCIPLES OF SURGICAL MANAGEMENT OF NEUROENDOCRINE TUMORS

- **Cytoreductive surgery of >90% of metastatic disease may provide symptomatic relief, prevent future symptoms, and improve progression-free survival for patients with functioning tumors. This strategy is particularly appropriate for patients with relatively indolent metastatic small bowel NETs, and less appropriate for patients in whom rapid progression of disease is expected after surgery. Patients who are symptomatic from hormonal syndromes, such as carcinoid syndrome, typically derive palliation from cytoreductive surgery.**
  - **Parenchymal sparing surgery, including enucleation of liver metastases ± ablation, is preferred to preserve as much liver parenchyma as possible.**
- **Cholecystectomy is recommended when performing surgery for advanced NETs in patients anticipated to receive long-term somatostatin analogs (SSAs), as these patients are at higher risk of developing biliary symptoms and cholecystitis.**
- **Liver-directed therapies (eg, liver resection, thermal ablation, chemoembolization) for hepatic metastases from NETs following pancreatoduodenectomy are associated with increased risk for cholangitis and liver abscess.**
- **In cases of significant CHD, valve replacement should be done prior to liver resection if at all possible.**
- **Octreotide therapy should be considered parenterally prior to induction of anesthesia in patients with carcinoid syndrome to prevent carcinoid crisis.[4]**
- **All patients who undergo a splenectomy should receive vaccination against encapsulated bacterium (ie, pneumococcus, haemophilus influenzae b, meningococcal group C). These vaccinations should be administered at least 14 days before elective splenectomy, if possible. If the vaccinations are not administered before surgery, they should be administered after the procedure as soon as the patient's condition is stable.**
- **For MEN1-related surgical principles, see MEN1-A.**
- **For MEN2-associated PCCs, subtotal adrenalectomy may be an option for select patients.**

References

Note: All recommendations are category 2A unless otherwise indicated.

Version 3.2025, 10/01/2025 © 2025 National Comprehensive Cancer Network® (NCCN®), All rights reserved. NCCN Guidelines® and this illustration may not be reproduced in any form without the express written permission of NCCN.

PLEASE NOTE that use of this NCCN Content is governed by the End-User License Agreement, and you MAY NOT distribute this Content or use it with any artificial intelligence model or tool.
Printed by Galya Basol Kochav on 1/7/2026 1:55:52 PM. Copyright © 2026 National Comprehensive Cancer Network, Inc. All Rights Reserved.

PRINCIPLES OF SURGICAL MANAGEMENT OF NEUROENDOCRINE TUMORS
REFERENCES

[1] Zheng-Pywell R, Lopez-Aguiar A, Fields RC, et al. Are we undertreating black patients with nonfunctional pancreatic neuroendocrine tumors? Critical analysis of current surveillance guidelines by race. J Am Coll Surg 2022;234:599-606.
[2] Makris EA, Cannon JGD, Norton JA, et al. Calcifications and cystic morphology on preoperative imaging predict survival after resection of pancreatic neuroendocrine tumors. Ann Surg Oncol 2023;30:2424-2430.
[3] Ernani V, Appiah AK, Rodriguez D, et al. Lobar versus sublobar resection for atypical lung carcinoid: An analysis from the National Cancer Database. Cancer 2023;129:860-866.
[4] Maxwell JE, Naraev B, Halperin DM, Choti MA, Halfdanarson TR. Shifting paradigms in the pathophysiology and treatment of carcinoid crisis. Ann Surg Oncol 2022;29:3072-3084.

Note: All recommendations are category 2A unless otherwise indicated.

Version 3.2025, 10/01/2025 © 2025 National Comprehensive Cancer Network® (NCCN®), All rights reserved. NCCN Guidelines® and this illustration may not be reproduced in any form without the express written permission of NCCN.

PLEASE NOTE that use of this NCCN Content is governed by the End-User License Agreement, and you MAY NOT distribute this Content or use it with any artificial intelligence model or tool.
Printed by Galya Basol Kochav on 1/7/2026 1:55:52 PM. Copyright © 2026 National Comprehensive Cancer Network, Inc. All Rights Reserved.

PRINCIPLES OF HEREDITARY CANCER RISK ASSESSMENT AND GENETIC COUNSELING

- **The decision to offer genetic testing involves three related stages:**
  1) Pre-test counseling prior to ordering testing;
  2) Consideration of the most appropriate testing strategy; and
  3) Testing result disclosure and post-test counseling.
- **It is recommended that a genetic counselor, medical geneticist, endocrinologist, oncologist, surgeon, oncology nurse, or other health professional with expertise and experience in cancer genetics be involved at each stage whenever possible. Clinicians without direct referral access to the appropriate expertise should be aware of the telehealth genetic counseling options available. These resources can be found through the National Society of Genetic Counselors "Find a Genetic Counselor" tool (www.nsgc.org).**

1) Pre-Test Counseling:

- **Pre-test counseling includes the following elements:**
  - **Evaluation of patient's knowledge, needs/concerns, and goals for familial risk assessment.**
  - **Detailed family history (including cancers/tumors and age at diagnosis, as well as clinical symptoms that can indicate an underlying endocrine neoplasia) in first-, second-, and third-degree family members on each side of the family.**
  - **Detailed past medical history and review of systems, including:**
    - **Documentation of prior genetic testing results for patients and their family members; and**
    - **Personal cancer/tumor history including age of diagnosis and treatment.**
  - **Focused physical examination (conducted by qualified clinician) when indicated.**
  - **Generation of differential diagnosis and educating the patient on inheritance pattern, penetrance, variable expressivity, and the possibility of genetic heterogeneity.**
  - **Discussion of possible genetic testing result outcomes, including positive (pathogenic or likely pathogenic), negative, and variants of uncertain significance (VUS).**
  - **Discussion of the clinical implications of testing results to the patient.**
  - **Discussion of the clinical implications of testing results to potentially affected family members and their available options for pursuing risk assessment, testing, and management.**
  - **Cost of genetic testing.**
  - **Current legislation regarding genetic discrimination and the privacy of genetic information.**

See NCCN Guidelines for Genetic/Familial High-Risk Assessment: Breast, Ovarian, and Pancreatic (EVAL-A, EVAL-B)

Note: All recommendations are category 2A unless otherwise indicated.

Version 3.2025, 10/01/2025 © 2025 National Comprehensive Cancer Network® (NCCN®), All rights reserved. NCCN Guidelines® and this illustration may not be reproduced in any form without the express written permission of NCCN.

PLEASE NOTE that use of this NCCN Content is governed by the End-User License Agreement, and you MAY NOT distribute this Content or use it with any artificial intelligence model or tool.
Printed by Galya Basol Kochav on 1/7/2026 1:55:52 PM. Copyright © 2026 National Comprehensive Cancer Network, Inc. All Rights Reserved.

PRINCIPLES OF HEREDITARY CANCER RISK ASSESSMENT AND GENETIC COUNSELING

2) Considerations When Determining the Most Appropriate Testing Strategy:

- The introduction of multigene testing for hereditary endocrine neoplasia syndromes has rapidly altered the clinical approach to genetic testing of patients.
- Given the possible overlap in clinical presentation amongst hereditary endocrine neoplasias, multigene panel testing may be more efficient and cost-effective in many situations.
- As commercially available tests differ in the specific genes analyzed, variant classification, and other factors (eg, methods of DNA/RNA analysis or option to reflex from a narrow to a larger panel; provision of financial assistance for cascade testing of relatives), it is important to consider the indication for testing and the expertise of the laboratory when choosing the specific laboratory and test panel.
- The interpretation of genetic testing remains subjective and complex. The interpretations can differ based on interlaboratory classification rules, access to unique case-level data, and other evidence. Additionally, variants may need to be reconsidered and reclassified as additional data emerge in the field.
- Genetic testing performed to identify somatic mutations arising in malignant cells is often not designed to detect germline variants and may thus be inadequate for evaluation of an underlying hereditary endocrine neoplasia syndrome.
- Testing for unaffected family members when no affected member is available should be considered. Significant limitations of interpreting test results should be discussed.

3) Post-Test Counseling Includes the Following Elements:

- Discussion of results and implications for patient and/or family members.
- Interpretation of results in context of personal and family history.
- Likely pathogenic variants are usually clinically managed similarly to pathogenic variants, while patients with VUS and likely benign variants should be managed based on the cancers/tumors in the family.
- For patients with positive results:
  - Discussion of recommended medical management.
  - Discussion of the importance of notifying family members and offering materials/resources for information and testing of family members.
  - For many hereditary endocrine neoplasia syndromes, testing of children is indicated since screening interventions often start in childhood or adolescence.
  - Discussion of available resources such as high-risk clinics, disease-specific support groups, and research studies.
  - For patients of reproductive age, advise about options for prenatal diagnosis and assisted reproduction, including pre-implantation genetic diagnosis.
  - Consider carrier status implications of certain autosomal recessive disorders.
- For patients with negative results:
  - Discussion of possible etiologies for their personal/family history including sporadic, multifactorial, or unidentified hereditary factors.
  - For patients with a clinical diagnosis of an endocrine neoplasia condition (such as MEN1) and negative genetic testing, consider following the related surveillance recommendations for patient and first-degree family members.

Note: All recommendations are category 2A unless otherwise indicated.

Version 3.2025, 10/01/2025 © 2025 National Comprehensive Cancer Network® (NCCN®), All rights reserved. NCCN Guidelines® and this illustration may not be reproduced in any form without the express written permission of NCCN.

PLEASE NOTE that use of this NCCN Content is governed by the End-User License Agreement, and you MAY NOT distribute this Content or use it with any artificial intelligence model or tool.
Printed by Galya Basol Kochav on 1/7/2026 1:55:52 PM. Copyright © 2026 National Comprehensive Cancer Network, Inc. All Rights Reserved.

PRINCIPLES OF HEREDITARY CANCER RISK ASSESSMENT AND GENETIC COUNSELING

4) Recommend Genetic Risk Evaluation and Genetic Testing for Hereditary Endocrine Neoplasia Syndromes for Patients Meeting Any of the Following Criteria:

- **ACC. See Hereditary Cancer Predisposition Syndromes Associated with Adrenocortical Carcinoma (NE-G 6 of 8).**
- **PCC/PGL**
- **Parathyroid adenoma or primary hyperparathyroidism before age 30, multiple parathyroid adenomas, multigland hyperplasia (without obvious secondary causes), or recurrent primary hyperparathyroidism**
- **Clinical suspicion for MEN1 due to ≥2 of the following, or 1 AND a family history of ≥1 of the following:**
  - **Primary hyperparathyroidism**
  - **Duodenal NET/PanNET**
  - **Pituitary adenoma**
  - **Foregut carcinoid (lung, thymic, or gastric)**
- **Clinical suspicion for MEN2 due to the presence of medullary thyroid carcinoma or other combination of MEN2-related features**
- **A mutation identified on tumor genomic testing that has clinical implications if also identified in the germline (eg, tumor analysis shows mutation in *BRCA1/2* or MMR gene)**
- **Close blood relative with a known pathogenic variant/likely pathogenic variant in a cancer susceptibility gene**
- **A first-degree relative meeting one of the above criteria but not available for testing**

5) Consider Genetic Risk Evaluation and Genetic Testing for Patients Meeting Any of the Following Criteria:

- **Gastrinoma (duodenal/pancreatic or type 2 gNET)**
- **Multifocal PanNETs**
- **Duodenal NET/PanNET at any age[a]**
- **Other combinations of tumors or cancers in the patient and/or their family members**

Endocrine neoplasia manifestations or medical conditions associated with specific hereditary syndromes and clinical manifestations are outlined in this table: Tumor Associations of Hereditary Endocrine Neoplasia Syndromes (NE-G 4 of 8).

[a] Studies of unselected patients with PanNETs have identified germline variants in 16%–17% of cases. However, these studies involved relatively small cohorts of patients. Raj N, Shah R, Stadler Z, et al. Real-time genomic characterization of metastatic pancreatic neuroendocrine tumors has prognostic implications and identifies potential germline actionability. JCO Precis Oncol 2018;2018:PO.17.00267. Scarpa A, Chang DK, Nones K, et al. Whole-genome landscape of pancreatic neuroendocrine tumours. Nature 2017;543:65-71.

Note: All recommendations are category 2A unless otherwise indicated.

Version 3.2025, 10/01/2025 © 2025 National Comprehensive Cancer Network® (NCCN®), All rights reserved. NCCN Guidelines® and this illustration may not be reproduced in any form without the express written permission of NCCN.

PLEASE NOTE that use of this NCCN Content is governed by the End-User License Agreement, and you MAY NOT distribute this Content or use it with any artificial intelligence model or tool.
Printed by Galya Basol Kochav on 1/7/2026 1:55:52 PM. Copyright © 2026 National Comprehensive Cancer Network, Inc. All Rights Reserved.

PRINCIPLES OF HEREDITARY CANCER RISK ASSESSMENT AND GENETIC COUNSELING

Tumor Associations of Hereditary Endocrine Neoplasia Syndromes[b]

Syndrome (Gene)[c]	Endocrine Neoplasia Manifestations	Other Manifestations	Surveillance
Hereditary PCC/PGL syndrome (*MAX*, *SDHA*, *SDHAF2*, *SDHB*, *SDHC*, *SDHD*, or *TMEM127*)	PCC[c] PGL[c]	GI stromal tumor (GIST) (*SDHx*) Renal cell cancer (*SDHx*)	NE-G (7 of 8) NCCN Guidelines for Kidney Cancer
Multiple endocrine neoplasia type 1 (*MEN1*)[1]	Parathyroid adenoma/hyperplasia (>95%) PanNETs (functioning) or duodenal NETs (20%–80%) ▸ Gastrinoma (20%–61%) ▸ Insulinoma (7%–31%) ▸ Glucagonoma (1%–5%) ▸ VIPoma/somatostatinoma (<2%) Pituitary adenomas (30%–40%) Gastric carcinoids (7%–35%) Lung/thymic carcinoids (<8%) Adrenal adenomas (27%–36%)	Angiofibromas Collagenomas Lipomas Meningiomas	MEN1-2[1] and MEN1-A[1]
Multiple endocrine neoplasia type 2 (*RET*)	Medullary thyroid carcinoma (≤98%) PCC (≤50%) Parathyroid adenoma/hyperplasia (≤25% MEN2A, rare in MEN2B)	MEN2A*:* • Cutaneous lichens amyloidosis • Hirschsprung disease MEN2B*:* • Intestinal ganglioneuromas • Mucosal neuromas • Marfanoid habitus	MEN2-1 and NE-G (7 of 8)[2] NCCN Guidelines for Thyroid Carcinoma

Note: This resource is not intended to be an exhaustive list of hereditary endocrine neoplasias. Specific scenarios may warrant consideration of less common conditions such as Carney complex, Carney triad, Currarino syndrome, or polycythemia-paraganglioma-somatostatinoma syndrome.

[b] Many of these may be associated with non-neuroendocrine conditions. Evaluation by comprehensive multidisciplinary team should be considered.
[c] Penetrance estimates and tumor locations vary significantly by gene. For patients with pathogenic variants in the *SDHD, SDAHF2*, and possibly *MAX* genes, tumor risks are mostly a concern when the variant is paternally inherited.

Note: All recommendations are category 2A unless otherwise indicated.

References

Version 3.2025, 10/01/2025 © 2025 National Comprehensive Cancer Network® (NCCN®), All rights reserved. NCCN Guidelines® and this illustration may not be reproduced in any form without the express written permission of NCCN.

PLEASE NOTE that use of this NCCN Content is governed by the End-User License Agreement, and you MAY NOT distribute this Content or use it with any artificial intelligence model or tool.
Printed by Galya Basol Kochav on 1/7/2026 1:55:52 PM. Copyright © 2026 National Comprehensive Cancer Network, Inc. All Rights Reserved.

PRINCIPLES OF HEREDITARY CANCER RISK ASSESSMENT AND GENETIC COUNSELING

Tumor Associations of Hereditary Endocrine Neoplasia Syndromes[b]

Syndrome (Gene)	Endocrine Neoplasia Manifestations	Other Manifestations	Surveillance
Multiple endocrine neoplasia type 4 *(CDKN1B)* [d]	Parathyroid adenoma/hyperplasia Pituitary adenomas PanNETs or duodenal NETs Papillary thyroid carcinoma	Meningiomas	Not available[1]
Neurofibromatosis type 1 *(NF1)*	PCC (3%) PanNETs (rare)	Neurofibromas Skin lesions (café-au-lait and freckling) Lisch nodules Gliomas GIST	NCCN Guidelines for Genetic/Familial High-Risk Assessment: Breast, Ovarian, Pancreatic, and Prostate AAP Health Supervision Guidelines[3]
Tuberous sclerosis complex *(TSC1 and TSC2)*	Pituitary adenomas (rare) Parathyroid adenoma/hyperplasia (rare) PanNETs (rare)	Skin lesions Central nervous system tumors/cancers Renal angiomyolipomas Clear cell renal cancer Cardiac rhabdomyomas Lymphangioleiomyomatosis	NCCN Guidelines for Kidney Cancer
von Hippel-Lindau (VHL) syndrome	PCC (10%–20%) PGL (10%–20%) PanNETs (5%–17%)	Hemangioblastomas (retinal or central nervous system) Clear cell renal cancer Endolymphatic sac tumors Cystadenomas	NE-G (7 of 8) and PanNET-11 VHLA Handbook[4] NCCN Guidelines for Kidney Cancer

Note: This resource is not intended to be an exhaustive list of hereditary endocrine neoplasias. Specific scenarios may warrant consideration of less common conditions such as Carney complex, Carney triad, Currarino syndrome, or polycythemia-paraganglioma-somatostatinoma syndrome.

[b] Many of these may be associated with non-neuroendocrine conditions. Evaluation by comprehensive multidisciplinary team should be considered.
[d] MEN4 is a newly described endocrine neoplasia. Therefore, penetrance estimates and surveillance guidelines are not available. Given the clinical overlap with MEN1, consideration can be given to following MEN1-related surveillance recommendations in patients with MEN4.

Note: All recommendations are category 2A unless otherwise indicated.

References

Version 3.2025, 10/01/2025 © 2025 National Comprehensive Cancer Network® (NCCN®), All rights reserved. NCCN Guidelines® and this illustration may not be reproduced in any form without the express written permission of NCCN.

PLEASE NOTE that use of this NCCN Content is governed by the End-User License Agreement, and you MAY NOT distribute this Content or use it with any artificial intelligence model or tool.
Printed by Galya Basol Kochav on 1/7/2026 1:55:52 PM. Copyright © 2026 National Comprehensive Cancer Network, Inc. All Rights Reserved.

PRINCIPLES OF HEREDITARY CANCER RISK ASSESSMENT AND GENETIC COUNSELING

Hereditary Cancer Predisposition Syndromes Associated with Adrenocortical Carcinoma[b]

Syndrome (Gene)	Other Cancer/Tumor Associations	Surveillance Recommendations
Li-Fraumeni syndrome (*TP53*)	Sarcoma, brain cancer, breast cancer, leukemia	NCCN Guidelines for Genetic/Familial High-Risk Assessment: Breast, Ovarian, Pancreatic, and Prostate
Lynch syndrome (*MLH1, EPCAM/MSH2, MSH6, PMS2*)	Colon, endometrial, gastric, ovarian, and other cancers	NCCN Guidelines for Genetic/Familial High-Risk Assessment: Breast, Ovarian, Pancreatic, and Prostate NCCN Guidelines for Genetic/Familial High-Risk Assessment: Colorectal, Endometrial, and Gastric
Multiple endocrine neoplasia type 1 (*MEN1*)	Parathyroid adenoma/hyperplasia, duodenal/PanNETs, pituitary adenomas, lung/thymic carcinoids	MEN1-2 and MEN1-A
Familial adenomatous polyposis (*APC*)	Colon polyposis/cancer, duodenal/periampullary polyposis/cancer, thyroid carcinoma	NCCN Guidelines for Genetic/Familial High-Risk Assessment: Colorectal, Endometrial, and Gastric

[b] Many of these may be associated with non-neuroendocrine conditions. Evaluation by comprehensive multidisciplinary team should be considered.

Note: All recommendations are category 2A unless otherwise indicated.

Version 3.2025, 10/01/2025 © 2025 National Comprehensive Cancer Network® (NCCN®), All rights reserved. NCCN Guidelines® and this illustration may not be reproduced in any form without the express written permission of NCCN.

PLEASE NOTE that use of this NCCN Content is governed by the End-User License Agreement, and you MAY NOT distribute this Content or use it with any artificial intelligence model or tool.
Printed by Galya Basol Kochav on 1/7/2026 1:55:52 PM. Copyright © 2026 National Comprehensive Cancer Network, Inc. All Rights Reserved.

PRINCIPLES OF HEREDITARY CANCER RISK ASSESSMENT AND GENETIC COUNSELING

PCC/PGL-Specific Screening Recommendations for Patients with Confirmed Germline Hereditary Syndromes[5-8]

Hereditary PCC/PGL syndrome[e,9]

- **Surveillance starting at 6–10 years for patients with *SDHB* mutations and 10–15 years for patients with all other forms of hereditary PCC/PGL. If asymptomatic and without a prior history of elevation, annual follow-up and testing can be omitted or done with imaging every 2–3 years.**
  - **Blood pressure monitoring at all medical visits.**
  - **Annual measurement of plasma free metanephrines or 24-hour urine for fractionated metanephrines.**
  - **Cross-sectional imaging of skull base to pelvis every 2–3 years. Whole body MRI (if available) or other non-radiation–containing imaging procedures. If whole body MRI not available, may consider abdomen MRI, skull base and neck MRI, and chest CT.[f,g,10,11]**
  - **Since *SDH* genes have variability in their tumor penetrance and risk for malignancy, consideration can be given to modified screening intervals, especially for less penetrant genes such as *SDHA*.**

Multiple endocrine neoplasia type 2[2]

- **Surveillance starting by age 11 years for children in the American Thyroid Association high risk (ATA-H) and highest risk (ATA-HST) categories and by age 16 years in children in the ATA moderate risk (ATA-MOD) category:**
  - **Annual measurement of plasma free metanephrines or 24-hour urine for fractionated metanephrines.**
  - **Adrenal imaging with CT or MRI is indicated in patients with positive biochemical results.**

von Hippel-Lindau syndrome

- **Blood pressure monitoring at all medical visits starting at age 2 years.**
- **Annual measurement of plasma free metanephrines (preferred) or 24-hour urine for fractionated metanephrines starting at age 5 years.**
- **Abdomen MRI (preferred) or CT with and without intravenous (IV) contrast every 2–3 years starting at age 15 years.**

Surgical Recommendations for Patients with Suspected or Confirmed PCC/PGL Syndromes

- **Preoperative alert: Patients with a suspected or confirmed diagnosis of a hereditary PCC/PGL syndrome should have blood and/or urine screening for tumors prior to any surgical procedures.**
- **Patients with hereditary PCC/PGL, MEN2, and VHL have an appreciable risk for bilateral tumors. Consideration should be given to cortical-sparing adrenalectomy.**

[e] Patients with *SDHD, SDHAF2*, and *MAX* mutations are most at risk if the pathogenic variant was paternally inherited. Recommend following the above recommendations if the parent of origin is unknown. Consider screening for patients with maternally inherited variants as case reports of tumor occurrence exist.
[f] Optimal interval for imaging surveillance is not known and much of the data are based on expert opinion.
[g] Available data suggest that patients with *SDHAF2* mutations are primarily at risk for head and neck tumors and patients with *MAX* mutations are primarily at risk for adrenal tumors. Therefore, consideration can be given to more targeted imaging in these cohorts.

References

Note: All recommendations are category 2A unless otherwise indicated.

Version 3.2025, 10/01/2025 © 2025 National Comprehensive Cancer Network® (NCCN®), All rights reserved. NCCN Guidelines® and this illustration may not be reproduced in any form without the express written permission of NCCN.

PLEASE NOTE that use of this NCCN Content is governed by the End-User License Agreement, and you MAY NOT distribute this Content or use it with any artificial intelligence model or tool.
Printed by Galya Basol Kochav on 1/7/2026 1:55:52 PM. Copyright © 2026 National Comprehensive Cancer Network, Inc. All Rights Reserved.

PRINCIPLES OF HEREDITARY CANCER RISK ASSESSMENT AND GENETIC COUNSELING
REFERENCES

[1] Thakker RV, Newey PJ, Walls GV, et al. Clinical practice guidelines for multiple endocrine neoplasia type 1 (MEN1). J Clin Endocrinol Metab 2012;97:2990-3011.
[2] Wells SA Jr, Asa SL, Dralle H, et al. Revised American Thyroid Association guidelines for the management of medullary thyroid carcinoma. Thyroid 2015;25:567-610.
[3] Miller DT, Freedenberg D, Schorry E, et al. Health supervision for children with neurofibromatosis Type 1. Pediatrics 2019;143:e20190660.
[4] The VHL Alliance. The VHL Handbook: What you need to know about VHL. 6th ed. 2020.
[5] Rednam SP, Erez A, Druker H, et al. Von Hippel-Lindau and hereditary pheochromocytoma/paraganglioma syndromes: Clinical features, genetics, and surveillance recommendations in childhood. Clin Cancer Res 2017;23:e68-e75.
[6] Muth A, Crona J, Gimm O, et al. Genetic testing and surveillance guidelines in hereditary pheochromocytoma and paraganglioma. J Intern Med 2019;285:187-204.
[7] Tufton N, Sahdev A, Akker SA. Radiological surveillance screening in asymptomatic succinate dehydrogenase mutation carriers. J Endocr Soc 2017;1:897-907.
[8] Neumann HPH, Young WF Jr, Eng C. Pheochromocytoma and paraganglioma. N Engl J Med 2019;381:552-565.
[9] Amar L, Pacak K, Steichen O, et al. International consensus on initial screening and follow-up of asymptomatic *SDHx* mutation carriers. Nat Rev Endocrinol 2021;17:435-444.
[10] Hanson H, Durkie M, Lalloo F, et al. UK recommendations for *SDHA* germline genetic testing and surveillance in clinical practice. J Med Genet 2023;60:107-111.
[11] Wong MY, Andrews KA, Challis BG, et al. Clinical Practice Guidance: Surveillance for phaeochromocytoma and paraganglioma in pediatric succinate dehydrogenase gene mutation carriers. Clin Endocrinol (Oxf) 2019;90:499-505.

Note: All recommendations are category 2A unless otherwise indicated.

Version 3.2025, 10/01/2025 © 2025 National Comprehensive Cancer Network® (NCCN®), All rights reserved. NCCN Guidelines® and this illustration may not be reproduced in any form without the express written permission of NCCN.

PLEASE NOTE that use of this NCCN Content is governed by the End-User License Agreement, and you MAY NOT distribute this Content or use it with any artificial intelligence model or tool.
Printed by Galya Basol Kochav on 1/7/2026 1:55:52 PM. Copyright © 2026 National Comprehensive Cancer Network, Inc. All Rights Reserved.

PRINCIPLES OF SYSTEMIC ANTI-TUMOR THERAPY
Locoregional Advanced and/or Distant Metastatic Neuroendocrine Tumors of the Gastrointestinal Tract (Well-Differentiated Grade 1/2)

- **Systemic therapy may not be appropriate for every patient with locoregional advanced and/or distant metastatic disease. Consider multidisciplinary discussion to determine the best choice of treatment, including: observation for patients with stable disease with mild tumor burden, locoregional therapy, cytoreductive surgery, or systemic therapy, which may be appropriate considerations.**
- **Currently, there are no data to support a specific sequence of regional versus systemic therapy, and no data to guide sequencing of the following systemic therapy options.**
- **There is no known role for systemic treatment in the adjuvant setting for NETs.**
- **Doses and schedules are subject to appropriate modifications depending on the circumstances.**
- **For management of hormone-related symptoms for GI tumors, see NET-9. For management of carcinoid syndrome, see NET-14.**

Neuroendocrine Tumors of the Gastrointestinal Tract (Well-Differentiated Grade 1/2)[a]			
	Preferred Regimens	**Other Recommended Regimens**	**Useful in Certain Circumstances**
Locoregional Advanced Disease and/or Distant Metastases	• Cabozantinib (category 1 if prior treatment with everolimus or lutetium Lu 177 dotatate)[1] • Everolimus (category 1 for nonfunctional tumors)[b,c,2,3] • PRRT with lutetium Lu 177 dotatate (if SSTR-positive and progression on octreotide LAR/lanreotide) (category 1 for progressive mid-gut tumors) (NE-J) • First-line PRRT with lutetium Lu 177 dotatate (if SSTR-positive, Ki-67 ≥10%, and clinically significant tumor burden)[4] • Octreotide LAR[d-g,5,6] or lanreotide[d-g,7,8]	• None	• If progression on standard SSA doses, above-label dose octreotide LAR[h] or lanreotide[h] (if SSTR-positive) • Consider RT ± concurrent fluoropyrimidine-based chemotherapy for locally advanced unresectable disease (excluding small bowel mesenteric) (NE-I) • Consider (listed in alphabetical order): ▸ Cytotoxic chemotherapy, if no other options feasible (all category 3): Anticancer agents such as 5-fluorouracil (5-FU), capecitabine, dacarbazine, oxaliplatin, and temozolomide can be used in patients with progressive disease. (See Discussion for details.)

[a] If clinically significant disease progression, treatment with octreotide LAR or lanreotide should be discontinued for non-functional tumors and continued in patients with functional tumors; these regimens may be used in combination with any of the subsequent options. For details on the administration of octreotide LAR or lanreotide with lutetium Lu 177 dotatate, see NE-J.
[b] Effectiveness of everolimus in the treatment of patients with carcinoid syndrome has not been established.
[c] Phase III study done in nonfunctional tumors.
[d] Treatment with octreotide LAR or lanreotide will likely be of greatest benefit in patients with SSTR-positive tumors.
[e] For symptom and/or tumor control, octreotide LAR 20–30 mg IM or lanreotide 120 mg SC every 4 weeks. Higher doses have been shown to be safe. For breakthrough symptoms, octreotide 100–250 mcg SC TID can be considered.
[f] The PROMID trial showed an antitumor effect of octreotide LAR in advanced NETs of the midgut.[5] The CLARINET trial showed an antitumor effect of lanreotide in advanced, well-differentiated metastatic grade 1 and grade 2 GEP NETs.[6]
[g] If injection site-related complications occur, consider switching to another SSA.
[h] After clinical, symptomatic, or radiographic progression on standard SSA doses, for symptom and/or tumor control, above-label dosing octreotide LAR (up to 60 mg once a month) or lanreotide (up to 120 mg every 14 days) may be useful in select cases.

Note: All recommendations are category 2A unless otherwise indicated.

References

Version 3.2025, 10/01/2025 © 2025 National Comprehensive Cancer Network® (NCCN®), All rights reserved. NCCN Guidelines® and this illustration may not be reproduced in any form without the express written permission of NCCN.

PLEASE NOTE that use of this NCCN Content is governed by the End-User License Agreement, and you MAY NOT distribute this Content or use it with any artificial intelligence model or tool.
Printed by Galya Basol Kochav on 1/7/2026 1:55:52 PM. Copyright © 2026 National Comprehensive Cancer Network, Inc. All Rights Reserved.

PRINCIPLES OF SYSTEMIC ANTI-TUMOR THERAPY
Distant Metastatic Neuroendocrine Tumors of Lung and Thymus

- **Systemic therapy may not be appropriate for every patient with distant metastatic disease. Consider multidisciplinary discussion to determine the best choice of treatment, including: observation for patients with stable disease with mild tumor burden, locoregional therapy, cytoreductive surgery, or systemic therapy, which may be appropriate considerations.**
- **Currently, there are no data to support a specific sequence of regional versus systemic therapy and no data to guide sequencing of the following systemic therapy options.**
- **There is no known role for systemic treatment in the adjuvant setting for NETs.**
- **Doses and schedules are subject to appropriate modifications depending on the circumstances.**
- **For management of carcinoid syndrome, see NET-14.**

Lung/Thymus Neuroendocrine Tumors[a]			
	Preferred Regimens	**Other Recommended Regimens**	**Useful in Certain Circumstances**
Distant Metastases (clinically significant tumor burden and low grade [typical carcinoid] or evidence of disease progression or intermediate grade [atypical carcinoid] or symptomatic)	• Cabozantinib (category 1 if prior treatment with everolimus)[1] • Everolimus[b,c,2,3] (category 1 for nonfunctional lung NETs) • Octreotide LAR[e,g,6] or lanreotide[e,g,7,9] (if SSTR-positive and/or hormonal symptoms)	• None	• Carboplatin + etoposide[i,10,11] • Cisplatin + etoposide[i,10-12] • PRRT with lutetium Lu 177 dotatate (if SSTR-positive and progression on octreotide LAR or lanreotide) (NE-J) • Temozolomide[13,14] ± capecitabine[i,15,16] • If progression on standard SSA doses, above-label dose octreotide LAR[h] or lanreotide[h] (if SSTR-positive and/or hormonal symptoms) (category 2B)

[a] If clinically significant disease progression, treatment with octreotide LAR or lanreotide should be discontinued for non-functional tumors and continued in patients with functional tumors; these regimens may be used in combination with any of the subsequent options. For details on the administration of octreotide LAR or lanreotide with lutetium Lu 177 dotatate, see NE-J.
[b] Effectiveness of everolimus in the treatment of patients with carcinoid syndrome has not been established.
[c] Phase III study done in nonfunctional tumors.
[e] For symptom and/or tumor control, octreotide LAR 20–30 mg IM or lanreotide 120 mg SC every 4 weeks. Higher doses have been shown to be safe. For breakthrough symptoms, octreotide 100–250 mcg SC TID can be considered.
[g] If injection site-related complications occur, consider switching to another SSA.
[h] After clinical, symptomatic, or radiographic progression on standard SSA doses, for symptom and/or tumor control, above-label dosing octreotide LAR (up to 60 mg once a month) or lanreotide (up to 120 mg every 14 days) may be useful in select cases.
[i] Carboplatin + etoposide, cisplatin + etoposide, or temozolomide ± capecitabine can be considered for intermediate-grade/atypical tumors with Ki-67 proliferative index and mitotic index in the higher end of the defined spectrum.

Note: All recommendations are category 2A unless otherwise indicated.

References

Version 3.2025, 10/01/2025 © 2025 National Comprehensive Cancer Network® (NCCN®), All rights reserved. NCCN Guidelines® and this illustration may not be reproduced in any form without the express written permission of NCCN.

PLEASE NOTE that use of this NCCN Content is governed by the End-User License Agreement, and you MAY NOT distribute this Content or use it with any artificial intelligence model or tool.
Printed by Galya Basol Kochav on 1/7/2026 1:55:52 PM. Copyright © 2026 National Comprehensive Cancer Network, Inc. All Rights Reserved.

PRINCIPLES OF SYSTEMIC ANTI-TUMOR THERAPY

Locoregional Advanced and/or Distant Metastatic Pancreatic Neuroendocrine Tumors (Well-Differentiated Grade 1/2)

- **Systemic therapy may not be appropriate for every patient with locoregional advanced and/or distant metastatic disease. Consider multidisciplinary discussion to determine the best choice of treatment, including: observation for patients with stable disease with mild tumor burden, locoregional therapy, cytoreductive surgery, or systemic therapy.**
- **Currently, there are no data to support a specific sequence of regional versus systemic therapy and no data to guide sequencing of the following systemic therapy options.**
- **There is no known role for systemic treatment in the adjuvant setting for PanNETs.**
- **Doses and schedules are subject to appropriate modifications depending on the circumstances.**
- **For management of hormone-related symptoms and complications, see PanNET-1 through PanNET-10.**

Pancreatic Neuroendocrine Tumors (Well-Differentiated Grade 1/2)[a]			
	Preferred Regimens	**Other Recommended Regimens**	**Useful in Certain Circumstances**
Locoregional Advanced Disease and/or Distant Metastases	• Cabozantinib (category 1 if prior treatment with everolimus, lutetium Lu 177 dotatate, or sunitinib)[1] • Everolimus[17] (category 1 for progressive disease) 10 mg by mouth, daily • Sunitinib[18] (category 1 for progressive disease) 37.5 mg by mouth, daily • Octreotide LAR[e,f,g,j] or lanreotide[e,f,g,j,8] (if SSTR-positive) • First-line PRRT with lutetium Lu 177 dotatate (if SSTR-positive, Ki-67 ≥10%, and clinically significant tumor burden)[4] • PRRT with lutetium Lu 177 dotatate (if SSTR-positive and progression on octreotide LAR or lanreotide)[19] (NE-J) • Temozolomide + capecitabine[20] (preferred when tumor response is needed for symptoms or cytoreduction)	• Cytotoxic chemotherapy options considered in patients with bulky, symptomatic, and/or progressive disease include: ◊ FOLFOX[21] ◊ CAPEOX[22]	• If progression on standard SSA doses, above-label dose octreotide LAR[h,j] or lanreotide[h,j] (if SSTR-positive) • Octreotide LAR[e,g] or lanreotide[e,g] (if SSTR-negative)[23] • Consider belzutifan in the setting of germline *VHL* alteration in patients with progressive PanNETs[k,l,24] • Consider RT ± concurrent fluoropyrimidine-based chemotherapy for locally advanced unresectable disease (excluding small bowel mesenteric) (NE-I)

Footnotes on NE-H 4 of 12
References

Note: All recommendations are category 2A unless otherwise indicated.

Version 3.2025, 10/01/2025 © 2025 National Comprehensive Cancer Network® (NCCN®), All rights reserved. NCCN Guidelines® and this illustration may not be reproduced in any form without the express written permission of NCCN.

PLEASE NOTE that use of this NCCN Content is governed by the End-User License Agreement, and you MAY NOT distribute this Content or use it with any artificial intelligence model or tool.
Printed by Galya Basol Kochav on 1/7/2026 1:55:52 PM. Copyright © 2026 National Comprehensive Cancer Network, Inc. All Rights Reserved.

PRINCIPLES OF SYSTEMIC ANTI-TUMOR THERAPY
Locoregional Advanced and/or Distant Metastatic Pancreatic Neuroendocrine Tumors (Well-Differentiated Grade 1/2)
FOOTNOTES

[a] If clinically significant disease progression, treatment with octreotide LAR or lanreotide should be discontinued for non-functional tumors and continued in patients with functional tumors; these regimens may be used in combination with any of the subsequent options. For details on the administration of octreotide LAR or lanreotide with lutetium Lu 177 dotatate, see NE-J.

[e] For symptom and/or tumor control, octreotide LAR 20–30 mg IM or lanreotide 120 mg SC every 4 weeks. Higher doses have been shown to be safe. For breakthrough symptoms, octreotide 100–250 mcg SC TID can be considered.

[f] The PROMID trial showed an antitumor effect of octreotide LAR in advanced NETs of the midgut.[5] The CLARINET trial showed an antitumor effect of lanreotide in advanced, well-differentiated metastatic grade 1 and grade 2 GEP NETs.[6]

[g] If injection site-related complications occur, consider switching to another SSA.

[h] After clinical, symptomatic, or radiographic progression on standard SSA doses, for symptom and/or tumor control, above-label dosing octreotide LAR (up to 60 mg once a month) or lanreotide (up to 120 mg every 14 days) may be useful in select cases.

[j] For patients with insulinoma, octreotide LAR or lanreotide should be used only if SSTR-based imaging is positive. If used, they should be used with caution in patients with insulinoma as they may transiently worsen hypoglycemia (see Discussion for details).

[k] Data for the use of belzutifan for larger tumors, locally advanced unresectable tumors, and distant disease are extremely limited. Clinical trials are ongoing.

[l] The study excluded patients with prior systemic anticancer therapy, including anti-vascular endothelial growth factor therapy, patients needing immediate surgical intervention for tumor treatment, or patients with evidence of metastatic disease on screening imaging. Jonasch E, Donskov F, Iliopoulos O, et al. Belzutifan for renal cell carcinoma in von Hippel-Lindau disease. N Engl J Med 2021;385:2036-2046.

Note: All recommendations are category 2A unless otherwise indicated.

Version 3.2025, 10/01/2025 © 2025 National Comprehensive Cancer Network® (NCCN®), All rights reserved. NCCN Guidelines® and this illustration may not be reproduced in any form without the express written permission of NCCN.

PLEASE NOTE that use of this NCCN Content is governed by the End-User License Agreement, and you MAY NOT distribute this Content or use it with any artificial intelligence model or tool.
Printed by Galya Basol Kochav on 1/7/2026 1:55:52 PM. Copyright © 2026 National Comprehensive Cancer Network, Inc. All Rights Reserved.

PRINCIPLES OF SYSTEMIC ANTI-TUMOR THERAPY
Well-Differentiated, Grade 3 Neuroendocrine Tumors

Well-Differentiated, Grade 3 Neuroendocrine Tumors[25,26]		
Favorable Biology (eg, relatively low Ki-67 [<55%],[m] slow growing, positive SSTR-based PET imaging)	**Unfavorable Biology (eg, relatively high Ki-67 [≥55%],[m] faster growing, negative SSTR-based PET imaging)**	
Locally Advanced/Metastatic Disease (Unresectable with Clinically Significant Tumor Burden or Evidence of Disease Progression)	**Locoregional Disease (Resectable)**	**Locally Advanced/Metastatic Disease**
• Clinical trial (preferred) • Cabozantinib[1] • Chemotherapy (temozolomide ± capecitabine,[n,27] FOLFOX, CAPEOX, cisplatin/etoposide, or carboplatin/etoposide) • Everolimus • Octreotide LAR[e,g] or lanreotide[e,g] (if SSTR-positive and/or hormonal symptoms) (if progression on standard SSA doses, above-label dose octreotide LAR[h] or lanreotide[h] [category 2B]) • Pembrolizumab[o] (if MSI-H, dMMR, or TMB-H [≥10 mut/Mb]) • PRRT with lutetium Lu 177 dotatate (if SSTR-positive) (NE-J) • Sunitinib (pancreas only) • Consider RT (NE-I) ± concurrent fluoropyrimidine-based chemotherapy for locally advanced unresectable disease	• Clinical trial (preferred) • Neoadjuvant chemotherapy on a case-by-case basis (eg, Ki-67 ≥55%) ▸ Cisplatin/etoposide or carboplatin/etoposide ▸ Oxaliplatin-based therapy (FOLFOX, CAPEOX) ▸ Temozolomide ± capecitabine[n,27]	• Clinical trial (preferred) • Cisplatin/etoposide or carboplatin/etoposide • Irinotecan-based therapy (eg, FOLFIRI, cisplatin + irinotecan, or FOLFIRINOX) • Oxaliplatin-based therapy (ie, FOLFOX or CAPEOX) • Pembrolizumab[o] (if MSI-H, dMMR, or TMB-H [≥10 mut/Mb]) • Temozolomide ± capecitabine[n,27] • Nivolumab + ipilimumab[p,28,29] (category 2B) • Consider RT (NE-I) ± concurrent fluoropyrimidine-based chemotherapy for locally advanced unresectable disease

[e] For symptom and/or tumor control, octreotide LAR 20–30 mg IM or lanreotide 120 mg SC every 4 weeks. Higher doses have been shown to be safe. For breakthrough symptoms, octreotide 100–250 mcg SC TID can be considered.
[g] If injection site-related complications occur, consider switching to another SSA.
[h] After clinical, symptomatic, or radiographic progression on standard SSA doses, for symptom and/or tumor control, above-label dosing octreotide LAR (up to 60 mg once a month) or lanreotide (up to 120 mg every 14 days) may be useful in select cases.
[m] There are limitations in terms of the data for what the appropriate cutoff should be, as well as variability/heterogeneity of Ki-67 in a given tumor and over time in serial biopsies. The clinical course can be heterogeneous and treatment considerations need to account for both pathologic and clinical features.
[n] Temozolomide ± capecitabine may have more activity in tumors arising in the pancreas compared to GI NETs.
[o] Pembrolizumab can be considered for patients with MSI-H, dMMR, or advanced TMB-H tumors (as determined by an FDA-approved test) that have progressed following prior treatment and have no satisfactory alternative treatment options.
[p] Nivolumab and hyaluronidase-nvhy is not approved for concurrent use with IV ipilimumab; however, for nivolumab monotherapy, nivolumab and hyaluronidase-nvhy subcutaneous injection may be substituted for IV nivolumab. Nivolumab and hyaluronidase-nvhy has different dosing and administration instructions compared to IV nivolumab.

Note: All recommendations are category 2A unless otherwise indicated.

References

Version 3.2025, 10/01/2025 © 2025 National Comprehensive Cancer Network® (NCCN®), All rights reserved. NCCN Guidelines® and this illustration may not be reproduced in any form without the express written permission of NCCN.

PLEASE NOTE that use of this NCCN Content is governed by the End-User License Agreement, and you MAY NOT distribute this Content or use it with any artificial intelligence model or tool.
Printed by Galya Basol Kochav on 1/7/2026 1:55:52 PM. Copyright © 2026 National Comprehensive Cancer Network, Inc. All Rights Reserved.

PRINCIPLES OF SYSTEMIC ANTI-TUMOR THERAPY
Extrapulmonary Poorly Differentiated: Neuroendocrine Carcinoma/Large or Small Cell Carcinoma/ Mixed Neuroendocrine-Non-Neuroendocrine Neoplasm

Extrapulmonary Poorly Differentiated: Neuroendocrine Carcinoma/Large or Small Cell Carcinoma/Mixed Neuroendocrine-Non-Neuroendocrine Neoplasm		
Resectable disease	**Locoregional unresectable disease: Chemoradiation (concurrent/sequential)**	**Locoregional unresectable/metastatic disease: Systemic therapy[q]**
• Carboplatin + etoposide[30] • Cisplatin + etoposide[15] • FOLFIRI • FOLFOX • Temozolomide ± capecitabine	• Capecitabine (when etoposide + platinum is not feasible) • Carboplatin + etoposide • Cisplatin + etoposide	Chemotherapy: • Carboplatin + etoposide[30] • Cisplatin + etoposide[15] • Carboplatin + irinotecan • Cisplatin + irinotecan • FOLFIRI • FOLFIRINOX[31-33] • FOLFOX • Temozolomide ± capecitabine Immunotherapy: • Pembrolizumab[o] (if MSI-H, dMMR, or TMB-H tumors [≥10 mut/Mb]) • Nivolumab + ipilimumab[p,28,29,34,35] (category 2B) (only for metastatic disease with progression) Targeted therapy: • Dabrafenib + trametinib (if *BRAF* V600E mutation-positive)[r,36] • Entrectinib (if *NTRK* gene fusion-positive)[s,37,38] • Larotrectinib (if *NTRK* gene fusion-positive)[s,37,39] • Repotrectinib (if *NTRK* gene fusion-positive)[t,s,40] • Selpercatinib (if *RET* gene fusion-positive)[u,41]

Footnotes on NE-H 7 of 12
References

Note: All recommendations are category 2A unless otherwise indicated.

Version 3.2025, 10/01/2025 © 2025 National Comprehensive Cancer Network® (NCCN®), All rights reserved. NCCN Guidelines® and this illustration may not be reproduced in any form without the express written permission of NCCN.

PLEASE NOTE that use of this NCCN Content is governed by the End-User License Agreement, and you MAY NOT distribute this Content or use it with any artificial intelligence model or tool.
Printed by Galya Basol Kochav on 1/7/2026 1:55:52 PM. Copyright © 2026 National Comprehensive Cancer Network, Inc. All Rights Reserved.

PRINCIPLES OF SYSTEMIC ANTI-TUMOR THERAPY
Extrapulmonary Poorly Differentiated: Neuroendocrine Carcinoma/Large or Small Cell Carcinoma/ Mixed Neuroendocrine-Non-Neuroendocrine Neoplasm
FOOTNOTES

[o] Pembrolizumab can be considered for patients with MSI-H, dMMR, or advanced TMB-H tumors (as determined by an FDA-approved test) that have progressed following prior treatment and have no satisfactory alternative treatment options.
[p] Nivolumab and hyaluronidase-nvhy is not approved for concurrent use with IV ipilimumab; however, for nivolumab monotherapy, nivolumab and hyaluronidase-nvhy subcutaneous injection may be substituted for IV nivolumab. Nivolumab and hyaluronidase-nvhy has different dosing and administration instructions compared to IV nivolumab.
[q] There are no comparative data to define optimal treatment after first-line systemic therapy.
[r] Dabrafenib + trametinib can be considered for patients with *BRAF* V600E mutation-positive tumors that have progressed following prior treatment and have no satisfactory alternative treatment options.
[s] Entrectinib, larotrectinib, and repotrectinib can be considered for patients with *NTRK* gene fusion-positive tumors without a known acquired resistance mutation, that are metastatic or where surgical resection is likely to result in severe morbidity, and that have no satisfactory alternative treatments or that have progressed following treatment.
[t] Repotrectinib can also be considered for patients with *NTRK* gene fusion-positive tumors that progressed on a prior *NTRK*-targeted treatment.
[u] Selpercatinib can be considered for patients with *RET* gene fusion-positive tumors that have progressed on or following prior systemic treatment or who have no satisfactory alternative treatment options.

Note: All recommendations are category 2A unless otherwise indicated.

Version 3.2025, 10/01/2025 © 2025 National Comprehensive Cancer Network® (NCCN®), All rights reserved. NCCN Guidelines® and this illustration may not be reproduced in any form without the express written permission of NCCN.

PLEASE NOTE that use of this NCCN Content is governed by the End-User License Agreement, and you MAY NOT distribute this Content or use it with any artificial intelligence model or tool.
Printed by Galya Basol Kochav on 1/7/2026 1:55:52 PM. Copyright © 2026 National Comprehensive Cancer Network, Inc. All Rights Reserved.

PRINCIPLES OF SYSTEMIC ANTI-TUMOR THERAPY
Locoregional Unresectable/Metastatic Adrenocortical Carcinoma[v]

Locoregional Unresectable/Metastatic Adrenocortical Carcinoma		
Preferred Regimens	**Other Recommended Regimens**	**Useful in Certain Circumstances**
• Carboplatin + etoposide ± doxorubicin ± mitotane[w,x] • Cisplatin + etoposide[42] ± doxorubicin ± mitotane[w,x,43]	• Cabozantinib[44] • Mitotane monotherapy[w,x] • Pembrolizumab[45,46] ± mitotane[w,x]	• Nivolumab + ipilimumab[p,47] • Osilodrostat (for symptom control)[y,48,49]

[p] Nivolumab and hyaluronidase-nvhy is not approved for concurrent use with IV ipilimumab; however, for nivolumab monotherapy, nivolumab and hyaluronidase-nvhy subcutaneous injection may be substituted for IV nivolumab. Nivolumab and hyaluronidase-nvhy has different dosing and administration instructions compared to IV nivolumab.

[v] See Discussion for further information regarding the phase III FIRM-ACT trial.

[w] Monitor mitotane blood levels. Some institutions recommend target levels of 14–20 mcg/mL if tolerated. Steady-state levels may be reached several months after initiation of mitotane. Life-long hydrocortisone ± fludrocortisone replacement usually is required with mitotane.

[x] Mitotane may have more benefit for control of hormone symptoms than control of tumor.

[y] Studies have demonstrated efficacy in the setting of cortisol excess in states like adrenal adenomas, adrenal carcinomas, and ectopic ACTH syndrome.

Note: All recommendations are category 2A unless otherwise indicated.

References

Version 3.2025, 10/01/2025 © 2025 National Comprehensive Cancer Network® (NCCN®), All rights reserved. NCCN Guidelines® and this illustration may not be reproduced in any form without the express written permission of NCCN.

PLEASE NOTE that use of this NCCN Content is governed by the End-User License Agreement, and you MAY NOT distribute this Content or use it with any artificial intelligence model or tool.
Printed by Galya Basol Kochav on 1/7/2026 1:55:52 PM. Copyright © 2026 National Comprehensive Cancer Network, Inc. All Rights Reserved.

PRINCIPLES OF SYSTEMIC ANTI-TUMOR THERAPY
Pheochromocytoma/Paraganglioma

Pheochromocytoma/Paraganglioma	
Locally Unresectable	**Distant Metastases**
• Clinical trial • Belzutifan • Cabozantinib[50] • High-specific-activity (HSA) iobenguane I-131[z] or other 131I-MIBG (requires prior positive MIBG scan) • Selpercatinib[u] • Sunitinib 37.5 mg once daily[51] • Systemic chemotherapy (CVD [cyclophosphamide, vincristine, and dacarbazine] or temozolomide) • PRRT with lutetium Lu 177 dotatate (if SSTR-positive)[aa,bb,52,53] (NE-J) • SSAs (octreotide LAR or lanreotide)[g,cc,dd] (if SSTR-positive)[aa]	• Clinical trial • Belzutifan • Cabozantinib[50] • HSA iobenguane I-131[z] or other 131I-MIBG (requires prior positive MIBG scan) • Selpercatinib[u] • Sunitinib 37.5 mg once daily[51] • Systemic chemotherapy (CVD or temozolomide) • PRRT with lutetium Lu 177 dotatate (if SSTR-positive)[aa,bb,52,53] (NE-J) • SSAs (octreotide LAR or lanreotide)[g,cc,dd] (if SSTR-positive)[aa]

[g] If injection site-related complications occur, consider switching to another SSA.
[u] Selpercatinib can be considered for patients with *RET* gene fusion-positive tumors that have progressed on or following prior systemic treatment or who have no satisfactory alternative treatment options.
[z] HSA iobenguane I-131 is an FDA-approved option.
[aa] SSTR-PET tracers (eg, 68Ga-DOTATATE, 64Cu-DOTATATE, and 68Ga-DOTATOC).
[bb] Data are limited on the use of PRRT with lutetium Lu 177 dotatate in this setting.
[cc] Extrapolating from established treatment for other types of functional NETs, use of SSAs (octreotide LAR 20–30 mg IM or lanreotide 120 mg SC every 4 weeks) for hormone excess and symptom control can be considered. For breakthrough symptoms, octreotide 100–250 mcg SC TID can also be considered.
[dd] Data about antiproliferative effects of SSAs are limited and clinical trials are ongoing.

Note: All recommendations are category 2A unless otherwise indicated.

References

Version 3.2025, 10/01/2025 © 2025 National Comprehensive Cancer Network® (NCCN®), All rights reserved. NCCN Guidelines® and this illustration may not be reproduced in any form without the express written permission of NCCN.

PLEASE NOTE that use of this NCCN Content is governed by the End-User License Agreement, and you MAY NOT distribute this Content or use it with any artificial intelligence model or tool.
Printed by Galya Basol Kochav on 1/7/2026 1:55:52 PM. Copyright © 2026 National Comprehensive Cancer Network, Inc. All Rights Reserved.

PRINCIPLES OF SYSTEMIC ANTI-TUMOR THERAPY
REFERENCES

[1] Chan JA, Geyer S, Zemla T, et al. Phase 3 trial of cabozantinib to treat advanced neuroendocrine tumors. N Engl J Med 2025;392:653-665.
[2] Pavel ME, Baudin E, Oberg KE, et al. Efficacy of everolimus plus octreotide LAR in patients with advanced neuroendocrine tumor and carcinoid syndrome: final overall survival from the randomized, placebo-controlled phase 3 RADIANT-2 study. Ann Oncol 2017;28:1569-1575.
[3] Pavel ME, Singh S, Strosberg JR, et al. Health-related quality of life for everolimus versus placebo in patients with advanced, non-functional, well-differentiated gastrointestinal or lung neuroendocrine tumours (RADIANT-4): a multicentre, randomised, double-blind, placebo-controlled, phase 3 trial. Lancet Oncol 2017;18:1411-1422.
[4] Singh S, Halperin D, Myrehaug S, et al. [177Lu]Lu-DOTA-TATE plus long-acting octreotide versus high-dose long-acting octreotide for the treatment of newly diagnosed, advanced grade 2-3, well-differentiated, gastroenteropancreatic neuroendocrine tumours (NETTER-2): An open-label, randomised, phase 3 study. Lancet 2024;403:2807-2817.
[5] Strosberg JR, Caplin ME, Kunz PL, et al. 177Lu-dotatate plus long-acting octreotide versus high-dose long-acting octreotide in patients with midgut neuroendocrine tumors (NETTER-1): Final overall survival and long-term safety results from an open-label, randomised, controlled, phase 3 trial. Lancet Oncol 2021;22:1752-1763.
[6] Rinke A, Muller HH, Schade-Brittinger C, et al. Placebo-controlled, double-blind, prospective, randomized study on the effect of octreotide LAR in the control of tumor growth in patients with metastatic neuroendocrine midgut tumors: a report from the PROMID Study Group. J Clin Oncol 2009;27:4656-4663.
[7] Caplin ME, Pavel M, Cwikla JB, et al. Lanreotide in metastatic enteropancreatic neuroendocrine tumors. N Engl J Med 2014;371:224-233.
[8] Pavel M, Cwikla JB, Lombard-Bohas C, et al. Efficacy and safety of high-dose lanreotide autogel in patients with progressive pancreatic or midgut neuroendocrine tumors: CLARINET FORTE phase 2 study results. Eur J Cancer 2021;157:403-414.
[9] Baudin E, Capdevila J, Hörsch D, et al. Treatment of advanced BP-NETS with lanreotide autogel/depot vs placebo: the phase III SPINET study. Endocr Relat Cancer 2024;31:e230337.
[10] Chong CR, Wirth LJ, Nishino M, et al. Chemotherapy for locally advanced and metastatic pulmonary carcinoid tumors. Lung Cancer 2014;86:241-246.
[11] Rossi A, Di Maio M, Chiodini P, et al. Carboplatin- or cisplatin-based chemotherapy in first-line treatment of small-cell lung cancer: the COCIS meta-analysis of individual patient data. J Clin Oncol 2012;30:1692-1698.
[12] Iwasa S, Morizane C, Okusaka T, et al. Cisplatin and etoposide as first-line chemotherapy for poorly differentiated neuroendocrine carcinoma of the hepatobiliary tract and pancreas. Jpn J Clin Oncol 2010;40:313-318.
[13] Crona J, Fanola I, Lindholm DP, et al. Effect of temozolomide in patients with metastatic bronchial carcinoids. Neuroendocrinology 2013;98:151-155.
[14] Ekeblad S, Sundin A, Janson ET, et al. Temozolomide as monotherapy is effective in treatment of advanced malignant neuroendocrine tumors. Clin Cancer Res 2007;13:2986-2991.
[15] Al-Toubah T, Morse B, Strosberg J. Capecitabine and temozolomide in advanced lung neuroendocrine neoplasms. Oncologist 2020;25:e48-e52.
[16] Papaxoinis G, Kordatou Z, McCallum L, et al. Capecitabine and temozolomide in patients with advanced pulmonary carcinoid tumours. Neuroendocrinology 2020;110:413-421.
[17] Yao JC, Shah MH, Ito T, et al. Everolimus for advanced pancreatic neuroendocrine tumors. N Engl J Med 2011;364:514-523.
[18] Raymond E, Dahan L, Raoul JL, et al. Sunitinib malate for the treatment of pancreatic neuroendocrine tumors. N Engl J Med 2011;364:501-513.
[19] Zandee WT, Brabander T, Blažević A, et al. Symptomatic and radiological response to 177Lu-DOTATATE for the treatment of functioning pancreatic neuroendocrine tumors. J Clin Endocrinol Metab 2019;104:1336-1344.
[20] Kunz PL, Graham NT, Catalano PJ, et al. Randomized study of temozolomide or temozolomide and capecitabine in patients with advanced pancreatic neuroendocrine tumors (ECOG-ACRIN E2211). J Clin Oncol 2023;41:1359-1369.
[21] Kunz PL, Balise RR, Fehrenbacher L, et al. Oxaliplatin-fluoropyrimidine chemotherapy plus bevacizumab in advanced neuroendocrine tumors: an analysis of 2 phase II trials. Pancreas 2016;45:1394-1400.
[22] Spada F, Antonuzzo L, Marconcini R, et al. Oxaliplatin-based chemotherapy in advanced neuroendocrine tumors: clinical outcomes and preliminary correlation with biological factors. Neuroendocrinology 2016;103:806-814.
[23] Refardt J, Zandee WT, Brander T, et al. Inferior outcome of neuroendocrine tumor patients negative on somatostatin receptor imaging. Endocr Relat Cancer 2020;27:615-624.

Note: All recommendations are category 2A unless otherwise indicated.

Continued

Version 3.2025, 10/01/2025 © 2025 National Comprehensive Cancer Network® (NCCN®), All rights reserved. NCCN Guidelines® and this illustration may not be reproduced in any form without the express written permission of NCCN.

PLEASE NOTE that use of this NCCN Content is governed by the End-User License Agreement, and you MAY NOT distribute this Content or use it with any artificial intelligence model or tool.
Printed by Galya Basol Kochav on 1/7/2026 1:55:52 PM. Copyright © 2026 National Comprehensive Cancer Network, Inc. All Rights Reserved.

PRINCIPLES OF SYSTEMIC ANTI-TUMOR THERAPY
REFERENCES

[24] Jonasch E, Donskov F, Iliopoulos O, et al. Belzutifan for renal cell carcinoma in von Hippel-Lindau disease. N Engl J Med 2021;385:2036-2046.
[25] de Mestier L, Lamarca A, Hernando J, et al. Treatment outcomes of advanced digestive well-differentiated grade 3 NETs. Endocr Relat Cancer 2021;28:549-561.
[26] Apostolidis L, Dal Buono A, Merola E, et al. Multicenter analysis of treatment outcomes for systemic therapy in well differentiated grade 3 neuroendocrine tumors (NET G3). Cancers (Basel) 2021;13:1936.
[27] Chan DL, Bergsland EK, Chan JA, et al. Temozolomide in grade 3 gastroenteropancreatic neuroendocrine neoplasms: A multicenter retrospective review. Oncologist 2021;26:950-955.
[28] Patel SP, Mayerson E, Chae YK, et al. A phase II basket trial of Dual Anti-CTLA-4 and Anti-PD-1 Blockade in Rare Tumors (DART) SWOG S1609: High-grade neuroendocrine neoplasm cohort. Cancer 2021;127:3194-3201.
[29] Patel SP, Othus M, Chae YK, et al. A Phase II basket trial of Dual Anti-CTLA-4 and Anti-PD-1 Blockade in Rare Tumors (DART SWOG 1609) in patients with nonpancreatic neuroendocrine tumors. Clin Cancer Res 2020;26:2290-2296.
[30] Frizziero M, Spada F, Lamarca A, et al. Carboplatin in combination with oral or intravenous etoposide for extra-pulmonary, poorly-differentiated neuroendocrine carcinomas. Neuroendocrinology 2019;109:100-112.
[31] Zhu J, Strosberg JR, Dropkin E, Strickler JH. Treatment of high-grade metastatic pancreatic neuroendocrine carcinoma with FOLFIRINOX. J Gastrointest Cancer 2015;46:166-169.
[32] Borghesani M, Reni A, Lauricella E, et al. Efficacy and toxicity analysis of mFOLFIRINOX in high-grade gastroenteropancreatic neuroendocrine neoplasms. J Natl Compr Canc Netw 2024;22:e247005.
[33] Butt BP, Stokmo HL, Ladekarl M, et al. Folfirinox in the treatment of advanced gastroenteropancreatic neuroendocrine carsinomas [abstract]. Ann Oncol 2021;32:S915.
[34] Sherman S, Rotem O, Shochat T, et al. Efficacy of immune check-point inhibitors (ICPi) in large cell neuroendocrine tumors of lung (LCNEC). Lung Cancer 2020;143:40-46.
[35] Klein O, Kee D, Markman B, et al. Immunotherapy of ipilimumab and nivolumab in patients with advanced neuroendocrine tumors: A subgroup analysis of the CA209-538 Clinical Trial for Rare Cancers. Clin Cancer Res 2020;26:4454-4459.
[36] Salama AKS, Li S, Macrae ER, et al. Dabrafenib and trametinib in patients with tumors with *BRAFV600E* mutations: Results of the NCI-MATCH trial Subprotocol H. J Clin Oncol 2020;38:3895-3904.
[37] Sigal DS, Bhangoo MS, Hermel JA, et al. Comprehensive genomic profiling identifies novel NTRK fusions in neuroendocrine tumors. Oncotarget 2018;9:35809-35812.
[38] Doebele RC, Drilon A, Paz-Ares L, et al. Entrectinib in patients with advanced or metastatic NTRK fusion-positive solid tumours: Integrated analysis of three phase 1-2 trials. Lancet Oncol 2020;21:271-282.
[39] Drilon A, Laetsch TW, Kummar S, et al. Efficacy of larotrectinib in TRK fusion-positive cancers in adults and children. N Engl J Med 2018;378:731-739.
[40] Solomon B, Drilon A, Lin JJ, et al. Repotrectinib in patients (pts) with NTRK fusion-positive (NTRK+) advanced solid tumors, including NSCLC: Update from the phase I/II TRIDENT-1 trial [abstract]. Ann Oncol 2023;34:Abstract 1372P.
[41] Subbiah V, Wolf J, Konda B, et al. Tumour-agnostic efficacy and safety of selpercatinib in patients with RET fusion-positive solid tumours other than lung or thyroid tumours (LIBRETTO-001): A phase 1/2, open-label, basket trial. Lancet Oncol 2022;23:1261-1273.
[42] Williamson SK, Lew D, Miller GJ, et al. Phase II evaluation of cisplatin and etoposide followed by mitotane at disease progression in patients with locally advanced or metastatic adrenocortical carcinoma: a Southwest Oncology Group Study. Cancer 2000;88:1159-1165.
[43] Fassnacht M, Terzolo M, Allolio B, et al. Combination chemotherapy in advanced adrenocortical carcinoma. N Engl J Med 2012;366:2189-2197.
[44] Campbell MT, Balderrama-Brondani V, Jimenez C, et al. Cabozantinib monotherapy for advanced adrenocortical carcinoma: A single-arm, phase 2 trial. Lancet Oncol 2024;25:649-657.
[45] Raj N, Zheng Y, Kelly V, et al. PD-1 blockade in advanced adrenocortical carcinoma. J Clin Oncol 2020;38:71-80.
[46] Habra MA, Stephen B, Campbell M, et al. Phase II clinical trial of pembrolizumab efficacy and safety in advanced adrenocortical carcinoma. J Immunother Cancer 2019;7:253.
[47] Patel SP, Othus M, Chae YK, et al. Phase II basket trial of dual anti-CTLA-4 and anti-PD-1 blockade in rare tumors (DART) SWOG S1609: Adrenocortical carcinoma cohort. J Immunother Cancer 2024;12:e009074.
[48] Pivonello R, Simeoli C, Di Paola N, et al. Osilodrostat: A novel potent inhibitor of 11-beta-hydroxylase for the treatment of Cushing's syndrome. touchREV Endocrinol 2024;20:43-51.
[49] Fleseriu M, Biller BMK. Treatment of Cushing's syndrome with osilodrostat: Practical applications of recent studies with case examples. Pituitary 2022;25:795-809.

Continued

Note: All recommendations are category 2A unless otherwise indicated.

Version 3.2025, 10/01/2025 © 2025 National Comprehensive Cancer Network® (NCCN®), All rights reserved. NCCN Guidelines® and this illustration may not be reproduced in any form without the express written permission of NCCN.

PLEASE NOTE that use of this NCCN Content is governed by the End-User License Agreement, and you MAY NOT distribute this Content or use it with any artificial intelligence model or tool.
Printed by Galya Basol Kochav on 1/7/2026 1:55:52 PM. Copyright © 2026 National Comprehensive Cancer Network, Inc. All Rights Reserved.

PRINCIPLES OF SYSTEMIC ANTI-TUMOR THERAPY
REFERENCES

[50] Jimenez C, Habra MA, Campbell MT, et al. Cabozantinib in patients with unresectable and progressive metastatic phaeochromocytoma or paraganglioma (the Natalie trial): A single-arm, phase 2 trial. Lancet Oncol 2024;25:658-667.
[51] Baudin E, Goichot B, Berruti A, et al. Sunitinib for metastatic progressive phaeochromocytomas and paragangliomas: results from FIRSTMAPPP, an academic, multicentre, international, randomised, placebo-controlled, double-blind, phase 2 trial. Lancet 2024;403:1061-1070.
[52] Jaiswal SK, Sarathi V, Memon SS, et al. 177Lu-DOTATATE therapy in metastatic/inoperable pheochromocytoma-paraganglioma. Endocr Connect 2020;9:864-873.
[53] Vyakaranam AR, Crona J, Norlén O, et al. Favorable outcome in patients with pheochromocytoma and paraganglioma treated with 177Lu-DOTATATE. Cancers (Basel) 2019;11:909.

Note: All recommendations are category 2A unless otherwise indicated.

Version 3.2025, 10/01/2025 © 2025 National Comprehensive Cancer Network® (NCCN®), All rights reserved. NCCN Guidelines® and this illustration may not be reproduced in any form without the express written permission of NCCN.

PLEASE NOTE that use of this NCCN Content is governed by the End-User License Agreement, and you MAY NOT distribute this Content or use it with any artificial intelligence model or tool.
Printed by Galya Basol Kochav on 1/7/2026 1:55:52 PM. Copyright © 2026 National Comprehensive Cancer Network, Inc. All Rights Reserved.

PRINCIPLES OF RADIATION THERAPY[1,2]

General Principles:

- EBRT is a useful modality for select patients with locoregional or metastatic neuroendocrine or adrenal tumors.
- Decisions to use EBRT should be made in a multidisciplinary manner, considering patient factors, disease site/stage, and other therapeutic options available.
- EBRT may be considered for any histologic subtype of NETs (including well-differentiated grade 1/2/3, NECs, MiNENs, PCCs, and PGLs).
- Site-specific principles used for other primary cancer types are generally applicable; see appropriate NCCN Guidelines (eg, Pancreatic Adenocarcinoma, Hepatocellular Carcinoma, Biliary Tract Cancers).
- Higher EBRT doses have been associated with higher rates of disease control, but may be associated with increased risk of adverse events.[3]
- Intensity-modulated RT (IMRT)/volumetric modulated arc therapy (VMAT) techniques with image-guided RT (IGRT) may be needed to maintain RT precision and reduce the risk of toxicity.
- When administering SBRT[4]/stereotactic ablative radiotherapy (SABR),[5] IGRT techniques and motion management (if applicable) are strongly recommended to maintain RT precision and reduce the risk of toxicity.
- Using Response Evaluation Criteria in Solid Tumors, most patients achieve partial response or stable disease after EBRT, whereas complete response is less common.

Locoregional Disease:

- EBRT may be considered as a treatment option for select patients with locoregional NETs that are locally advanced/unresectable, potentially resectable but with unacceptable morbidity, or in patients who are medically inoperable due to comorbidity.
- Specific sites where EBRT may be considered include lung, thymus, and locations in the GI tract where resection may be associated with significant morbidity, such as esophagus, stomach, pancreas, or rectum. Depending on disease site, treatment may be adjuvant (postoperative), definitive, or palliative. For details on techniques, please refer to the appropriate NCCN Guidelines for the respective primary cancer types.
- EBRT generally does not play a role in the management of locoregional NETs of the small bowel, appendix, or colon (including mesenteric disease), due to risk of bowel injury. However, focal EBRT may be considered in select circumstances using conformal techniques and careful attention to bowel dose constraints.
- The use of concurrent radiosensitizing chemotherapy may be considered depending on the histologic subtype.

Metastatic Disease:

- EBRT may be considered in select situations for metastatic NET or PCC/PGL[6]:
  - Palliation of symptomatic metastases, such as painful bone metastases, or impending pathologic fracture or cord compression.
  - Liver-directed EBRT in patients with limited (<5) liver metastases. EBRT may be used alone, or in combination with other liver-directed therapies (resection, ablation, and/or embolization). Consider SBRT[4]/SABR[5] to achieve durable disease control. For details on techniques, please refer to the NCCN Guidelines for Hepatocellular Carcinoma, Principles of Radiation Therapy.
  - SBRT[4]/SABR[5] (≤5 fractions) and hypofractionated RT (6–20 fractions) can be considered for oligometastatic disease at multiple sites, including (but not limited to) liver, adrenal, bone (including spine), lung, mediastinum, head and neck, and lymph nodes. An ablative dose is delivered to the tumor while respecting the surrounding organ and adjacent normal tissue constraints.
  - Treatment of functional NETs to improve hormonal symptoms.
- Hypofractionated regimens (≤10 fractions) are most frequently used.

References

Note: All recommendations are category 2A unless otherwise indicated.

Version 3.2025, 10/01/2025 © 2025 National Comprehensive Cancer Network® (NCCN®), All rights reserved. NCCN Guidelines® and this illustration may not be reproduced in any form without the express written permission of NCCN.

PLEASE NOTE that use of this NCCN Content is governed by the End-User License Agreement, and you MAY NOT distribute this Content or use it with any artificial intelligence model or tool.
Printed by Galya Basol Kochav on 1/7/2026 1:55:52 PM. Copyright © 2026 National Comprehensive Cancer Network, Inc. All Rights Reserved.

PRINCIPLES OF RADIATION THERAPY
REFERENCES

[1] Chan DL, Thompson R, Lam M, et al. External beam radiotherapy in the treatment of gastroenteropancreatic neuroendocrine tumours: A systematic review. Clin Oncol (R Coll Radiol) 2018;30:400-408.
[2] Contessa JN, Griffith KA, Wolff E, et al. Radiotherapy for pancreatic neuroendocrine tumors. Int J Radiat Oncol Biol Phys 2009;75:1196-1200.
[3] Chen KS, Lawhn-Heath C, Behr S, et al. Outcomes after high-dose radiation in the management of neuroendocrine neoplasms. PLoS One 2021;16:e0252574.
[4] Myrehaug S, Hallet J, Chu W, et al. Proof of concept for stereotactic body radiation therapy in the treatment of functional neuroendocrine neoplasms. J Radiosurg SBRT 2020;6:321-324.
[5] Hudson JM, Chung HTK, Chu W, et al. Stereotactic ablative radiotherapy for the management of liver metastases from neuroendocrine neoplasms: A preliminary study. Neuroendocrinology 2022;112:153-160.
[6] Breen W, Bancos I, Young WF Jr, et al. External beam radiation therapy for advanced/unresectable malignant paraganglioma and pheochromocytoma. Adv Radiat Oncol 2017;3:25-29.

Note: All recommendations are category 2A unless otherwise indicated.

Version 3.2025, 10/01/2025 © 2025 National Comprehensive Cancer Network® (NCCN®), All rights reserved. NCCN Guidelines® and this illustration may not be reproduced in any form without the express written permission of NCCN.

PLEASE NOTE that use of this NCCN Content is governed by the End-User License Agreement, and you MAY NOT distribute this Content or use it with any artificial intelligence model or tool.
Printed by Galya Basol Kochav on 1/7/2026 1:55:52 PM. Copyright © 2026 National Comprehensive Cancer Network, Inc. All Rights Reserved.

PRINCIPLES OF PEPTIDE RECEPTOR RADIONUCLIDE THERAPY WITH LUTETIUM LU 177 DOTATATE[1-10]

- **Lutetium Lu 177 dotatate is a radiolabeled SSA used as PRRT.**
- **It is approved by the FDA for the treatment of adult and pediatric patients ≥12 years of age with SSTR-positive GEP NETs, including foregut, midgut, and hindgut NETs.[1,2]**
- **Currently there are no randomized data, but there are reports of treatment efficacy and favorable outcomes when PRRT is used for PCCs, PGLs, and lung/thymic NETs.[3-10] If feasible, participation in clinical trials of PRRT is strongly recommended for patients with such rare groups of NET.**
- **PRRT may reduce symptoms for symptomatic insulinoma and other functional NETs.[11]**

Key Eligibility:

- **Well-differentiated NET**
- **SSTR expression of NET as detected by SSTR-PET/CT or SSTR-PET/MR (NE-D)[a,b]**
- **Adequate bone marrow, renal, and hepatic function**

Preparing Eligible Patients for Lutetium Lu 177 Dotatate

- **Do not administer long-acting SSAs (eg, octreotide LAR, lanreotide) for 4 weeks prior to each lutetium Lu 177 dotatate treatment. Administer short-acting octreotide as needed for symptom control of carcinoid syndrome; discontinue at least 24 hours prior to initiating lutetium Lu 177 dotatate.**
- **Counsel patients about the risks of:**
  - **Radiation exposure to themselves and others**
  - **Myelosuppression**
  - **Secondary myelodysplastic syndrome and leukemia**
  - **Renal toxicity**
  - **Hepatic toxicity**
  - **Neuroendocrine hormonal crisis or carcinoid crisis: flushing, diarrhea, hypotension, bronchoconstriction, or other signs and symptoms**
  - **Embryo-fetal toxicity**
  - **Infertility**
  - **Nausea/vomiting (related to amino acid infusion required as part of therapy)**
- **Discuss radiation safety precautions during and after lutetium Lu 177 dotatate.**
- **Verify pregnancy status in patients of childbearing potential.**
- **Advise on use of effective contraception for up to 7 months (patients assigned female at birth) and 4 months (patients assigned male at birth) after last dose of lutetium Lu 177 dotatate.**

[a] SSTR-PET/CT or SSTR-PET/MRI of skull vertex to mid-thigh with multiphase IV contrast when possible. Data are limited on the optimal timing of scans following administration of SSAs.
[b] SSTR-PET tracers (eg, 68Ga-DOTATATE, 64Cu-DOTATATE, and 68Ga-DOTATOC).

References

Note: All recommendations are category 2A unless otherwise indicated.

Version 3.2025, 10/01/2025 © 2025 National Comprehensive Cancer Network® (NCCN®), All rights reserved. NCCN Guidelines® and this illustration may not be reproduced in any form without the express written permission of NCCN.

PLEASE NOTE that use of this NCCN Content is governed by the End-User License Agreement, and you MAY NOT distribute this Content or use it with any artificial intelligence model or tool.
Printed by Galya Basol Kochav on 1/7/2026 1:55:52 PM. Copyright © 2026 National Comprehensive Cancer Network, Inc. All Rights Reserved.

PRINCIPLES OF PEPTIDE RECEPTOR RADIONUCLIDE THERAPY WITH LUTETIUM LU 177 DOTATATE[1-10]

Dose and Administration

- Lutetium Lu 177 dotatate is administered via peripheral IV at a dose of 200 mCi over 30–40 minutes every 8 weeks for a total of 4 treatments (unless dose modification required secondary to adverse reactions).
- Amino acid solution:
  - IV infusion of amino acids is a critical part of lutetium Lu 177 dotatate therapy for nephroprotection.
  - Amino acids are administered 30 minutes before, concurrently with, and 3 hours after lutetium Lu 177 dotatate.
  - Commercial (nonselective) amino acid formulations infused at high rates are more emetogenic than compounded amino acids.
    - Solutions containing only arginine/lysine are only available through compounding pharmacies, but are much less emetogenic than commercial amino acid solutions. Options for compounded amino acids are as follows:
      - Arginine 2.5%/lysine 2.5% in 1000 mL NaCl infused at 250 mL/h for 4 hours.
      - Commercial amino acid formulation (typically containing approximately 20 amino acids) mixed in sterile water for a total volume of approximately 2000 mL. Infusion rate can be increased to roughly 300–500 mL/h, as tolerated. Recommend starting at low rate of 50 mL/h and increasing by 10 mL/h every 10 minutes as tolerated based on symptoms such as nausea. Lutetium Lu 177 dotatate infusion should begin after at least 250 mL of amino acids have been infused.
- Antiemetic medications should be available prior to and during amino acid and lutetium Lu 177 dotatate infusions. Aggressive antiemetic prophylaxis is recommended for patients when nonselective amino acid solutions are used with PRRT. Routine prophylactic antiemetics may not be necessary if selective (arginine/lysine) amino acid solutions are used, but should be available as needed.

Post-treatment Instructions

- Detailed instructions on post-treatment radiation-risk reduction strategies should be provided per institutional radiation safety guidelines.
- Complete blood count, serum chemistry including renal and hepatic functions should be monitored.
- SSAs (octreotide or lanreotide) can be administered 4–24 hours after each lutetium Lu 177 dotatate treatment.

Timing of SSAs (Octreotide or Lanreotide) in Relation to Lutetium Lu 177 Dotatate

- Most patients treated with PRRT will have had disease progression on a first-line SSA.
- Generally, patients with hormonally functional tumors should continue octreotide LAR or lanreotide along with lutetium Lu 177 dotatate. It is unclear whether patients with nonfunctional tumors benefit from continuation of SSA treatment during and after lutetium Lu 177 dotatate treatment.
- There are theoretical concerns regarding the competition between SSAs and lutetium Lu 177 dotatate for SSTR binding. Therefore, the following actions are recommended:
  - Do not administer long-acting SSAs for 4 weeks prior to each lutetium Lu 177 dotatate treatment.
  - Stop short-acting SSAs 24 hours before each lutetium LU 177 dotatate treatment.
  - SSAs (short- and long-acting) can be resumed 4–24 hours after each lutetium Lu 177 dotatate treatment.

References

Note: All recommendations are category 2A unless otherwise indicated.

Version 3.2025, 10/01/2025 © 2025 National Comprehensive Cancer Network® (NCCN®), All rights reserved. NCCN Guidelines® and this illustration may not be reproduced in any form without the express written permission of NCCN.

PLEASE NOTE that use of this NCCN Content is governed by the End-User License Agreement, and you MAY NOT distribute this Content or use it with any artificial intelligence model or tool.
Printed by Galya Basol Kochav on 1/7/2026 1:55:52 PM. Copyright © 2026 National Comprehensive Cancer Network, Inc. All Rights Reserved.

PRINCIPLES OF PEPTIDE RECEPTOR RADIONUCLIDE THERAPY WITH LUTETIUM LU 177 DOTATATE
REFERENCES

[1] Prescribing information for lutetium Lu 177 dotatate injection, for intravenous use. Available at: https://www.accessdata.fda.gov/drugsatfda_docs/label/2024/208700s031lbl.pdf. Accessed June 18, 2024.
[2] Strosberg J, El-Haddad G, Wolin E, et al. Phase 3 trial of ^{177}Lu-dotatate for midgut neuroendocrine tumors. N Engl J Med 2017;376:125-135.
[3] Brabander T, van der Zwan WA, Teunissen JJM, et al. Long-term efficacy, survival, and safety of [^{177}Lu-DOTA^{0},Tyr^{3}] octreotate in patients with gastroenteropancreatic and bronchial neuroendocrine tumors. Clin Cancer Res 2017;23:4617-4624.
[4] Baum RP, Kulkarni HR, Singh A, et al. Results and adverse events of personalized peptide receptor radionuclide therapy with 90Yttrium and 177Lutetium in 1048 patients with neuroendocrine neoplasms. Oncotarget 2018;9:16932-16950.
[5] Sharma N, Naraev BG, Engelman EG, et al. Peptide receptor radionuclide therapy outcomes in a North American cohort with metastatic well-differentiated neuroendocrine tumors. Pancreas 2017;46:151-156.
[6] Katona BW, Roccardo GA, Soulen MC, et al. Efficacy of peptide receptor radionuclide therapy in a United States-based cohort of metastatic neuroendocrine tumor patients: Single-institution retrospective analysis. Pancreas 2017;46:1121-1126.
[7] Kong G, Grozinsky-Glasberg S, Hofman MS, et al. Efficacy of peptide receptor radionuclide therapy for functional metastatic paraganglioma and pheochromocytoma. J Clin Endocrinol Metab 2017;102:3278-3287.
[8] Vyakaranam AR, Crona J, Norlén O, et al. Favorable outcome in patients with pheochromocytoma and paraganglioma treated with 177Lu-DOTATATE. Cancers (Basel) 2019;11:909.
[9] Jaiswal SK, Sarathi V, Menon SS, et al. 177Lu-DOTATATE therapy in metastatic/inoperable pheochromocytoma-paraganglioma. Endocr Connect 2020;9:864-873.
[10] Mirvis E, Toumpanakis C, Mandair D, et al. Efficacy and tolerability of peptide receptor radionuclide therapy (PRRT) in advanced metastatic bronchial neuroendocrine tumours (NETs). Lung Cancer 2020;150:70-75.
[11] Zandee WT, Brabander T, Blažević A, et al. Symptomatic and radiological response to 177Lu-DOTATATE for the treatment of functioning pancreatic neuroendocrine tumors. J Clin Endocrinol Metab 2019;104:1336-1344.

Note: All recommendations are category 2A unless otherwise indicated.

Version 3.2025, 10/01/2025 © 2025 National Comprehensive Cancer Network® (NCCN®), All rights reserved. NCCN Guidelines® and this illustration may not be reproduced in any form without the express written permission of NCCN.

PLEASE NOTE that use of this NCCN Content is governed by the End-User License Agreement, and you MAY NOT distribute this Content or use it with any artificial intelligence model or tool.
Printed by Galya Basol Kochav on 1/7/2026 1:55:52 PM. Copyright © 2026 National Comprehensive Cancer Network, Inc. All Rights Reserved.

PRINCIPLES OF LIVER-DIRECTED THERAPY FOR NEUROENDOCRINE TUMOR METASTASES

- **Liver-directed therapy[1] consists of four categories of treatment:**
  - **Surgical resection (which may include intraoperative thermal ablation of lesions); See Principles of Surgical Management of Neuroendocrine Tumors (NE-F)**
  - **Hepatic arterial embolization, including bland transarterial embolization [TAE], transarterial chemoembolization [TACE], and transarterial radioembolization [TARE]**
  - **Percutaneous thermal ablation**
  - **RT (SBRT/SABR) (NE-I)**

Indications for Hepatic Arterial Embolization[2]

- **Embolization is recommended for well-differentiated NETs with liver-dominant, unresectable metastases that are:**
  - **Symptomatic on an SSA or following another form of systemic therapy**
  - **Progressive on an SSA or following another form of systemic therapy**
  - **Presenting with bulky liver disease; embolization may be used as cytoreduction therapy without waiting for progression.**
- **Objective radiologic response rates vary widely in retrospective studies, but average approximately 60%, with symptom palliation in approximately 85% of patients with hormonal syndromes.**
- **Relative contraindications include significant baseline liver dysfunction (eg, jaundice, ascites) and a liver tumor burden >70%. Prior Whipple surgery or biliary instrumentation (ie, sphincterotomy, stent) increases the risk of liver abscess due to biliary bacterial colonization; infectious complications occur in about 20% of cases following TAE/TACE and 8% after TARE, even with broad-spectrum antibiotic coverage.**

Embolization Modalities

- **TAE and TACE**
  - **There are no completed randomized studies comparing TAE with conventional TACE and both are acceptable.**
  - **Drug-eluting embolics are associated with increased hepatobiliary toxicity in the NET population, and are not recommended.**
  - **In patients with bilobar disease, TAE/TACE is generally performed over at least two procedures, approximately 1 month apart. Patients with very high liver tumor burden may require three or four embolizations to safely treat the entire liver. Short-acting octreotide should be administered pre-embolization for patients with hormonal syndromes. Overnight observation is typically appropriate to monitor and treat symptoms of post-embolization syndrome such as pain and nausea and exacerbation of hormone-related symptoms.**
- **TARE may be considered particularly in the following scenarios:**
  - **Lobar or segmental (less than lobular) disease distribution.**
  - **Patients with prior Whipple surgery or biliary tract instrumentation (lower risk of hepatobiliary infection than TAE/TACE).[3-6]**
  - **TARE is better tolerated than TAE/TACE, but late radioembolization-induced chronic hepatotoxicity may occur in long-term survivors, and is particularly a concern among patients undergoing bilobar radioembolization.**
  - **To date there is no evidence for or against the safety of sequencing TARE and PRRT.[7,8]**

Ablative Therapy

- **Percutaneous thermal ablation, often using microwave energy (radiofrequency and cryoablation are also acceptable), can be considered for oligometastatic liver disease, generally up to four lesions each <3 cm. Feasibility considerations include safe percutaneous imaging-guided approach to the target lesions, and proximity to vessels, bile ducts, or adjacent non-target structures that may require hydro- or aero-dissection for displacement.**

References

Note: All recommendations are category 2A unless otherwise indicated.

Version 3.2025, 10/01/2025 © 2025 National Comprehensive Cancer Network® (NCCN®), All rights reserved. NCCN Guidelines® and this illustration may not be reproduced in any form without the express written permission of NCCN.

PLEASE NOTE that use of this NCCN Content is governed by the End-User License Agreement, and you MAY NOT distribute this Content or use it with any artificial intelligence model or tool.
Printed by Galya Basol Kochav on 1/7/2026 1:55:52 PM. Copyright © 2026 National Comprehensive Cancer Network, Inc. All Rights Reserved.

PRINCIPLES OF LIVER-DIRECTED THERAPY FOR NEUROENDOCRINE TUMOR METASTASES
REFERENCES

[1] Habibollahi P, Bai HX, Sanampudi S, et al. Effectiveness of liver-directed therapy for the management of intractable hypoglycemia in metastatic insulinoma. Pancreas 2020;49:763-767.
[2] Linch F, Thompson S, Fleming C, et al. Hepatic artery embolization for palliation of symptomatic hypoglycemia in patients with hepatic insulinoma metastases. J Endocr Soc 2021;5:bvab149.
[3] Devulapalli KK, Fidelman N, Soulen MC, et al. 90Y radioembolization for hepatic malignancy in patients with previous biliary intervention: Multicenter analysis of hepatobiliary infections. Radiology 2018;288:774-781.
[4] Patel S, Tuite CM, Mondschein JI, Soulen MC. Effectiveness of an aggressive antibiotic regimen for chemoembolization in patients with previous biliary intervention. J Vasc Interv Radiol 2006;17:1931-1934.
[5] Kim W, Clark TW, Baum RA, Soulen MC. Risk factors for liver abscess formation after hepatic chemoembolization. J Vasc Interv Radiol 2001;12:965-968.
[6] Cholapranee A, van Houten D, Deitrick G, et al. Risk of liver abscess formation in patients with prior biliary intervention following yttrium-90 radioembolization. Cardiovasc Intervent Radiol 2015;38:397-400.
[7] Braat AJAT, Ahmadzadehfar H, Kappadath SC, et al. Radioembolization with 90Y resin microspheres of neuroendocrine liver metastases after initial peptide receptor radionuclide therapy. Cardiovasc Intervent Radiol 2020;43:246-253.
[8] Braat AJAT, Bruijnen RCG, van Rooij R, et al. Additional holmium-166 radioembolisation after lutetium-177-dotatate in patients with neuroendocrine tumour liver metastases (HEPAR PLuS): a single-centre, single-arm, open-label, phase 2 study. Lancet Oncol 2020;21:561-570.

Note: All recommendations are category 2A unless otherwise indicated.

Version 3.2025, 10/01/2025 © 2025 National Comprehensive Cancer Network® (NCCN®), All rights reserved. NCCN Guidelines® and this illustration may not be reproduced in any form without the express written permission of NCCN.

PLEASE NOTE that use of this NCCN Content is governed by the End-User License Agreement, and you MAY NOT distribute this Content or use it with any artificial intelligence model or tool.
Printed by Galya Basol Kochav on 1/7/2026 1:55:52 PM. Copyright © 2026 National Comprehensive Cancer Network, Inc. All Rights Reserved.

PRINCIPLES OF HORMONE CONTROL

Carcinoid Syndrome

- **Carcinoid syndrome primarily occurs in patients with metastatic well-differentiated NETs originating in the distal small intestine and proximal colon (midgut). Carcinoid syndrome can also be secondary to pulmonary NETs and rarely PanNETs. Serotonin along with other vasoactive substances contributes to the syndrome.**
- **Signs and symptoms include flushing, diarrhea, wheezing (rare), and CHD (in patients with highly elevated serotonin levels).**
  - **Serotonin is thought to be the most important factor in the etiology of carcinoid syndrome diarrhea and CHD, but the etiology of flushing is less well understood.**
  - **Refractory flushing or diarrhea is defined as suboptimal symptom control in the setting of long-acting SSAs (octreotide LAR or lanreotide) used in approved doses.**
  - **It is important to note that diarrhea can be multifactorial: other common causes include direct side effects from SSAs, pancreatic exocrine insufficiency from SSA use resulting in steatorrhea, bile malabsorption from ileocecectomy or cholecystectomy, and short-gut syndrome.**
- **Carcinoid crisis is a potentially life-threatening form of carcinoid syndrome caused by a massive release of vasoactive substances, often triggered by tumor manipulation or anesthesia. It is typically associated with hypotension, diarrhea, and blood pressure fluctuation.**
  - **The prevalence and risk of carcinoid crisis varies greatly across studies according to the diagnostic criteria used.[1]**
- **In patients with carcinoid syndrome, invasive procedures should only be performed in centers with experienced anesthesiologists.**
- **Octreotide should be available as needed during surgical procedures for patients with carcinoid syndrome who develop hemodynamic instability that could indicate carcinoid crisis. Doses of octreotide (100–500 mcg IV) can be used, potentially followed by IV infusion of octreotide (50–300 mcg/h).[2]**
- **Therapeutic levels of octreotide would not be expected to be reached for 10–14 days after LAR injections. Short-acting SC octreotide PRN can help address suboptimal symptom control quickly.**
- **Vasopressors can be used for severe and/or prolonged hypotension.[2,3]**
- **Prophylactic administration of octreotide prior to surgery can be utilized although intraoperative complications can still arise, and the routine use of prophylactic octreotide has been called into question.[2-5]**

[1] Maxwell JE, Naraev B, Halperin DM, Choti MA, Halfdanarson TR. Shifting paradigms in the pathophysiology and treatment of carcinoid crisis. Ann Surg Oncol 2022;29:3072-3084.
[2] Howe JR, Cardona K, Fraker DL, et al. The surgical management of small bowel neuroendocrine tumors: Consensus Guidelines of the North American Neuroendocrine Tumor Society. Pancreas 2017;46:715-731.
[3] McCully BH, Kozuma K, Pommier S, Pommier RF. Comparison of octreotide and vasopressors as first-line treatment for intraoperative carcinoid crisis. Ann Surg Oncol 2024;31:2996-3002.
[4] Kaltsas G, Caplin M, Davies P, et al. ENETS Consensus Guidelines for the standards of care in neuroendocrine tumors: Pre- and perioperative therapy in patients with neuroendocrine tumors. Neuroendocrinology 2017;105:245-254.
[5] Wonn SM, Ratzlaff AN, Pommier SJ, McCully BH, Pommier RF. A prospective study of carcinoid crisis with no perioperative octreotide. Surgery 2022;171:88-93.

Note: All recommendations are category 2A unless otherwise indicated.

Version 3.2025, 10/01/2025 © 2025 National Comprehensive Cancer Network® (NCCN®), All rights reserved. NCCN Guidelines® and this illustration may not be reproduced in any form without the express written permission of NCCN.

PLEASE NOTE that use of this NCCN Content is governed by the End-User License Agreement, and you MAY NOT distribute this Content or use it with any artificial intelligence model or tool.
Printed by Galya Basol Kochav on 1/7/2026 1:55:52 PM. Copyright © 2026 National Comprehensive Cancer Network, Inc. All Rights Reserved.

PRINCIPLES OF HORMONE CONTROL

Symptom Management of Carcinoid Syndrome

- **Carcinoid syndrome–diarrhea and flushing**
  - **Long-acting SSAs (octreotide LAR and lanreotide) are highly active for control of both flushing and diarrhea.**
  - **Telotristat 250 mg TID can be considered specifically for patients with refractory diarrhea secondary to carcinoid syndrome (usually with proven elevated serotonin or 5-HIAA), in combination with long-acting SSA. Symptomatic benefit can sometimes be delayed for several weeks after initiation of the drug.**
  - **Patients who experience symptom exacerbation towards the end of each 4-week SSA cycle can often benefit from more frequent administration (ie, every 3 weeks). Dose escalation can also sometimes benefit patients with refractory symptoms.**
  - **Short-acting octreotide, given subcutaneously, administered at doses of 100–250 mcg every 8 hours as needed, can be prescribed to patients with suboptimal control of flushing and/or diarrhea.**
  - **Serotonin antagonists such as ondansetron can improve refractory carcinoid syndrome diarrhea in patients with refractory symptoms.**
  - **Treatments that effectively cytoreduce secretory metastatic tumors are likely to palliate hormonal symptoms. For patients with liver-dominant disease, surgical cytoreduction or hepatic arterial embolization are highly effective at control of flushing and/or diarrhea. PRRT with lutetium Lu 177 dotatate has been associated with delay in diarrhea progression.**
  - **Nonspecific antidiarrheals (ie, loperamide, diphenoxylate/atropine, tincture of opium) can be beneficial for management of refractory diarrhea, regardless of cause.**

- **Non-carcinoid syndrome–diarrhea**
  - **In patients who develop diarrhea/steatorrhea exacerbation while on SSA, a trial of pancreatic enzymes for pancreatic exocrine insufficiency should be considered.**
  - **Patients with persistent diarrhea after ileocecectomy or cholecystectomy, especially if associated with urgency, can be treated empirically with bile acid-binding drugs such as cholestyramine.**
  - **For patients with presumed short-gut syndrome, suggest referral to appropriate gastroenterologist expert.**
  - **Nonspecific antidiarrheals (ie, loperamide, diphenoxylate/atropine, tincture of opium) can be beneficial for management of refractory diarrhea, regardless of cause.**

- **Carcinoid heart disease**
  - **CHD should be monitored by a cardiologist with expertise in the disease as the echocardiographic diagnosis of CHD can be challenging. Valve replacement (typically tricuspid and pulmonary) is indicated for patients with symptomatic disease.**

Note: All recommendations are category 2A unless otherwise indicated.

Version 3.2025, 10/01/2025 © 2025 National Comprehensive Cancer Network® (NCCN®), All rights reserved. NCCN Guidelines® and this illustration may not be reproduced in any form without the express written permission of NCCN.

PLEASE NOTE that use of this NCCN Content is governed by the End-User License Agreement, and you MAY NOT distribute this Content or use it with any artificial intelligence model or tool.
Printed by Galya Basol Kochav on 1/7/2026 1:55:52 PM. Copyright © 2026 National Comprehensive Cancer Network, Inc. All Rights Reserved.

Pancreatic Neuroendocrine Tumors

- **Medical, surgical, and interventional treatments that effectively cytoreduce secretory tumors are likely to also palliate hormonal symptoms. The following recommendations pertain to non-cytotoxic treatments, which can reduce hormonal secretions or mitigate secretory effects.**

Hormone	Management
Gastrin	• Manage gastric hypersecretion with high-dose PPIs, generally given two times a day. • Consider octreotide LAR[a] or lanreotide.
Insulin	• Stabilize glucose levels with diet and/or diazoxide or everolimus. • Octreotide LAR[a] or lanreotide can be considered but only if tumor expresses SSTRs. In the absence of SSTRs, octreotide LAR[a] or lanreotide can profoundly worsen hypoglycemia.
VIP	• Octreotide LAR[a] or lanreotide are the first-line management for control of hormone symptoms. • Correct electrolyte imbalance (K+, Mg2+, HCO3-) and dehydration. • Corticosteroids can be effective in patients with SSTR-refractory disease.
Glucagon	• Octreotide LAR[a] or lanreotide are the first-line management for control of hormone symptoms. • Treat hyperglycemia and diabetes, as appropriate.

[a] Short-acting octreotide can be added to octreotide LAR or lanreotide for rapid relief of symptoms or for breakthrough symptoms.

Note: All recommendations are category 2A unless otherwise indicated.

Version 3.2025, 10/01/2025 © 2025 National Comprehensive Cancer Network® (NCCN®), All rights reserved. NCCN Guidelines® and this illustration may not be reproduced in any form without the express written permission of NCCN.

PLEASE NOTE that use of this NCCN Content is governed by the End-User License Agreement, and you MAY NOT distribute this Content or use it with any artificial intelligence model or tool.
Printed by Galya Basol Kochav on 1/7/2026 1:55:52 PM. Copyright © 2026 National Comprehensive Cancer Network, Inc. All Rights Reserved.

American Joint Committee on Cancer (AJCC)
TNM Staging System for Well-Differentiated Neuroendocrine Tumors of the Jejunum and Ileum (NET G1, G2, and G3) (Version 9, 2023)

Table 1. **Definitions for T, N, M**

T	Primary Tumor
TX	Primary tumor cannot be assessed
T0	No evidence of primary tumor
T1	Tumor invades mucosa or submucosa, and ≤1 cm in greatest dimension
T2	Tumor invades muscularis propria or >1 cm in greatest dimension
T3	Tumor invades through the muscularis propria into subserosal tissue without penetration of overlying serosa
T4	Tumor invades visceral peritoneum (serosal) or other organs or adjacent structures

Note: Multiple tumors should be designated as such (the largest tumor should be used to assign T category):
- Use T(#); e.g., pT3(4) N0 M0, or
- Use the *m* suffix, T(m); e.g., pT3(m) N0 M0.

N	Regional Lymph Nodes
NX	Regional lymph nodes cannot be assessed
N0	No tumor involvement of regional lymph node(s)
N1	Tumor involvement or less than 12 regional lymph node(s)
N2	Tumor involvement of large mesenteric masses (>2 cm) and/or extensive nodal deposits (12 or greater), especially those that encase the superior mesenteric vessels *Note*: Mesenteric masses ≤2 cm should be stated in the pathology report as being present and collected by registrars but do not affect stage.

M		Distant Metastasis
cM0		No distant metastasis
cM1		Distant metastasis
	cM1a	Metastasis confined to liver
	cM1b	Metastases in at least one extrahepatic site (e.g., lung, ovary, nonregional lymph node, peritoneum, bone)
	cM1c	Both hepatic and extrahepatic metastases
pM1		Microscopic confirmation of distant metastasis
	pM1a	Microscopic confirmation of metastasis confined to liver
	pM1b	Microscopic confirmation of metastases in at least one extrahepatic site (e.g., lung, ovary, nonregional lymph node, peritoneum, bone)
	pM1c	Microscopic confirmation of both hepatic and extrahepatic metastases

Table 2. **AJCC Prognostic Stage Groups**

	T	N	M
Stage I	T1	N0	M0
Stage II	T2, T3	N0	M0
Stage III	T4	N0	M0
	Any T	N1, N2	M0
Stage IV	Any T	Any N	M1

Continued

© 2023, American College of Surgeons, All Rights Reserved. *Used with permission of the American College of Surgeons, Chicago, Illinois. The original source for this information is the AJCC Cancer Staging System.*

Version 3.2025, 10/01/2025 © 2025 National Comprehensive Cancer Network® (NCCN®), All rights reserved. NCCN Guidelines® and this illustration may not be reproduced in any form without the express written permission of NCCN.

PLEASE NOTE that use of this NCCN Content is governed by the End-User License Agreement, and you MAY NOT distribute this Content or use it with any artificial intelligence model or tool.
Printed by Galya Basol Kochav on 1/7/2026 1:55:52 PM. Copyright © 2026 National Comprehensive Cancer Network, Inc. All Rights Reserved.

American Joint Committee on Cancer (AJCC)
TNM Staging System for Well-Differentiated Neuroendocrine Tumors of the Duodenum and Ampulla of Vater (NET G1, G2, and G3) (Version 9, 2023)

***Table 3*. Definitions for T, N, M**

T	**Primary Tumor**
TX	Primary tumor cannot be assessed
T1	Tumor invades the mucosa or submucosa only, and is ≤1 cm in greatest dimension (duodenal tumors); Tumor ≤1 cm in greatest dimension and confined within the sphincter of Oddi (ampullary tumors)
T2	Tumor invades the muscularis propria or is >1 cm in greatest dimension (duodenal tumors); Tumor invades through sphincter into duodenal submucosa or muscularis propria, or is >1 cm in greatest dimension (ampullary tumors)
T3	Tumor invades the pancreas or peripancreatic adipose tissue
T4	Tumor invades the visceral peritoneum (serosa) or other organs

Note: Multiple tumors should be designated as such (the largest tumor should be used to assign T category):
- Use T(#); e.g., pT3(4) N0 M0, or
- Use the *m* suffix, T(m); e.g., pT3(m) N0 M0.

N	**Regional Lymph Nodes**
NX	Regional lymph nodes cannot be assessed
N0	No tumor involvement of regional lymph node(s)
N1	Tumor involvement of regional lymph node(s)

M		**Distant Metastasis**
cM0		No distant metastasis
cM1		Distant metastasis
	cM1a	Metastasis confined to liver
	cM1b	Metastases in at least one extrahepatic site (e.g., lung, ovary, nonregional lymph node, peritoneum, bone)
	cM1c	Both hepatic and extrahepatic metastases
pM1		Microscopic confirmation of distant metastasis
	pM1a	Microscopic confirmation of metastasis confined to liver
	pM1b	Microscopic confirmation of metastases in at least one extrahepatic site (e.g., lung, ovary, nonregional lymph node, peritoneum, bone)
	pM1c	Microscopic confirmation of both hepatic and extrahepatic metastases

***Table 4.* AJCC Prognostic Stage Groups**

	T	N	M
Stage I	T1	NX, N0	M0
Stage II	T2, T3	N0	M0
Stage III	T4	N0	M0
	Any T	N1	M0
Stage IV	Any T	Any N	M1

Continued

© 2023, American College of Surgeons, All Rights Reserved. *Used with permission of the American College of Surgeons, Chicago, Illinois. The original source for this information is the AJCC Cancer Staging System.*

Version 3.2025, 10/01/2025 © 2025 National Comprehensive Cancer Network® (NCCN®), All rights reserved. NCCN Guidelines® and this illustration may not be reproduced in any form without the express written permission of NCCN.

PLEASE NOTE that use of this NCCN Content is governed by the End-User License Agreement, and you MAY NOT distribute this Content or use it with any artificial intelligence model or tool.
Printed by Galya Basol Kochav on 1/7/2026 1:55:52 PM. Copyright © 2026 National Comprehensive Cancer Network, Inc. All Rights Reserved.

American Joint Committee on Cancer (AJCC)
TNM Staging System for Well-Differentiated Neuroendocrine Tumors of the Appendix (NET G1, G2, and G3) (Version 9, 2023)

***Table 5.* Definitions for T, N, M**

T	**Primary Tumor**
TX	Primary tumor cannot be assessed
T0	No evidence of primary tumor
T1	Tumor ≤2 cm in greatest dimension
T2	Tumor >2 cm but ≤4 cm in greatest dimension
T3	Tumor >4 cm in greatest dimension, or with subserosal invasion, or involvement of the mesoappendix
T4	Tumor perforates the peritoneum, or directly invades other adjacent organs or structures (excluding direct mural extension to adjacent subserosa of adjacent bowel), e.g., abdominal wall and skeletal muscle

Note: Multiple tumors should be designated as such (the largest tumor should be used to assign T category):
- Use T(#); e.g., pT3(4) N0 M0, or
- Use the *m* suffix, T(m); e.g., pT3(m) N0 M0.

N	**Regional Lymph Nodes**
NX	Regional lymph nodes cannot be assessed
N0	No tumor involvement of regional lymph node(s)
N1	Tumor involvement of regional lymph node(s)

M		**Distant Metastasis**
cM0		No distant metastasis
cM1		Distant metastasis
	cM1a	Metastasis confined to liver
	cM1b	Metastases in at least one extrahepatic site (e.g., lung, ovary, nonregional lymph node, peritoneum, bone)
	cM1c	Both hepatic and extrahepatic metastases
pM1		Microscopic confirmation of distant metastasis
	pM1a	Microscopic confirmation of metastasis confined to liver
	pM1b	Microscopic confirmation of metastases in at least one extrahepatic site (e.g., lung, ovary, nonregional lymph node, peritoneum, bone)
	pM1c	Microscopic confirmation of both hepatic and extrahepatic metastases

***Table 6.* AJCC Prognostic Stage Groups**

	T	N	M
Stage I	T1	NX, N0	M0
Stage II	T2	NX, N0	M0
	T3	N0	M0
Stage III	T4	N0	M0
	Any T	N1	M0
Stage IV	Any T	Any N	M1

Continued

© 2023, American College of Surgeons, All Rights Reserved. *Used with permission of the American College of Surgeons, Chicago, Illinois. The original source for this information is the AJCC Cancer Staging System.*

Version 3.2025, 10/01/2025 © 2025 National Comprehensive Cancer Network® (NCCN®), All rights reserved. NCCN Guidelines® and this illustration may not be reproduced in any form without the express written permission of NCCN.

PLEASE NOTE that use of this NCCN Content is governed by the End-User License Agreement, and you MAY NOT distribute this Content or use it with any artificial intelligence model or tool.
Printed by Galya Basol Kochav on 1/7/2026 1:55:52 PM. Copyright © 2026 National Comprehensive Cancer Network, Inc. All Rights Reserved.

American Joint Committee on Cancer (AJCC)
TNM Staging System for Well-Differentiated Neuroendocrine Tumors of the Colon and Rectum (NET G1, G2, and G3) (Version 9, 2023)

***Table 7*. Definitions for T, N, M**

T	Primary Tumor
TX	Primary tumor cannot be assessed
T0	No evidence of primary tumor
T1	Tumor invades the mucosa or submucosa, and ≤2 cm in greatest dimension
T1a	Tumor ≤1 cm in greatest dimension
T1b	Tumor >1– but ≤2 cm in greatest dimension
T2	Tumor invades the muscularis propria, or is >2 cm in greatest dimension with invasion of the mucosa or submucosa
T3	Tumor invades through the muscularis propria into subserosal tissue without penetration of overlying serosa
T4	Tumor invades the visceral peritoneum (serosa), or other organs or adjacent structures

Note: Multiple tumors should be designated as such (the largest tumor should be used to assign T category):
- Use T(#); e.g., pT3(4) N0 M0, or
- Use the *m* suffix, T(m); e.g., pT3(m) N0 M0.

N	Regional Lymph Nodes
NX	Regional lymph nodes cannot be assessed
N0	No tumor involvement of regional lymph node(s)
N1	Tumor involvement of regional lymph node(s) metastasis

M		Distant Metastasis
cM0		No distant metastasis
cM1		Distant metastasis
	cM1a	Metastasis confined to liver
	cM1b	Metastases in at least one extrahepatic site (e.g., lung, ovary, nonregional lymph node, peritoneum, bone)
	cM1c	Both hepatic and extrahepatic metastases
pM1		Microscopic confirmation of distant metastasis
	pM1a	Microscopic confirmation of metastasis confined to liver
	pM1b	Microscopic confirmation of metastases in at least one extrahepatic site (e.g., lung, ovary, nonregional lymph node, peritoneum, bone)
	pM1c	Microscopic confirmation of both hepatic and extrahepatic metastases

***Table 8.* AJCC Prognostic Groups**

	T	N	M
Stage I	T1	NX,N0	M0
Stage IIA	T2	N0	M0
Stage IIB	T3	N0	M0
Stage IIIA	T4	N0	M0
Stage IIIB	Any T	N1	M0
Stage IV	Any T	Any N	M1

Continued

© 2023, American College of Surgeons, All Rights Reserved. *Used with permission of the American College of Surgeons, Chicago, Illinois. The original source for this information is the AJCC Cancer Staging System.*

Version 3.2025, 10/01/2025 © 2025 National Comprehensive Cancer Network® (NCCN®), All rights reserved. NCCN Guidelines® and this illustration may not be reproduced in any form without the express written permission of NCCN.

PLEASE NOTE that use of this NCCN Content is governed by the End-User License Agreement, and you MAY NOT distribute this Content or use it with any artificial intelligence model or tool.
Printed by Galya Basol Kochav on 1/7/2026 1:55:52 PM. Copyright © 2026 National Comprehensive Cancer Network, Inc. All Rights Reserved.

American Joint Committee on Cancer (AJCC)
TNM Staging System for Well-Differentiated Neuroendocrine Tumors of the Stomach (NET G1, G2, and G3) (Version 9, 2023)

***Table 9*. Definitions for T, N, M**

T	Primary Tumor
TX	Primary tumor cannot be assessed
T0	No evidence of primary tumor
T1	Tumor invades the mucosa or submucosa, and ≤1 cm in greatest dimension
T2	Tumor invades the muscularis propria or >1 cm in greatest dimension
T3	Tumor invades through the muscularis propria into subserosal tissue without penetration of overlying serosa
T4	Tumor invades visceral peritoneum (serosa) or other organs or adjacent structures

Note: Multiple tumors should be designated as such (the largest tumor should be used to assign T category):
- Use T(#); e.g., pT3(4) N0 M0, or
- Use the *m* suffix, T(m); e.g., pT3(m) N0 M0.

N	Regional Lymph Nodes
NX	Regional lymph nodes cannot be assessed
N0	No tumor involvement of regional lymph node(s)
N1	Tumor involvement of regional lymph node(s)

M		Distant Metastasis
cM0		No distant metastasis
cM1		Distant metastasis
	cM1a	Metastasis confined to liver
	cM1b	Metastases in at least one extrahepatic site (e.g., lung, ovary, nonregional lymph node, peritoneum, bone)
	cM1c	Both hepatic and extrahepatic metastases
pM1		Microscopic confirmation of distant metastasis
	pM1a	Microscopic confirmation of metastasis confined to liver
	pM1b	Microscopic confirmation of metastases in at least one extrahepatic site (e.g., lung, ovary, nonregional lymph node, peritoneum, bone)
	pM1c	Microscopic confirmation of both hepatic and extrahepatic metastases

***Table 10.* AJCC Prognostic Stage Groups**

	T	N	M
Stage I	T1	NX, N0	M0
Stage II	T2, T3	N0	M0
Stage III	T4	N0	M0
	Any T	N1	M0
Stage IV	Any T	Any N	M1

Continued

© 2023, American College of Surgeons, All Rights Reserved. *Used with permission of the American College of Surgeons, Chicago, Illinois. The original source for this information is the AJCC Cancer Staging System.*

Version 3.2025, 10/01/2025 © 2025 National Comprehensive Cancer Network® (NCCN®), All rights reserved. NCCN Guidelines® and this illustration may not be reproduced in any form without the express written permission of NCCN.

PLEASE NOTE that use of this NCCN Content is governed by the End-User License Agreement, and you MAY NOT distribute this Content or use it with any artificial intelligence model or tool.
Printed by Galya Basol Kochav on 1/7/2026 1:55:52 PM. Copyright © 2026 National Comprehensive Cancer Network, Inc. All Rights Reserved.

American Joint Committee on Cancer (AJCC)
TNM Staging System for Lung (Version 9, 2024) [carcinomas of the lung, including non–small cell and small cell carcinomas, and bronchopulmonary carcinoid (neuroendocrine) tumors]

Table 11. **Definitions for T, N, M**

T	Primary Tumor
TX	Primary tumor cannot be assessed. Includes tumors proven by the presence of malignant cells in sputum or bronchial washings but not visualized by imaging or bronchoscopy
T0	No evidence of primary tumor
Tis	Carcinoma *in situ* Squamous cell carcinoma *in situ* (SCIS) Adenocarcinoma *in situ* (AIS): adenocarcinoma with pure lepidic pattern, ≤3 cm in greatest dimension
T1	Tumor ≤3 cm in greatest dimension surrounded by lung or visceral pleura, or in a lobar or more peripheral bronchus
T1mi	Minimally invasive adenocarcinoma: adenocarcinoma (≤3 cm in greatest dimension) with a predominantly lepidic pattern and ≤5 mm invasion in greatest dimension
T1a	Tumor ≤1 cm in greatest dimension OR Tumor of any size whose invasive component is limited to the bronchial wall and may extend proximal to the main bronchus, this is an uncommon superficial, spreading tumor
T1b	Tumor >1 cm but ≤2 cm in greatest dimension
T1c	Tumor >2 cm but ≤3 cm in greatest dimension

Continued

© 2024, American College of Surgeons, All Rights Reserved. *Used with permission of the American College of Surgeons, Chicago, Illinois. The original source for this information is the AJCC Cancer Staging System.*

Version 3.2025, 10/01/2025 © 2025 National Comprehensive Cancer Network® (NCCN®), All rights reserved. NCCN Guidelines® and this illustration may not be reproduced in any form without the express written permission of NCCN.

PLEASE NOTE that use of this NCCN Content is governed by the End-User License Agreement, and you MAY NOT distribute this Content or use it with any artificial intelligence model or tool.
Printed by Galya Basol Kochav on 1/7/2026 1:55:52 PM. Copyright © 2026 National Comprehensive Cancer Network, Inc. All Rights Reserved.

American Joint Committee on Cancer (AJCC)
TNM Staging System for Lung (Version 9, 2024) [carcinomas of the lung, including non–small cell and small cell carcinomas, and bronchopulmonary carcinoid (neuroendocrine) tumors]

Table 11. **Definitions for T, N, M *(continued)***

T	Primary Tumor
T2	Tumor >3 cm but ≤5 cm in greatest dimension OR Tumor ≤4 cm with one or more of the following features: • Invades visceral pleura • Invades an adjacent lobe • Involves main bronchus (up to but not including the carina) or associated with atelectasis or obstructive pneumonitis, extending to the hilar regions, involving either part of or the entire lung
T2a	Tumor >3 cm but ≤4 cm in greatest dimension OR Tumor ≤4 cm in greatest dimension with one or more of the following features: • Invades visceral pleura • Invades an adjacent lobe • Involves main bronchus (up to but not including the carina) or associated with atelectasis or obstructive pneumonitis, extending to the hilar regions, involving either part of or the entire lung
T2b	Tumor >4 cm but ≤5 cm in greatest dimension with or without any of the following features: • Invades visceral pleura • Invades an adjacent lobe • Involves main bronchus (up to but not including the carina) or associated with atelectasis or obstructive pneumonitis, extending to the hilar regions, involving either part of or the entire lung

Continued

© 2024, American College of Surgeons, All Rights Reserved. *Used with permission of the American College of Surgeons, Chicago, Illinois. The original source for this information is the AJCC Cancer Staging System.*

Version 3.2025, 10/01/2025 © 2025 National Comprehensive Cancer Network® (NCCN®), All rights reserved. NCCN Guidelines® and this illustration may not be reproduced in any form without the express written permission of NCCN.

PLEASE NOTE that use of this NCCN Content is governed by the End-User License Agreement, and you MAY NOT distribute this Content or use it with any artificial intelligence model or tool.
Printed by Galya Basol Kochav on 1/7/2026 1:55:52 PM. Copyright © 2026 National Comprehensive Cancer Network, Inc. All Rights Reserved.

American Joint Committee on Cancer (AJCC)
TNM Staging System for Lung (Version 9, 2024) [carcinomas of the lung, including non–small cell and small cell carcinomas, and bronchopulmonary carcinoid (neuroendocrine) tumors]

Table 11. **Definitions for T, N, M *(continued)***

T	Primary Tumor
T3	Tumor >5 cm but ≤7 cm in greatest dimension OR Tumor ≤7 cm with one or more of the following freatures: • Invades parietal pleura or chest wall • Invades pericardium, phrenic nerve or azygos vein Although these structures lie within the mediastinum, the degree of mediastinal penetration by the tumor needed to invade these structures is not counted as T4 • Invades thoracic nerve roots (i.e., T1, T2) or stellate ganglion • Separate tumor nodule(s) in the same lobe as the primary
T4	Tumor >7 cm in greatest dimension OR Tumor of any size with one or more of the following features: • Invades mediastinum (except structures listed in T3), thymus, trachea, carina, recurrent laryngeal nerve, vagus nerve, esophagus or diaphragm • Invades heart, great vessels (aorta, superior/inferior vena cava, intrapericardial pulmonary arteries/veins), supra-aortic arteries or brachiocephalic veins • Invades subclavian vessels, vertebral body, lamina, spinal canal, cervical nerve roots or brachial plexus (i.e., trunks, divisions, cords or terminal nerves) • Separate tumor nodule(s) in different ipsilateral lobe than that of the primary
N	**Regional Lymph Nodes**
NX	Regional lymph nodes cannot be assessed
N0	No tumor involvement of regional lymph node(s)
N1	Tumor involvement of ipsilateral peribronchial and/or ipsilateral hilar and/or ipsilateral intrapulmonary lymph node station(s), including involvement by direct extension
N2	Tumor involvement of ipsilateral mediastinal nodal station(s) and/or subcarinal lymph node station
N2a	Tumor involvement of a single ipsilateral mediastinal nodal station or of the subcarinal nodal station
N2b	Tumor involvement of multiple ipsilateral mediastinal nodal stations with or without involvement of the subcarinal nodal station
N3	Tumor involvement of contralateral mediastinal, contralateral hilar, ipsilateral/contralateral scalene, or ipsilateral/contralateral supraclavicular lymph node station(s)

Continued

© 2024, American College of Surgeons, All Rights Reserved. *Used with permission of the American College of Surgeons, Chicago, Illinois. The original source for this information is the AJCC Cancer Staging System.*

Version 3.2025, 10/01/2025 © 2025 National Comprehensive Cancer Network® (NCCN®), All rights reserved. NCCN Guidelines® and this illustration may not be reproduced in any form without the express written permission of NCCN.

PLEASE NOTE that use of this NCCN Content is governed by the End-User License Agreement, and you MAY NOT distribute this Content or use it with any artificial intelligence model or tool.
Printed by Galya Basol Kochav on 1/7/2026 1:55:52 PM. Copyright © 2026 National Comprehensive Cancer Network, Inc. All Rights Reserved.

American Joint Committee on Cancer (AJCC)
TNM Staging System for Lung (Version 9, 2024) [carcinomas of the lung, including non–small cell and small cell carcinomas, and bronchopulmonary carcinoid (neuroendocrine) tumors]

Table 11. **Definitions for T, N, M** ***(continued)***

M	Distant Metastasis
cMO	No distant metastasis
cM1	Distant metastasis
cM1a	Metastasis in pleural or pericardial nodules, and/or malignant pleural or pericardial effusions, and/or separate tumor nodule(s) in a contralateral lobe Note: Most pleural (pericardial) effusions with lung cancer are a result of the tumor. In a few patients, however, multiple microscopic examinations of pleural (pericardial) fluid are negative for tumor, and the fluid is non-bloody and not an exudate. If these elements and clinical judgment dictate that the effusion is not related to the tumor, the effusion should be excluded as a staging descriptor
cM1b	Single extrathoracic metastasis in a single organ system (including involvement of a single non-regional node)
cM1c	Multiple extrathoracic metastases in a single or multiple organ system(s)
CM1c1	Multiple extrathoracic metastases in a single organ system For example, the skeleton is considered one organ. Several metastases in a single bone or several metastases in several bones are classified as M1c1
cM1c2	Multiple extrathoracic metastases in multiple organ systems
pM1	Microscopic confirmation of distant metastasis
pM1a	Microscopic confirmation of metastasis in pleural or pericardial nodules, and/or malignant pleural or pericardial effusions, and/or separate tumor nodule(s) in a contralateral lobe Note: Most pleural (pericardial) effusions with lung cancer are a result of the tumor. In a few patients, however, multiple microscopic examinations of pleural (pericardial) fluid are negative for tumor, and the fluid is non-bloody and not an exudate. If these elements and clinical judgment dictate that the effusion is not related to the tumor, the effusion should be excluded as a staging descriptor
pM1b	Microscopic confirmation of single extrathoracic metastasis in a single organ system (including involvement of a single non-regional node)
pM1c	Microscopic confirmation of multiple extrathoracic metastases in a single or multiple organ system(s)
pM1c1	Microscopic confirmation of multiple extrathoracic metastases in a single organ system For example, the skeleton is considered one organ. Several metastases in a single bone or several metastases in several bones are classified as M1c1
pM1c2	Microscopic confirmation of multiple extrathoracic metastases in multiple organ systems

Continued

© 2024, American College of Surgeons, All Rights Reserved. *Used with permission of the American College of Surgeons, Chicago, Illinois. The original source for this information is the AJCC Cancer Staging System.*

Version 3.2025, 10/01/2025 © 2025 National Comprehensive Cancer Network® (NCCN®), All rights reserved. NCCN Guidelines® and this illustration may not be reproduced in any form without the express written permission of NCCN.

PLEASE NOTE that use of this NCCN Content is governed by the End-User License Agreement, and you MAY NOT distribute this Content or use it with any artificial intelligence model or tool.
Printed by Galya Basol Kochav on 1/7/2026 1:55:52 PM. Copyright © 2026 National Comprehensive Cancer Network, Inc. All Rights Reserved.

American Joint Committee on Cancer (AJCC)
TNM Staging System for Lung (Version 9, 2024) [carcinomas of the lung, including non–small cell and small cell carcinomas, and bronchopulmonary carcinoid (neuroendocrine) tumors]

Table 12. AJCC Prognostic Stage Groups

	T	N	M
Occult Carcinoma	TX	N0	M0
Stage 0	Tis	N0	M0
Stage IA1	T1mi-T1a	N0	M0
Stage IA2	T1b	N0	M0
Stage IA3	T1c	N0	M0
Stage IB	T2a	N0	M0
Stage IIA	T2b	N0	M0
	T1	N1	M0
Stage IIB	T3	N0	M0
	T1	N2a	M0
	T2a-T2b	N1	M0
Stage IIIA	T4	N0	M0
	T3-T4	N1	M0
	T1	N2b	M0
	T2-T3	N2a	M0
Stage IIIB	T2-T3	N2b	M0
	T4	N2a-N2b	M0
	T1-T2	N3	M0
Stage IIIC	T3-T4	N3	M0
Stage IVA	Any T	Any N	M1a-M1b
Stage IVB	Any T	Any N	M1c1-M1c2

Continued

© 2024, American College of Surgeons, All Rights Reserved. *Used with permission of the American College of Surgeons, Chicago, Illinois. The original source for this information is the AJCC Cancer Staging System.*

Version 3.2025, 10/01/2025 © 2025 National Comprehensive Cancer Network® (NCCN®), All rights reserved. NCCN Guidelines® and this illustration may not be reproduced in any form without the express written permission of NCCN.

PLEASE NOTE that use of this NCCN Content is governed by the End-User License Agreement, and you MAY NOT distribute this Content or use it with any artificial intelligence model or tool.
Printed by Galya Basol Kochav on 1/7/2026 1:55:52 PM. Copyright © 2026 National Comprehensive Cancer Network, Inc. All Rights Reserved.

American Joint Committee on Cancer (AJCC)
TNM Staging System for Thymus (Version 9, 2024) [including thymomas, thymic carcinomas, thymic neuroendocrine neoplasms]

Table 13. **Definitions for T, N, M**

T	**Primary Tumor**
TX	Primary tumor cannot be assessed
T0	No evidence of primary tumor
T1	Tumor limited to the thymus with or without encapsulation, or directly invades into the mediastinal fat only, or directly invades the mediastinal pleura but does not invlove any other mediastinal structure
T1a	Tumor ≤5 cm in greatest dimension with either: • Limited to the thymus with or without encapsulation • Directly invades into the mediastinal fat only • Directly invades the mediastinal pleura but does not involve any other mediastinal structure
T1b	Tumor >5 cm in greatest dimension with either: • Limited to the thymus with or without encapsulation • Directly invades into the mediastinal fat only • Directly invades the mediastinal pleura but does not involve any other mediastinal structure
T2	Tumor with direct invasion of the pericardium (either partial or full thickness), or the lung, or phrenic nerve
T3	Tumor with direct invasion into any of the following: brachiocephalic vein, superior vena cava, chest wall, or extrapericardial pulmonary arteries or veins
T4	Tumor with direct invasion into any of the following: aorta (ascending, arch, or descending), arch vessels, intrapericardial pulmonary artery or veins, myocardium, trachea, esophagus
N	**Regional Lymph Nodes**
NX	Regional lymph nodes cannot be assessed
N0	No tumor involvement of regional lymph node(s)
N1	Tumor involvement of anterior (perithymic) lymph nodes
N2	Tumor involvement of deep intrathoracic or cervical lymph nodes (e.g., paratracheal, subcarinal, aortopulmonary window, hilar, jugular, and/or supraclavicular nodes)

Continued

© 2024, American College of Surgeons, All Rights Reserved. *Used with permission of the American College of Surgeons, Chicago, Illinois. The original source for this information is the AJCC Cancer Staging System.*

Version 3.2025, 10/01/2025 © 2025 National Comprehensive Cancer Network® (NCCN®), All rights reserved. NCCN Guidelines® and this illustration may not be reproduced in any form without the express written permission of NCCN.

PLEASE NOTE that use of this NCCN Content is governed by the End-User License Agreement, and you MAY NOT distribute this Content or use it with any artificial intelligence model or tool.
Printed by Galya Basol Kochav on 1/7/2026 1:55:52 PM. Copyright © 2026 National Comprehensive Cancer Network, Inc. All Rights Reserved.

American Joint Committee on Cancer (AJCC)
TNM Staging System for Thymus (Version 9, 2024) [including thymomas, thymic carcinomas, thymic neuroendocrine neoplasms]

Table 13. **Definitions for T, N, M** ***(continued)***

M	Distant Metastasis
cM0	No distant metastasis
cM1	Distant metastasis
cM1a	Separate pleural or pericardial nodule(s)
cM1b	Pulmonary intraparenchymal nodule or other distant metastasis
pM1	Microscopic confirmation of distant metastasis
pM1a	Microscopic confirmation of separate pleural or pericardial nodule(s)
pM1b	Microscopic confirmation of pulmonary intraparenchymal nodule or other distant metastasis

Table 14. **AJCC Prognostic Stage Groups**

	T	N	M
Stage I	T1a-b	N0	M0
Stage II	T2	N0	M0
Stage IIIA	T3	N0	M0
Stage IIIB	T4	N0	M0
Stage IVA	Any T	N1	M0
	Any T	N0-N1	M1a
Stage IVB	Any T	N2	M0-M1a
	Any T	Any N	M1b

Continued

© 2024, American College of Surgeons, All Rights Reserved. *Used with permission of the American College of Surgeons, Chicago, Illinois. The original source for this information is the AJCC Cancer Staging System.*

Version 3.2025, 10/01/2025 © 2025 National Comprehensive Cancer Network® (NCCN®), All rights reserved. NCCN Guidelines® and this illustration may not be reproduced in any form without the express written permission of NCCN.

PLEASE NOTE that use of this NCCN Content is governed by the End-User License Agreement, and you MAY NOT distribute this Content or use it with any artificial intelligence model or tool.
Printed by Galya Basol Kochav on 1/7/2026 1:55:52 PM. Copyright © 2026 National Comprehensive Cancer Network, Inc. All Rights Reserved.

American Joint Committee on Cancer (AJCC)
TNM Staging System for Well-Differentiated Neuroendocrine Tumors of the Pancreas (NET G1, G2, and G3) (Version 9, 2023)

Table 15. Definitions for T, N, M

T	Primary Tumor
TX	Tumor cannot be assessed
T1	Tumor limited to the pancreas,* ≤2 cm in greatest dimension
T2	Tumor limited to the pancreas,* >2 cm but ≤4 cm in greatest dimension
T3	Tumor limited to the pancreas,* >4 cm in greatest dimension; or tumor invading the duodenum, ampulla of Vater, or common bile duct
T4	Tumor invading adjacent organs (stomach, spleen, colon, adrenal gland) or the wall of large vessels (celiac axis or the superior mesenteric artery/vein, splenic artery/vein, gastroduodenal artery/vein, portal vein)

**Limited to the pancreas* means there is no invasion of adjacent organs (stomach, spleen, colon, adrenal gland) or the wall of large vessels (celiac axis or the superior mesenteric artery). Extension of tumor into peripancreatic adipose tissue is NOT a basis for staging.

Note: Multiple tumors should be designated as such (the largest tumor should be used to assign T category):
- Use T(#); e.g., pT3(4) N0 M0.
- Use the *m* suffix, T(m); e.g., pT3(m) N0 M0.

N	Regional Lymph Nodes
NX	Regional lymph nodes cannot be assessed
N0	No tumor involvement of regional lymph node(s)
N1	Tumor involvement of regional lymph node(s)

M		Distant Metastasis
cM0		No distant metastasis
cM1		Distant metastasis
	cM1a	Metastasis confined to liver
	cM1b	Metastases in at least one extrahepatic site (e.g., lung, ovary, nonregional lymph node, peritoneum, bone)
	cM1c	Both hepatic and extrahepatic metastases
pM1		Microscopic confirmation of distant metastasis
	pM1a	Microscopic confirmation of metastasis confined to liver
	pM1b	Microscopic confirmation of metastases in at least one extrahepatic site (e.g., lung, ovary, nonregional lymph node, peritoneum, bone)
	pM1c	Microscopic confirmation of both hepatic and extrahepatic metastases

***Table 16.* AJCC Prognostic Stage Groups**

	T	N	M
Stage I	T1	N0	M0
Stage II	T2, T3	N0	M0
Stage III	T4	N0	M0
	Any T	N1	M0
Stage IV	Any T	Any N	M1

Continued

© 2023, American College of Surgeons, *Used with permission of the American College of Surgeons, Chicago, Illinois. The original source for this information is the AJCC Cancer Staging System.*

Version 3.2025, 10/01/2025 © 2025 National Comprehensive Cancer Network® (NCCN®), All rights reserved. NCCN Guidelines® and this illustration may not be reproduced in any form without the express written permission of NCCN.

PLEASE NOTE that use of this NCCN Content is governed by the End-User License Agreement, and you MAY NOT distribute this Content or use it with any artificial intelligence model or tool.
Printed by Galya Basol Kochav on 1/7/2026 1:55:52 PM. Copyright © 2026 National Comprehensive Cancer Network, Inc. All Rights Reserved.

American Joint Committee on Cancer (AJCC)
TNM Staging System for Adrenal Cortical Carcinoma (8th ed., 2017)

***Table 17*. Definitions for T, N, M**

T	**Primary Tumor**
TX	Primary tumor cannot be assessed
T0	No evidence of primary tumor
T1	Tumor ≤5 cm in greatest dimension, no extra-adrenal invasion
T2	Tumor >5 cm , no extra-adrenal invasion
T3	Tumor of any size with local invasion but not invading adjacent organs surrounding tissues (e.g., liver, pancreas, spleen, kidneys)
T4	Tumor of any size that invades adjacent organs (kidney, diaphragm, pancreas, spleen, or liver) or large blood vessels (renal vein or vena cava)

N	**Regional Lymph Nodes**
NX	Regional lymph nodes cannot be assessed
N0	No regional lymph node metastasis
N1	Regional lymph node metastasis

M	**Distant Metastasis**
M0	No distant metastasis
M1	Distant metastasis

***Table 18*. AJCC Prognostic Stage Groups**

	T	N	M
Stage I	T1	N0	M0
Stage II	T2	N0	M0
Stage III	T1, T2	N1	M0
	T3, T4	Any N	M0
Stage IV	Any T	Any N	M1

Continued

© 2017, American College of Surgeons, *Used with permission of the American College of Surgeons, Chicago, Illinois. The original source for this information is the AJCC Cancer Staging System.*

Version 3.2025, 10/01/2025 © 2025 National Comprehensive Cancer Network® (NCCN®), All rights reserved. NCCN Guidelines® and this illustration may not be reproduced in any form without the express written permission of NCCN.

PLEASE NOTE that use of this NCCN Content is governed by the End-User License Agreement, and you MAY NOT distribute this Content or use it with any artificial intelligence model or tool.
Printed by Galya Basol Kochav on 1/7/2026 1:55:52 PM. Copyright © 2026 National Comprehensive Cancer Network, Inc. All Rights Reserved.

American Joint Committee on Cancer (AJCC)
TNM Staging System for Adrenal – Neuroendocrine Tumors [Pheochromocytoma and paraganglioma] (8th ed., 2017)

Table 19. **Definitions for T, N, M**

T	**Primary Tumor**
TX	Primary tumor cannot be assessed
T1	PH <5 cm in greatest dimension, no extra-adrenal invasion
T2	PH ≥5 cm or PG-sympathetic of any size, no extra-adrenal invasion
T3	Tumor of any size with local invasion into surrounding tissues (e.g., liver, pancreas, spleen, kidneys)

PH: within adrenal gland
PG Sympathetic: functional
PG Parasympathetic: nonfunctional, usually in the head and neck region
Note: Parasympathetic paraganglioma are not staged because they are largely benign.

N	**Regional Lymph Nodes**
NX	Regional lymph nodes cannot be assessed
N0	No regional lymph node metastasis
N1	Regional lymph node metastasis

M	**Distant Metastasis**
M0	No distant metastasis
M1	Distant metastasis
M1a	Distant metastasis to only bone
M1b	Distant metastasis to only distant lymph nodes/liver or lung
M1c	Distant metastasis to bone plus multiple other sites

Table 20. **AJCC Prognostic Stage Groups**
Pheochromocytoma/Sympathetic Paraganglioma

	T	N	M
Stage I	T1	N0	M0
Stage II	T2	N0	M0
Stage III	T1	N1	M0
	T2	N1	M0
	T3	Any N	M0
Stage IV	Any T	Any N	M1

Continued

© 2017, American College of Surgeons, *Used with permission of the American College of Surgeons, Chicago, Illinois. The original source for this information is the AJCC Cancer Staging System.*

Version 3.2025, 10/01/2025 © 2025 National Comprehensive Cancer Network® (NCCN®), All rights reserved. NCCN Guidelines® and this illustration may not be reproduced in any form without the express written permission of NCCN.

PLEASE NOTE that use of this NCCN Content is governed by the End-User License Agreement, and you MAY NOT distribute this Content or use it with any artificial intelligence model or tool.
Printed by Galya Basol Kochav on 1/7/2026 1:55:52 PM. Copyright © 2026 National Comprehensive Cancer Network, Inc. All Rights Reserved.

American Joint Committee on Cancer (AJCC)
TNM Staging System for Carcinoma (8th ed., 2017)

Table 21. **Definitions for T, N, M**

T	**Primary Tumor**
TX	Primary tumor cannot be assessed
T0	No evidence of primary tumor
T1	Tumor ≤5 cm in greatest dimension, no extra-adrenal invasion
T2	Tumor >5 cm, no extra-adrenal invasion
T3	Tumor of any size with local invasion but not invading adjacent organs
T4	Tumor of any size that invades adjacent organs (kidney, diaphragm, pancreas, spleen, or liver) or large blood vessels (renal vein or vena cava)

N	**Regional Lymph Nodes**
NX	Regional lymph nodes cannot be assessed
N0	No regional lymph node metastasis
N1	Metastasis in regional lymph node(s)

M	**Distant Metastasis**
M0	No distant metastasis
M1	Distant metastasis

G	**Histologic Grade**
LG	Low grade (≤20 mitoses per 50 HPF)
HG	High grade (>20 mitosis per 50 HPF); *TP53* or *CTNNB* mutation

Table 22. **AJCC Prognostic Stage Groups**

	T	**N**	**M**
Stage I	T1	N0	M0
Stage II	T2	N0	M0
Stage III	T1	N1	M0
	T2	N1	M0
	T3	Any N	M0
	T4	Any N	M0
Stage IV	Any T	Any N	M1

Continued

© 2017, American College of Surgeons, *Used with permission of the American College of Surgeons, Chicago, Illinois. The original source for this information is the AJCC Cancer Staging System.*

Version 3.2025, 10/01/2025 © 2025 National Comprehensive Cancer Network® (NCCN®), All rights reserved. NCCN Guidelines® and this illustration may not be reproduced in any form without the express written permission of NCCN.

PLEASE NOTE that use of this NCCN Content is governed by the End-User License Agreement, and you MAY NOT distribute this Content or use it with any artificial intelligence model or tool.
Printed by Galya Basol Kochav on 1/7/2026 1:55:52 PM. Copyright © 2026 National Comprehensive Cancer Network, Inc. All Rights Reserved.

American Joint Committee on Cancer (AJCC)
TNM Staging System for Ampulla of Vater (Version 9, 2023) [applies to all primary carcinomas that arise in the ampulla or on the duodenal papilla, including high-grade neuroendocrine carcinomas such as small cell carcinoma and large cell neuroendocrine carcinoma]

Table 23. **Definitions for T, N, M**

T	**Primary Tumor**
TX	Primary tumor cannot be assessed
T0	No evidence of primary tumor
Tis	Carcinoma *in situ*
T1	Tumor limited to ampulla of Vater or sphincter of Oddi or tumor invades beyond the sphincter of Oddi (perisphincteric invasion) and/or into the duodenal submucosa
T1a	Tumor limited to ampulla of Vater or sphincter of Oddi
T1b	Tumor invades beyond the sphincter of Oddi (perisphincteric invasion) and/or into the duodenal submucosa
T2	Tumor invades into the muscularis propria of the duodenum
T3	Tumor directly invades the pancreas (up to 0.5 cm) or tumor extends more than 0.5 cm into the pancreas, or extends into peripancreatic or periduodenal tissue or duodenal serosa without involvement of the celiac axis or superior mesenteric artery
T3a	Tumor directly invades pancreas (up to 0.5 cm)
T3b	Tumor extends more than 0.5 cm into the pancreas, or extends into peripancreatic tissue or periduodenal tissue or duodenal serosa without involvement of the celiac axis or superior mesenteric artery
T4	Tumor involves the celiac axis, superior mesenteric artery, and/or common hepatic artery, irrespective of size

N	**Regional Lymph Nodes**
NX	Regional lymph nodes cannot be assessed
N0	No regional lymph node metastasis
N1	Metastasis to one to three regional lymph nodes
N2	Metastasis to four or more regional lymph nodes

M	**Distant Metastasis**
M0	No distant metastasis
M1	Distant metastasis

Table 24. **AJCC Prognostic Stage Groups**

	T	N	M
Stage 0	TiS	N0	M0
Stage IA	T1a	N0	M0
Stage IB	T1b, T2	N0	M0
Stage IIA	T3a	N0	M0
Stage IIB	T3b	N0	M0
Stage IIIA	T1a, T1b, T2, T3a, T3b	N1	M0
Stage IIIB	T4	Any N	M0
	Any T	N2	M0
Stage IV	Any T	Any N	M1

© 2023, American College of Surgeons, All Rights Reserved. *Used with permission of the American College of Surgeons, Chicago, Illinois. The original source for this information is the AJCC Cancer Staging System.*

Version 3.2025, 10/01/2025 © 2025 National Comprehensive Cancer Network® (NCCN®), All rights reserved. NCCN Guidelines® and this illustration may not be reproduced in any form without the express written permission of NCCN.

PLEASE NOTE that use of this NCCN Content is governed by the End-User License Agreement, and you MAY NOT distribute this Content or use it with any artificial intelligence model or tool.
Printed by Galya Basol Kochav on 1/7/2026 1:55:52 PM. Copyright © 2026 National Comprehensive Cancer Network, Inc. All Rights Reserved.

ABBREVIATIONS

2SC	2-succinocysteine
4D-CT	four-dimensional computed tomography
ACC	adrenocortical carcinoma
ACTH	adrenocorticotropic hormone
AIS	adenocarcinoma *in situ*
ATA-H	American Thyroid Association high risk
ATA-HST	American Thyroid Association highest risk
ATA-MOD	American Thyroid Association moderate risk
CHD	carcinoid heart disease
COPPS	Composite Pheochromocytoma/ Paraganglioma Prognostic Score
CVD	cyclophosphamide, vincristine, and dacarbazine
DHEA-S	dehydroepiandrosterone sulfate
DIPNECH	diffuse idiopathic pulmonary neuroendocrine cell hyperplasia
dMMR	mismatch repair deficient
EBRT	external beam radiation therapy
ECL	enterochromaffin-like
EGD	esophagogastroduodenoscopy
EUS	endoscopic ultrasound
FDG	fluorodeoxyglucose
FH	fumarate hydratase
FSH	follicle-stimulating hormone
GAPP	Grading of Adrenal Pheochromocytoma and Paraganglioma
GEP	gastroenteropancreatic
GI	gastrointestinal
GIST	gastrointestinal stromal tumor
gNET	gastric neuroendocrine tumor
HSA	high specific activity
H&P	history and physical
HPF	high-power field
HU	Hounsfield unit
IGF-1	insulin-like growth factor 1
IGRT	image-guided radiation therapy
IHC	immunohistochemistry
IMRT	intensity-modulated radiation therapy
LAR	long-acting release
LCNEC	large cell neuroendocrine carcinoma
LH	luteinizing hormone
MAOI	monoamine oxidase inhibitor
MEN1	multiple endocrine neoplasia, type 1
MEN2	multiple endocrine neoplasia, type 2
MIBG	meta-iodobenzylguanidine
MiNEN	mixed neuroendocrine-non-neuroendocrine neoplasm
MMR	mismatch repair
MSI	microsatellite instability
MSI-H	microsatellite instability-high
NEC	neuroendocrine carcinoma
NET	neuroendocrine tumor
NGS	next-generation sequencing
PanNET	pancreatic neuroendocrine tumor
PASS	Pheochromocytoma of the Adrenal gland Scaled Score
PCC	pheochromocytoma
PDNEC	poorly differentiated neuroendocrine carcinoma
PRRT	peptide receptor radionuclide therapy
PTH	parathyroid hormone
PGL	paraganglioma
PPI	proton pump inhibitor

Continued

Version 3.2025, 10/01/2025 © 2025 National Comprehensive Cancer Network® (NCCN®), All rights reserved. NCCN Guidelines® and this illustration may not be reproduced in any form without the express written permission of NCCN.

PLEASE NOTE that use of this NCCN Content is governed by the End-User License Agreement, and you MAY NOT distribute this Content or use it with any artificial intelligence model or tool.
Printed by Galya Basol Kochav on 1/7/2026 1:55:52 PM. Copyright © 2026 National Comprehensive Cancer Network, Inc. All Rights Reserved.

ABBREVIATIONS

SABR	**stereotactic ablative radiotherapy**
SBRT	**stereotactic body radiation therapy**
SCIS	**squamous cell carcinoma *in situ***
SCNEC	**small cell neuroendocrine carcinoma**
SDH	**succinate dehydrogenase**
SDHB	**succinate dehydrogenase complex iron sulfur subunit B**
SPECT	**single-photon emission computed tomography**
SSA	**somatostatin analog**
SSTR	**somatostatin receptor**
TACE	**transarterial chemoembolization**
TAE	**transarterial embolization**
TARE	**transarterial radioembolization**
TMB	**tumor mutational burden**
TMB-H	**tumor mutational burden-high**
TNM	**tumor node metastasis**
TSH	**thyroid-stimulating hormone**
TTE	**transthoracic echocardiogram**
VHL	**von Hippel-Lindau**
VMAT	**volumetric modulated arc therapy**
VUS	**variant of uncertain significance**

Version 3.2025, 10/01/2025 © 2025 National Comprehensive Cancer Network® (NCCN®), All rights reserved. NCCN Guidelines® and this illustration may not be reproduced in any form without the express written permission of NCCN.

PLEASE NOTE that use of this NCCN Content is governed by the End-User License Agreement, and you MAY NOT distribute this Content or use it with any artificial intelligence model or tool.
Printed by Galya Basol Kochav on 1/7/2026 1:55:52 PM. Copyright © 2026 National Comprehensive Cancer Network, Inc. All Rights Reserved.

NCCN Categories of Evidence and Consensus	
Category 1	Based upon high-level evidence (≥1 randomized phase 3 trials or high-quality, robust meta-analyses), there is uniform NCCN consensus (≥85% support of the Panel) that the intervention is appropriate.
Category 2A	Based upon lower-level evidence, there is uniform NCCN consensus (≥85% support of the Panel) that the intervention is appropriate.
Category 2B	Based upon lower-level evidence, there is NCCN consensus (≥50%, but <85% support of the Panel) that the intervention is appropriate.
Category 3	Based upon any level of evidence, there is major NCCN disagreement that the intervention is appropriate.

All recommendations are category 2A unless otherwise indicated.

NCCN Categories of Preference	
Preferred intervention	Interventions that are based on superior efficacy, safety, and evidence; and, when appropriate, affordability.
Other recommended intervention	Other interventions that may be somewhat less efficacious, more toxic, or based on less mature data; or significantly less affordable for similar outcomes.
Useful in certain circumstances	Other interventions that may be used for selected patient populations (defined with recommendation).

All recommendations are considered appropriate.

Version 3.2025, 10/01/2025 © 2025 National Comprehensive Cancer Network® (NCCN®), All rights reserved. NCCN Guidelines® and this illustration may not be reproduced in any form without the express written permission of NCCN.

PLEASE NOTE that use of this NCCN Content is governed by the End-User License Agreement, and you MAY NOT distribute this Content or use it with any artificial intelligence model or tool.
Printed by Galya Basol Kochav on 1/7/2026 1:55:52 PM. Copyright © 2026 National Comprehensive Cancer Network, Inc. All Rights Reserved.

Discussion

This discussion section corresponds to the NCCN Guidelines for Neuroendocrine and Adrenal Tumors. Last updated: October 1, 2025.

Table of Contents

Overview **MS-2**

Guidelines Update Methodology **MS-3**

Literature Search Criteria **MS-3**

Sensitive/Inclusive Language Usage **MS-3**

Histologic Classification and Staging of Neuroendocrine and Adrenal Tumors **MS-4**

- Histologic Classification MS-4
- Staging MS-5
- Pathologic Reporting MS-6
- Other Potential Prognostic Markers MS-6

Principles of Hereditary Cancer Risk Assessment and Genetic Counseling **MS-7**

Sporadic Neuroendocrine Tumors **MS-7**

- Neuroendocrine Tumors of the Gastrointestinal Tract (Well-Differentiated Grade 1/2), Lung, and Thymus MS-7
- Neuroendocrine Tumors of the Pancreas (Well-Differentiated Grade 1/2) MS-22
- Locoregional Therapies for Advanced Neuroendocrine Tumors of the Gastrointestinal Tract and Pancreas (Well-Differentiated Grade 1/2) and Lung/Thymus MS-33
- Liver Transplantation Considered Investigational for Liver Metastases of Neuroendocrine Tumors of the Gastrointestinal Tract and Pancreas (Well-Differentiated Grade 1/2) MS-34
- Neuroendocrine Tumors Neoplasms of Unknown Primary MS-34
- Well-Differentiated Grade 3 Neuroendocrine Tumors MS-35
- Extrapulmonary Poorly Differentiated: Neuroendocrine Carcinoma/Large or Small Cell Carcinoma/Mixed Neuroendocrine-Non-Neuroendocrine Neoplasm MS-39
- Adrenal Gland Tumors MS-41
- Pheochromocytomas/Paragangliomas MS-46

Multiple Endocrine Neoplasia **MS-51**

- MEN1 ..... MS-52
- MEN2 and Familial MTC MS-55

Future Trial Design **MS-58**

References **MS-59**

Version 3.2025 © 2025 National Comprehensive Cancer Network© (NCCN©), All rights reserved. NCCN Guidelines® and this illustration may not be reproduced in any form without the express written permission of NCCN.

PLEASE NOTE that use of this NCCN Content is governed by the End-User License Agreement, and you MAY NOT distribute this Content or use it with any artificial intelligence model or tool.
Printed by Galya Basol Kochav on 1/7/2026 1:55:52 PM. Copyright © 2026 National Comprehensive Cancer Network, Inc. All Rights Reserved.

Overview

Well-differentiated neuroendocrine tumors (NETs) are thought to arise from cells throughout the diffuse endocrine system. They comprise a broad family of tumors, the most common of which are in the gastrointestinal (GI) tract, lungs and bronchi (so-called bronchopulmonary), thymus, and pancreas. Sites of origin within the GI tract include the stomach, small intestine, appendix, and rectum.[1,2] Other NETs include those arising in the thyroid, adrenal, and pituitary glands. NETs are part of a broader group of neuroendocrine neoplasms (NENs), which include poorly differentiated neuroendocrine carcinomas (PDNECs), as well as mixed neuroendocrine-non-NENs (MiNENs).[3,4]

An analysis of the SEER database estimated that the incidence of NETs in the United States was 6.9 cases per 100,000 people from 2000 to 2021.[5] This analysis suggested that the age-adjusted incidence of NENs increased by a factor of 5.2 between 1975 and 2021, and that the 20-year forecasted prevalence of individuals with NENs was 243,896 on January 1, 2021. Another study of the SEER database found a 6.4-fold increase in the incidence rate of gastroenteropancreatic NETs (GEP-NETs) over a 40-year period (1975–2015) in the United States.[6] The reasons for this increase are unclear, although it seems likely that improved diagnosis and classification is one factor.[7]

Most NETs seem to be sporadic and risk factors for sporadic NETs are poorly understood. NETs may also arise in the context of inherited genetic syndromes, including multiple endocrine neoplasia types 1 (MEN1), 2 (MEN2), and 4 (MEN4), and *SDHx* mutations. NETs have also been associated with other conditions, including von Hippel-Lindau (VHL) disease, tuberous sclerosis complex, and neurofibromatosis.[8,9] MEN1, associated with mutations in the menin gene, is characterized by multiple tumors of the parathyroid, pituitary, and pancreatic glands.[10] MEN2, associated with mutations in the *RET* proto-oncogene, is characterized by the development of medullary thyroid cancer, pheochromocytoma (PCC) (often bilateral), and hyperparathyroidism.[11]

Patients with NETs can have symptoms attributable to hormonal hypersecretion. These symptoms include intermittent flushing and diarrhea in patients with GI NETs,[12] bronchospasm and wheezing in lung NETs,[12] hypertension in patients with PCC or paraganglioma (PGL),[13] and symptoms attributable to secretion of insulin, glucagon, gastrin, and other peptides in patients with pancreatic NETs (PanNETs).[14] Patients with hormonal symptoms are considered to have “functional” tumors, and those without symptoms are considered to have “nonfunctional” tumors.

Appropriate diagnosis and treatment of NETs often involves collaboration between specialists in multiple disciplines, using specific biochemical, radiologic, and surgical methods. Specialists include pathologists, endocrinologists, radiologists (including nuclear medicine specialists), and medical, radiation, and surgical oncologists.

PCCs are neoplasms of the chromaffin cells of the adrenal medulla in 80% to 90% of cases. Ectopic/extra-adrenal PCCs that arise from sympathetic and para-aortic sympathetic ganglia are called PGLs.[15,16] PCCs and PGLs occur in 0.05% to 0.1% of hypertensive patients, and their combined annual incidence in the United States is estimated to be between 500 and 1600 cases.[17] Approximately 10% to 15% of PCCs and PGLs are malignant, but it could be up to 40%.[18,19] PCCs release catecholamines (epinephrine and norepinephrine) and their metabolites metanephrine and normetanephrine, resulting in hypertension, arrhythmia, and/or hyperglycemia. About 40% of PGLs secrete catecholamines. Head and neck PGLs only secrete catecholamines about 5% of the time and often it is dopamine.

Adrenocortical carcinomas (ACCs) are rare tumors that originate in the adrenal glands (incidence, 0.7–2 per million).[20,21] ACC has a bimodal age

Version 3.2025 © 2025 National Comprehensive Cancer Network© (NCCN©), All rights reserved. NCCN Guidelines® and this illustration may not be reproduced in any form without the express written permission of NCCN.

PLEASE NOTE that use of this NCCN Content is governed by the End-User License Agreement, and you MAY NOT distribute this Content or use it with any artificial intelligence model or tool.
Printed by Galya Basol Kochav on 1/7/2026 1:55:52 PM. Copyright © 2026 National Comprehensive Cancer Network, Inc. All Rights Reserved.

distribution, with peak incidences in early childhood and the fourth to fifth decades of life. Females are more frequently affected (55%–60%).[20,22] Most cases are sporadic; however, ACCs have been observed in association with several hereditary syndromes, including Li-Fraumeni syndrome, Lynch syndrome, Beckwith-Wiedemann syndrome, MEN1, and familial adenomatous polyposis.[10,23-28] The underlying mechanisms of carcinogenesis in sporadic ACCs have not been fully elucidated; however, inactivating somatic mutations of the *p53* tumor suppressor gene (chromosome 17p13[29,30]) and alterations at the 11p15 locus (site of the *IGF2* gene[31,32]) seem to occur frequently.

These guidelines discuss the diagnosis and management of both sporadic and hereditary neuroendocrine and adrenal tumors and are intended to assist with clinical decision-making. Most of the guideline sections pertain to well-differentiated, low- to intermediate-grade tumors, although well-differentiated high-grade tumors and extrapulmonary PDNECs/large or small cell carcinomas/MiNENs are also addressed (see *Extrapulmonary Poorly Differentiated: Neuroendocrine Carcinoma/Large or Small Cell Carcinoma/Mixed Neuroendocrine-Non-Neuroendocrine Neoplasm*, below). Medical practitioners should note that unusual patient scenarios (presenting in <5% of patients) are not specifically discussed in these guidelines.

Guidelines Update Methodology

The complete details of the Development and Update of the NCCN Clinical Practice Guidelines in Oncology (NCCN Guidelines®) are available at www.NCCN.org.

Literature Search Criteria

Prior to the update of the NCCN Guidelines® for Neuroendocrine and Adrenal Tumors, an electronic search of the PubMed database was performed to obtain key literature in neuroendocrine and adrenal tumors since the previous Guidelines update, using the following search terms: neuroendocrine tumor OR adrenal cancer OR carcinoid OR pheochromocytoma OR paraganglioma OR Multiple Endocrine Neoplasia. The PubMed database was chosen as it remains the most widely used resource for medical literature and indexes peer-reviewed biomedical literature.[33]

The search results were narrowed by selecting studies in humans published in English. Results were confined to the following article types: Clinical Trial, Phase II; Clinical Trial, Phase III; Clinical Trial, Phase IV; Guideline; Practice Guideline; Randomized Controlled Trial; Meta-Analysis; Multicenter Studies; Systematic Reviews; and Validation Studies. The data from key PubMed articles as well as articles from additional sources deemed as relevant to these guidelines as discussed by the Panel during the Guidelines update have been included in this version of the Discussion section. Recommendations for which high-level evidence is lacking are based on the Panel's review of lower-level evidence and expert opinion.

Sensitive/Inclusive Language Usage

NCCN Guidelines strive to use language that advances the goals of equity, inclusion, and representation.[34] NCCN Guidelines endeavor to use language that is person-first; not stigmatizing; anti-racist, anti-classist, anti-misogynist, anti-ageist, anti-ableist, and anti-weight biased; and inclusive of individuals of all sexual orientations and gender identities. NCCN Guidelines incorporate non-gendered language, instead focusing on organ-specific recommendations. This language is both more accurate and more inclusive and can help fully address the needs of individuals of all sexual orientations and gender identities. NCCN Guidelines will continue to use the terms men, women, female, and male when citing statistics, recommendations, or data from organizations or sources that do not use inclusive terms. Most studies do not report how sex and gender

Version 3.2025 © 2025 National Comprehensive Cancer Network© (NCCN©), All rights reserved. NCCN Guidelines® and this illustration may not be reproduced in any form without the express written permission of NCCN.

PLEASE NOTE that use of this NCCN Content is governed by the End-User License Agreement, and you MAY NOT distribute this Content or use it with any artificial intelligence model or tool.
Printed by Galya Basol Kochav on 1/7/2026 1:55:52 PM. Copyright © 2026 National Comprehensive Cancer Network, Inc. All Rights Reserved.

data are collected and use these terms interchangeably or inconsistently. If sources do not differentiate gender from sex assigned at birth or organs present, the information is presumed to predominantly represent cisgender individuals. NCCN encourages researchers to collect more specific data in future studies and organizations to use more inclusive and accurate language in their future analyses.

Histologic Classification and Staging of Neuroendocrine and Adrenal Tumors

NENs are generally subclassified by site of origin, stage, and histologic characteristics (eg, differentiation and grade/proliferation rate).

Histologic Classification

NENs are divided into NETs and neuroendocrine carcinomas (NECs). The 2019 World Health Organization (WHO) classification of NENs included significant updates, including harmonizing the classification of GI and pancreatic NENs.[14] NETs are all well-differentiated while NECs are poorly differentiated neoplasms. Well-differentiated NETs are further classified into three categories: low-grade (G1), intermediate-grade (G2), and high-grade (G3) based on proliferation rate. All PDNECs are G3 but not all G3 NENs are poorly differentiated. Some tumors can have mixed, both well and poorly differentiated, histology and are termed MiNENs. The 2022 WHO update offered additional refinements, largely around the emerging use of immunohistochemical or molecular markers to facilitate classification in GI and pancreatic NENs.[4]

Tumor differentiation and tumor grade often correlate with mitotic count and Ki-67 proliferation index. In fact, most commonly used histologic classification schemes, including the European Neuroendocrine Tumor Society (ENETS), WHO systems, and the International Agency for Research on Cancer, incorporate mitotic rate and Ki-67 index for GI NETs and PanNETs.[14,35-39] Numerous studies have confirmed that increased mitotic rate and high Ki-67 index are associated with a more aggressive clinical course and worse prognosis.[40-43] In GI NETs and PanNETs, well-differentiated, low-grade tumors (G1) have a mitotic count of <2/10 high-power field (HPF) and/or a Ki-67 index of <3%. Well-differentiated, intermediate-grade tumors (G2) have a mitotic count of 2 to 20/10 HPF and/or a Ki-67 index of 3% to 20%. In high-grade well-differentiated tumors (G3), the mitotic count exceeds 20/10 HPF and/or the Ki-67 index exceeds 20%.

When both mitotic count and Ki-67 index are available and discordant, the higher value determines the grade classification.[44-46] Ki-67 immunohistochemistry should be analyzed and/or counted in the areas of highest activity referred to as “hot spots.” A key recommendation is that tumor differentiation, as well as Ki-67 index and/or mitotic rate, should be included in the pathology report. Ki-67 index is preferred over mitotic rate, unless there is insufficient tissue. Doing so allows the treating physician to factor these data into the clinical picture to make appropriate treatment decisions in GI NETs and PanNETs. Poorly differentiated NECs are automatically considered high grade (G3) and are often subtyped as large cell NEC, small cell NEC, and/or mixed histology (MiNENs).[14]

The classification of lung and thymus NETs varies from that of GEP-NETs in some classification systems, and in particular does not include Ki-67 index and includes the assessment of necrosis.[47] Well-differentiated NETs of the lung and thymus are classified as either typical carcinoid (<2 mitoses/2 mm^2, and no necrosis) or atypical carcinoid (2–10 mitoses/2 mm^2, and/or foci of necrosis), using histologic criteria.[47,48]

High-grade, poorly differentiated lung and thymus NECs are of either small cell or large cell cytology, with >10 mitoses/2 mm^2 and extensive foci of necrosis.[48] However, necrosis is not a feature of thymus small cell carcinoma.

Version 3.2025 © 2025 National Comprehensive Cancer Network© (NCCN©), All rights reserved. NCCN Guidelines® and this illustration may not be reproduced in any form without the express written permission of NCCN.

PLEASE NOTE that use of this NCCN Content is governed by the End-User License Agreement, and you MAY NOT distribute this Content or use it with any artificial intelligence model or tool.
Printed by Galya Basol Kochav on 1/7/2026 1:55:52 PM. Copyright © 2026 National Comprehensive Cancer Network, Inc. All Rights Reserved.

Considerable debate remains as to the most appropriate Ki-67 proliferative threshold for the determination of tumor grade and consequent treatment decisions.[49,50] A retrospective database review of 252 patients with high-grade GI NEC suggested that platinum-based chemotherapy is most active in those with a Ki-67 index of ≥55%.[51] These results suggest that a higher Ki-67 cutoff than is currently recommended may be more appropriate to classify tumors as high grade. Conversely, for low-grade tumors, some studies have suggested that the currently accepted cutoff may be too low. An analysis of data from 274 patients with PanNETs found that a 5% Ki-67 cutoff (rather than 2%) was the optimal prognostic indicator.[52] A comparable analysis based on 691 patients with jejunal-ileocecal NETs similarly found that a threshold of 5 mitoses/10 HPF provided better prognostic information than one of 2 mitoses/10 HPF.[53]

See *Principles of Pathology for the Diagnosis of Adrenocortical Carcinoma* and the *Principles of Pathology for the Diagnosis of Pheochromocytoma/Paraganglioma* in the algorithm for information about ACC and PCC/PGL.

Staging

NETs are staged according to the AJCC tumor (T), node (N), metastasis (M) staging system. The AJCC introduced its first TNM staging system for the classification of NETs in its 7th edition of the AJCC Cancer Staging Manual.[54] The T and N definitions and other staging definitions were revised in the 8th edition of the AJCC Cancer Staging Manual.[55] The 8th edition also added the first staging system for thymic tumors and adrenal NETs (including staging for PCC and PGL).[55] The T, N, and M definitions for NETs of the GI tract and pancreas were updated in version 9 of the AJCC Cancer Staging System.[56-62] NETs of the stomach, duodenum/ampulla, jejunum/ileum, appendix, colon/rectum, and pancreas have separate staging systems. The association of tumor stage with prognosis has been confirmed in analyses of the SEER database and the National Cancer Database.[63-69] An analysis of 691 patients with jejunal-ileocecal NETs treated at the Moffitt Cancer Center between 2000 and 2010 revealed 5-year survival rates of 100%, 100%, 91%, and 72% for stages I through IV, respectively, further validating the TNM staging system.[53] Of note, however, this analysis also suggested that, unlike other malignancies, primary tumor size and depth of invasion had little bearing on survival in early-stage disease.[50] Similar results were reported in a separate analysis of 6792 small intestine NETs in the SEER database, which found that outcomes were similar for patients with T1 and T2 tumors.[70]

The TNM staging system for the classification of PanNETs was first separated from exocrine pancreatic carcinoma in the 8th edition of the AJCC Cancer Staging Manual.[54,55] The primary tumor (T) is differentiated based on size and involvement of major vessels or other organs (see *Staging* in the algorithm). A retrospective analysis of 425 patients with PanNETs treated at the Moffitt Cancer Center between 1999 and 2010 validated the AJCC 2017 classification system, with 5-year overall survival (OS) rates of 92%, 84%, 81%, and 57% for stages I through IV, respectively ($P < .001$).[71] Although the trends of this analysis are consistent with population-based studies, the survival rates from this analysis were significantly higher than those seen in population-based studies.[72,73] For example, in the SEER database analysis of PanNETs, the 5-year survival rate for patients with metastatic disease was only 19.5%.[73] Taken together, the presence of lymph node and distant metastases have the strongest affect on survival in PanNETs.[74,75]

NETs of the lungs and bronchi are staged in the same manner as more common lung carcinomas. As in lung carcinoma, more advanced tumor stage for NETs of the lungs and bronchi is associated with worse prognosis.[54,55]

Version 3.2025 © 2025 National Comprehensive Cancer Network© (NCCN©), All rights reserved. NCCN Guidelines® and this illustration may not be reproduced in any form without the express written permission of NCCN.

Importantly, extrapulmonary NECs (including MiNENs) arising in any site are staged according to the organ-specific criteria for their non-neuroendocrine carcinoma counterparts (eg, adenocarcinoma or squamous carcinoma).[76]

Pathologic Reporting

In addition to information on histologic classification and stage, the margin status (positive or negative) and the presence of vascular or perineural invasion should be included in the pathology report; some studies have suggested that these factors may also have prognostic significance.[77,78] See *Principles of Pathology for the Diagnosis of Neuroendocrine Neoplasms* in the algorithm for additional information about required information for the pathology report.

Whether or not tumors are associated with symptoms of hormone hypersecretion (”functioning” or “non-functioning”) is a clinical rather than histologic diagnosis. The presence of hormone-staining granules without a clinical syndrome does not make a tumor “functioning.” Thus, functional status is usually not included in the pathology report. The Panel defines nonfunctioning NENs as those without symptoms secondary to hormone production whether or not hormone levels are elevated.

Other Potential Prognostic Markers

Chromogranin A is a secreted protein that is often elevated in patients with NETs; elevated levels have been associated with poorer prognosis.[79] However, routine use for monitoring disease has waned given challenges related to reproducibility across laboratories, and the impact of medications (eg, proton pump inhibitors [PPIs]) and comorbidities (eg, renal insufficiency) on lab values.[80,81] The NETest is a blood-based biomarker test that measures the expression level of multiple analytes.[82] It can help in the identification of small bowel, pancreas, and bronchopulmonary NENs, as well as PCCs and PGLs. The NETest demonstrated high sensitivity (>95%) in patients with well-differentiated, metastatic NETs[83] and may help predict for recurrence post-resection.[84-88] The peptide receptor radionuclide therapy (PRRT) predictive quotient (PPQ) assay is a related blood-based assay that integrates neuroendocrine gene transcripts with tumor Ki-67 index values to identify patients with tumors that are predicted to respond to PRRT.[89] Validation studies are ongoing, but neither biomarker has been incorporated into routine care yet.

The molecular basis of NETs remains poorly understood, and additional molecular predictors of outcome remain investigational. One study found that overexpression of mammalian target of rapamycin (mTOR) or its downstream targets was associated with shorter OS in 195 neuroendocrine tissue samples (15% were located in the pancreas; 85% were GI carcinoids).[90] Small bowel carcinoid (neuroendocrine) tumors have been found to have recurrent mutations in the cyclin-dependent kinase inhibitor, *CDKN1B* (p27),[91] and loss of CDKN1B expression has been reported to be an adverse prognostic factor in GEP-NETs.[92] Circulating tumor cells (CTCs) have also been studied as possible prognostic markers, based on the idea that tumor cells in the blood would be indicative of more disseminated disease. Another study found that the presence of ≥1 CTC in 7.5 mL of blood was independently associated with worse progression-free survival (PFS) and OS in patients with varyingly pretreated metastatic NETs from various primary sites.[93]

Additional research related to molecular assays is ongoing. A multinational consensus meeting of experts concluded that, to date, no single currently available biomarker is sufficient as a diagnostic, prognostic, or predictive marker in patients with NETs.[94] That said, tumor mutation profiling is increasingly routine for high-grade NENs, to some extent to assist with tumor classification, but also to identify actionable mutations.

Version 3.2025 © 2025 National Comprehensive Cancer Network© (NCCN©), All rights reserved. NCCN Guidelines® and this illustration may not be reproduced in any form without the express written permission of NCCN.

PLEASE NOTE that use of this NCCN Content is governed by the End-User License Agreement, and you MAY NOT distribute this Content or use it with any artificial intelligence model or tool.
Printed by Galya Basol Kochav on 1/7/2026 1:55:52 PM. Copyright © 2026 National Comprehensive Cancer Network, Inc. All Rights Reserved.

Principles of Hereditary Cancer Risk Assessment and Genetic Counseling

Recommendations are provided regarding pre-test counseling, considerations when determining the most appropriate testing strategy, post-test counseling, and criteria for genetic risk evaluation and genetic testing for hereditary endocrine neoplasia syndromes (see *Principles of Hereditary Cancer Risk Assessment and Genetic Counseling* in the algorithm).

Genetic risk evaluation and genetic testing for hereditary endocrine neoplasia syndromes are recommended in patients with any of the following: 1) ACC; 2) PCC/PGL; 3) parathyroid adenoma or primary hyperparathyroidism before age 30, multiple parathyroid adenomas, multigland hyperplasia (without obvious secondary causes), or recurrent primary hyperparathyroidism; 4) clinical suspicion for MEN2 due to the presence of medullary thyroid carcinoma (MTC) or other combination of MEN2-related features; 5) a mutation identified on tumor genomic testing that has clinical implications if also identified in the germline (eg, tumor analysis shows a mutation in *BRCA1/2* or mismatch repair [MMR] gene); 6) a close blood relative with a known pathogenic variant/likely pathogenic variant in a cancer susceptibility gene; 7) a first-degree relative meeting one of the above criteria but not available for testing; and 8) clinical suspicion for MEN1 due to ≥2 of the following, or 1 of the following and a family history of ≥1 of the following: primary hyperparathyroidism, duodenal NET/PanNET, pituitary adenoma, or foregut carcinoid (bronchial, thymic, or gastric). In addition, genetic risk evaluation and genetic testing should be considered for patients meeting any of the following criteria: 1) gastrinoma (duodenal/pancreatic or type 2 gastric NET [gNET]); 2) multifocal PanNETs[95]; 3) duodenal NET or PanNET at any age; and 4) other combinations of tumors or cancers in the patient and/or their family members. Data from two relatively small cohorts of patients with PanNETs suggest pathogenic mutations are present in 16% to 21% of patients.[95-97]

Sporadic Neuroendocrine Tumors

Neuroendocrine Tumors of the Gastrointestinal Tract (Well-Differentiated Grade 1/2), Lung, and Thymus

Approximately one-third of neuroendocrine (carcinoid) tumors arise in the lungs or thymus, and two-thirds arise in the GI tract. Sites of origin within the GI tract include the stomach, small intestine, appendix, and rectum.[1,2] The prognosis for patients with NETs varies according to the stage at diagnosis, histologic classification, and primary site of the tumor (see *Histologic Classification and Staging of Neuroendocrine and Adrenal Tumors*, above).

NETs of the GI tract, lung, or thymus may secrete various hormones and vasoactive peptides. Bronchial and thymic NETs have been associated with adrenocorticotropic hormone (ACTH) production and are a cause of Cushing syndrome.[98,99] NETs arising in the small intestine or appendix are more commonly associated with carcinoid syndrome, related to the secretion of serotonin, histamine, or tachykinins into the systemic circulation causing episodic flushing and diarrhea.[100] Approximately 50% to 66% of patients with carcinoid syndrome develop valvular cardiac complications consisting of tricuspid regurgitation and/or pulmonary stenosis.[101]

The metabolic products released by intestinal NETs are rapidly destroyed by liver enzymes in the portal circulation. Thus, the classical syndrome, occurring in approximately 8% to 28% of patients with NETs,[102,103] is not usually observed unless liver metastases or rarely retroperitoneal disease have occurred, in which case hepatic metastases release metabolic products directly into the systemic circulation via the hepatic veins.

These guidelines address seven major subtypes of NETs of the GI tract, lung, and thymus: 1) jejunal/ileal/colon, 2) duodenal, 3) appendix, 4) rectal, 5) gastric, 6) lung, and 7) thymus.

Version 3.2025 © 2025 National Comprehensive Cancer Network© (NCCN©), All rights reserved. NCCN Guidelines® and this illustration may not be reproduced in any form without the express written permission of NCCN.

PLEASE NOTE that use of this NCCN Content is governed by the End-User License Agreement, and you MAY NOT distribute this Content or use it with any artificial intelligence model or tool.
Printed by Galya Basol Kochav on 1/7/2026 1:55:52 PM. Copyright © 2026 National Comprehensive Cancer Network, Inc. All Rights Reserved.

Evaluation of Neuroendocrine Tumors of the Gastrointestinal Tract (Well-Differentiated Grade 1/2), Lung, and Thymus

Patients who present with suspected NETs of the GI tract, lung, or thymus should be evaluated with imaging studies to assess disease burden and possible primary location. Commonly used techniques include CT and MRI. NETs of the GI tract, lung, and thymus are highly vascular and can appear isodense with liver on conventional CT scan, depending on contrast phase. Multiphase CT or MRI scans with contrast should therefore be used for evaluation of liver metastasis. Chest CT scans with or without contrast are also recommended as appropriate to assess for lung metastases.

Because most NETs overexpress high-affinity receptors for somatostatin,[100,104] a peptide hormone generated by the hypothalamus that blocks the release of growth hormones,[105] somatostatin receptor (SSTR)-based imaging is often considered in the initial evaluation of patients with NETs but is recommended particularly in patients with jejunal/ileal/colon NETs. Such imaging can provide useful information on overall tumor burden and location; additionally, positive imaging confirms the presence of SSTRs, which can have therapeutic implications and assist with staging.

A major advance in SSTR-based imaging NETs came with the 2016 FDA approval of PET/CT imaging using the radiolabeled somatostatin analog (SSA) gallium-68 (68Ga)-DOTATATE. Several studies have shown the diagnostic utility, safety, specificity, and high sensitivity of 68Ga-DOTATATE PET/CT.[106-110] A systematic review and meta-analysis of 22 studies determined that 68Ga-DOTATATE had a pooled sensitivity and specificity of 91% and 94%, respectively, for the initial diagnosis of NETs.[111] One study even showed that it was able to more correctly identify patients for peptide receptor radiotherapy than indium 111 diethylenetriamine pentaacetic acid (In-111 DPTA) scintigraphy.[112] The 2018 Appropriate Use Criteria for Somatostatin Receptor PET Imaging in NETs recommends the use of SSTR PET over In-111 DPTA scintigraphy.[106-108,113] Unless otherwise indicated, the preferred SSTR-based imaging in this discussion includes SSTR-PET/CT or SSTR-PET/MRI imaging using 68Ga-DOTATATE, 64Cu-DOTATATE, or 68Ga-DOTATOC. SSTR scintigraphy using In-111 octreotide (with single-photon emission CT [SPECT]/CT) is appropriate only if SSTR-PET is not available as SSTR-PET imaging is more sensitive than SSTR scintigraphy for determining SSTR status. Data are limited on whether long-acting SSTR inhibition interferes with 68Ga-DOTATATE PET/CT scans, but one study[114] showed that timing does not make a difference. The Panel notes that for jejunal/ileal/colon NETs, SSTR-PET/CT or SSTR-PET/MRI should not be used to limit the extent of lymphadenectomy or small bowel resection as sensitivity may not be adequate.

Additional imaging recommendations vary by disease site and include as appropriate: colonoscopy for ileal and colon NETs; esophagogastroduodenoscopy (EGD) and/or endoscopic ultrasound (EUS) for duodenal and certain gNETs; endorectal ultrasound for rectal NETs; and bronchoscopy and brain MRI for lung NETs.

Biochemical evaluation can also be helpful in the initial diagnostic evaluation, particularly in patients with NETs who have clinical symptoms that are suggestive of hormone hypersecretion (most common in patients with primary tumors of the small bowel). Evaluation of serotonin secretion, using a 24-hour urine or plasma collection for 5-hydroxyindoleacetic acid (5-HIAA), is generally recommended in patients with metastatic lung or GI NETs with symptoms consistent with carcinoid syndrome, manifested by symptoms of flushing and diarrhea. Symptoms from excess production of insulin, gastrin, vasointestinal peptide, or other hormones also sometimes occur.[12,14] Screening for hormones in asymptomatic individuals is not routinely recommended, with the exception that baseline 5-HIAA should

Version 3.2025 © 2025 National Comprehensive Cancer Network© (NCCN©), All rights reserved. NCCN Guidelines® and this illustration may not be reproduced in any form without the express written permission of NCCN.

be considered in asymptomatic patients with jejunal/ileal/colon NETs with a high burden of metastatic disease.

Chromogranin A is sometimes used as a biochemical marker in non-functioning tumors. Whereas one meta-analysis calculated the sensitivity and specificity of chromogranin A to be 73% and 95%, respectively, for diagnosis of NETs,[115] others have questioned its value. Chromogranin A is elevated in patients with renal or hepatic impairment and in patients receiving PPIs, and in general should not be relied upon in isolation as a diagnostic test as it lacks specificity and test values can fluctuate, which can lead to false-positive results.[116,117] Unlike chromogranin A, the NETest scores are not impacted by the use of PPIs.[82] However, the Panel did not include NETest in the algorithm pending formal validation studies.

Genetic counseling and testing for inherited genetic syndromes should be considered for patients with lung or thymic NETs. A biochemical workup for hypercortisolemia (Cushing syndrome) [discussed in *Evaluation and Treatment of Hypercortisolemia (± Cushing Syndrome)*, below] and carcinoid syndrome may also be indicated in patients with lung or thymic NETs if signs and symptoms of hypercortisolemia are suspected. If hypercortisolemia (Cushing syndrome) is suspected, assess for and treat ectopic sources of ACTH production. Details of the evaluation and diagnosis of a patient with Cushing syndrome from a bronchial NET have been published.[118]

Management of Locoregional Neuroendocrine Tumors of the Gastrointestinal Tract (Well-Differentiated Grade 1/2), Lung, and Thymus

The management of locoregional NETs of the GI tract, lung, and thymus depends on tumor size, primary site, and the general condition of the patient. Resection is the first-line treatment approach for most localized NETs of the GI tract, lung, and thymus. Although symptoms of hormone hypersecretion are more common in patients with metastatic disease, for patients with locoregional disease and symptoms of hormone hypersecretion, symptom control with octreotide long-acting release (LAR) or lanreotide is paramount. Octreotide LAR and lanreotide are also recommended for tumor control in certain patients with unresectable locoregional disease [see *Management of Locoregional Advanced Disease and/or Distant Metastases of the Gastrointestinal Tract (Well-Differentiated Grade 1/2 Neuroendocrine Tumors)* and *Control of Tumor Growth in the Setting of Locoregional Unresectable Disease or Distant Metastatic Lung or Thymic Neuroendocrine Tumors (Atypical and Typical Carcinoid Tumors)*, below]. Specific recommendations for management of NET subtypes are described herein.

Neuroendocrine Tumors of the Duodenum, Small Intestine, and Colon

For non-functioning, localized lesions arising in the duodenum, endoscopic resection, transduodenal local excision with regional lymphadenectomy, or pancreatoduodenectomy are other options for first-line treatment of non-metastatic duodenal NETs. For lesions >1 cm, a multidisciplinary approach is recommended. For non-ampullary tumors, endoscopic or local excision is preferred. Pancreatoduodenectomy should be considered for ampullary tumors of any size not amenable to endoscopic or local excision. If endoscopic resection is performed, follow-up EGD should be performed as appropriate.

For patients presenting with tumors in the jejunum, ileum, or colon, surgical resection(s) of the bowel with regional lymphadenectomy is recommended. The surgical procedure should include careful examination of the entire bowel, because multiple synchronous lesions may be present. In addition, the proximity to or involvement of the superior mesenteric artery and superior mesenteric vein should be assessed during surgery.

Appendiceal Neuroendocrine Tumors

Most appendiceal NETs are identified incidentally, during appendectomy performed for appendicitis. Most appendiceal NETs have

Version 3.2025 © 2025 National Comprehensive Cancer Network© (NCCN©), All rights reserved. NCCN Guidelines® and this illustration may not be reproduced in any form without the express written permission of NCCN.

PLEASE NOTE that use of this NCCN Content is governed by the End-User License Agreement, and you MAY NOT distribute this Content or use it with any artificial intelligence model or tool.
Printed by Galya Basol Kochav on 1/7/2026 1:55:52 PM. Copyright © 2026 National Comprehensive Cancer Network, Inc. All Rights Reserved.

well-differentiated histology, and for most appendiceal tumors ≤2 cm, simple appendectomy is sufficient because metastases are uncommon.[119,120]

However, some controversy exists regarding the management of appendiceal NETs measuring <2 cm with more aggressive histologic features. Some NCCN Member Institutions thus consider right hemicolectomy for 1- to 2-cm tumors with poor prognostic features, such as lymphovascular or mesoappendiceal invasion or atypical histologic features. In a retrospective case series that included 79 patients with appendiceal carcinoid (neuroendocrine) tumors, small-vessel invasion was a risk factor for metastases in patients with tumors <2 cm.[121]

Patients with tumors >2 cm, or any tumor size with an incomplete resection or positive nodes/margins, are at significant risk for locoregional or distant metastases. These patients should be staged with multiphasic abdomen/pelvis CT or MRI scans with intravenous (IV) contrast. SSTR-based imaging may be considered and if no distant disease is identified, a right hemicolectomy should be considered. Results from a systematic review and meta-analysis with 261 patients suggest that a right hemicolectomy was beneficial in appendiceal NETs >2 cm.[122] Additionally, a small proportion of appendiceal NETs may also contain evidence of adenocarcinoma (ie, “adenocarcinoid” or “goblet cell carcinoid”). These tumors should be managed according to the NCCN Guidelines for Colon Cancer (available at www.NCCN.org).

Neuroendocrine Tumors of the Rectum

An analysis of the SEER database revealed that patients with NET tumors of the rectum had the best prognosis (hazard ratio [HR], 1.87; 95% CI, 1.76–1.98).[123] The treatment of rectal lesions is based on the size of the primary tumor. For small (<1 cm) incidental lesions, complete endoscopic resection with negative margins may be sufficient, but for resection with indeterminate margins and low grade (G1), endoscopy at 6 to 12 months is recommended to assess for residual disease. If endoscopy results determine residual disease or intermediate grade after endoscopy, or if the small incidental tumors have indeterminate margins and intermediate grade (G2), the pathway for all other rectal tumors should be followed. All other rectal lesions should be staged using rectal MRI or endorectal ultrasound. If the lesion is ≤2 cm or minimally invasive (T1), endoscopic or transanal excision is recommended. Given the higher risk of invasion with larger tumors, examination under anesthesia and/or EUS with radical resection if there is invasion of the muscularis propria or node positivity should be considered for tumors 1 to 2 cm in size before the procedure. A retrospective review found that metastases were present in 66% of 87 patients with well-differentiated rectal NETs of 11 to 19 mm.[124]

Tumors >2 cm or that are node positive, those with invasion of the muscularis propria (T2–T4), or those associated with lymph node metastases should be treated with low anterior resection or, in rare cases, an abdominoperineal resection.[125] There may be a role for neoadjuvant or definitive chemoradiation in selected cases.[126]

Gastric Neuroendocrine Tumors

There are four types of gNETs: type 1 (associated with chronic atrophic gastritis or high gastric pH); type 2 (associated with antrum-sparing type A Zollinger-Ellison syndrome); type 3 (sporadic and unifocal)[127]; and “other.” A SEER-based analysis of 3523 patients with gastric NENs found a 5-year OS rate of 53.7%.[128] Types 1 and 2 gNETs are both associated with hypergastrinemia and are typically multifocal. The major difference between them is that patients with type 1 gNETs generally have antrum-sparing atrophic gastritis with a loss of the usual negative feedback loop on the gastrin-producing cells of the antrum by acid (relatively high gastric pH), resulting in hypergastrinemia and excess stimulation of the endocrine cells of the fundus, and patients with type 2 gNETs have evidence of acid

Version 3.2025 © 2025 National Comprehensive Cancer Network© (NCCN©), All rights reserved. NCCN Guidelines® and this illustration may not be reproduced in any form without the express written permission of NCCN.

hypersecretion (low gastric pH) secondary to gastrinoma (Zollinger-Ellison syndrome).[127] Type 1 gNETs demonstrate an indolent course, with a rate of metastases of <5%. Evidence suggestive of type 1 disease includes a histologic diagnosis of atrophic gastritis on gastric biopsy, elevated gastric pH, vitamin B12 deficiency, and positive anti-intrinsic factor antibodies (not all tests need to be done to make a diagnosis). For rare type 1 tumors that are >2 cm, the workup should include multiphasic abdomen CT or MRI performed with contrast. Type 2 tumors are rare and occur in the setting of gastrinoma in which elevated gastrin levels produce gastric neuroendocrine hyperplasia and multifocal gNETs.

Endoscopic resection of tumors >1 cm is recommended for patients with locoregional hypergastrinemic/type 1 gNETs. For hypergastrinemic/type 2 gNETs, endoscopic resection of gastric tumors >1 cm is recommended and physicians should follow the recommendations for gastrinoma for the identification and treatment of the gastrin-producing tumor.

Patients with non-metastatic unifocal gNETs and normal gastrin levels (type 3) often have more aggressive tumors and are usually treated with partial or total gastrectomy, based on tumor location, with regional lymphadenectomy (preferred).[129] For early-stage, smaller type 3 tumors, endoscopic[130] or wedge resection can be considered if there is no evidence of regional lymphadenopathy on EUS or other imaging.[131] Endoscopic resection should be reserved for small (<1 cm), superficial, low-grade tumors.

For the emerging category of “other” gNETs, there is increasing evidence that patients who have been on long-term PPI therapy may be at an increased risk of developing gNETs, which appear to have a much lower propensity to metastasize than sporadic type 3 tumors.[132,133] PPI-associated tumors are challenging to diagnose as they can be associated with either normal or elevated gastrin levels.

Lung and Thymic Neuroendocrine Tumors

The 5-year survival rate of thymic NETs is 62%.[134] Localized (stage I–II) and locoregional (stage III A/B) NETs in the thymus are generally treated with surgical resection without adjuvant therapy if they have been completely resected with negative margins.

NETs arising in the lung or bronchus account for 30.6% of NETs.[123] Surgery, including lobectomy or other anatomic resection and mediastinal node dissection or sampling, is recommended for patients with stage I, II, and IIIA lung tumors. If surgery is contraindicated, thermal ablation or stereotactic body radiation therapy (SBRT) is recommended for those with stage I–II disease. If surgery is feasible and the disease is stage I, II, or low-grade IIIA, patients may be monitored post-resection under surveillance procedures as described [see *Surveillance of Resected Well-Differentiated Grade 1/2 Neuroendocrine Tumors of the Gastrointestinal Tract, Lung, and Thymus*, below].

Surveillance of Resected Well-Differentiated Grade 1/2 Neuroendocrine Tumors of the Gastrointestinal Tract, Lung, and Thymus

Surveillance of resected GI, lung, and thymic NETs should include complete patient history and physical (H&P) examination, imaging, and biochemical markers as clinically indicated. For those with resected lung or thymic NETs, surveillance CT imaging of the chest and abdomen is recommended (with pelvic imaging as clinically indicated). In patients with resected GI NETs, multiphasic abdomen, with or without pelvis, CT or an MRI scan is recommended (with chest imaging as clinically indicated). Most patients with resected NETs of the jejunum/ileum/colon; duodenum, rectum, lung, and thymus; and type 3 gNETs with normal gastrin levels should be reevaluated 12 weeks to 12 months after resection (earlier if the patient is symptomatic). After 1-year post-resection, follow-up should occur every 12 to 24 months for up to 10 years post-resection. After 10

Version 3.2025 © 2025 National Comprehensive Cancer Network© (NCCN©), All rights reserved. NCCN Guidelines® and this illustration may not be reproduced in any form without the express written permission of NCCN.

years, surveillance should be considered as clinically indicated. If initial scans are negative, the frequency of follow-up scans may decrease.

For functional tumors, the Panel recommends a follow-up with biochemical markers as clinically indicated. 5-HIAA, a metabolite of serotonin, in a 24-hour urine or plasma sample may also be considered as a biochemical marker in some cases, particularly in patients with metastatic small-intestinal NETs. A systematic review and meta-analysis revealed a predictive role of urinary 5-HIAA for mortality.[135] During monitoring of patients after treatment of a NET, decreasing levels of 5-HIAA indicate a response to treatment, whereas increasing or excessive concentration indicates that the treatment has not been successful. However, a patient with symptoms may still have a NET even if the concentration of 5-HIAA is normal. Diet and a variety of drugs can affect the 5-HIAA test. Therefore, patients should be advised not to eat avocados, bananas, cantaloupe, eggplant, pineapples, plums, tomatoes, hickory nuts/pecans, plantains, kiwi, dates, grapefruit, honeydew, or walnuts for 48 hours before the start of and during urine collection. Medications that can increase 5-HIAA include acetaminophen, ephedrine, diazepam, nicotine, glyceryl guaiacolate (an ingredient found in some cough medicines), and phenobarbital.

SSTR-based imaging or 18F-fluorodeoxyglucose (FDG)-PET/CT scans are not routinely recommended for surveillance after definitive resection, but may be indicated to assess disease location and disease burden for comparison in cases of subsequent possible recurrence.

In specific cases, follow-up recommendations for patients with resected GI NETs differ from the above general recommendations. For noninvasive duodenal nonfunctioning NETs, endoscopic surveillance is recommended every 3 to 12 months for the first year, and then annually thereafter. Routine endoscopic surveillance is recommended for noninvasive duodenal gastrinomas. For rectal tumors <1 cm and negative margins, prognosis is excellent and no follow-up is usually required. Follow-up endoscopies with rectal MRI or endorectal ultrasound are recommended for rectal tumors that are between 1 and 2 cm, 6 and 12 months after first-line therapy, and then as clinically indicated.

For appendiceal tumors <1 cm, no surveillance is indicated. For tumors ≥1 cm to ≤2 cm,[136,137] the Panel recommends optional multiphasic imaging with contrast as surveillance every 2 to 5 years based on clinicopathologic features. Several studies have suggested a nontrivial risk of nodal metastases in tumors <2 cm.[138-142] Patients with small, well-differentiated appendiceal NETs are at very low risk for recurrence.[143-145] In the setting of appendiceal NETs >2 cm, multiphasic CT or MRI of the abdomen with or without pelvis is recommended (with chest imaging as clinically indicated) 12 weeks to 12 months post-resection and every 12 to 24 months thereafter for 10 years.

For patients with hypergastrinemic/type 1 gNETs, follow-up EGD is recommended at 1 year and then every 1 to 3 years thereafter. For patients with hypergastrinemic/type 2 gNETs, follow-up EGD is recommended at 1 year and then as clinically indicated for patients who underwent endoscopic resection. Because gastrin levels remain persistently high in patients with atrophic gastritis, gastrin levels are generally uninformative in patients with type 1 gNETs. After baseline gastrin, the Panel does not recommend following gastrin and chromogranin A levels for type 1 tumors.

Evaluation of Locoregional Advanced Disease and/or Distant Metastatic Gastrointestinal Tract (Well-Differentiated Grade 1/2), Lung, and Thymic Neuroendocrine Tumors

Imaging recommendations for patients suspected to have distant metastatic disease include multiphase technique CT or MRI at baseline and assessment of disease progression.[146,147] The most common sites of metastases from intestinal NETs include regional/mesenteric lymph

Version 3.2025 © 2025 National Comprehensive Cancer Network© (NCCN©), All rights reserved. NCCN Guidelines® and this illustration may not be reproduced in any form without the express written permission of NCCN.

PLEASE NOTE that use of this NCCN Content is governed by the End-User License Agreement, and you MAY NOT distribute this Content or use it with any artificial intelligence model or tool.
Printed by Galya Basol Kochav on 1/7/2026 1:55:52 PM. Copyright © 2026 National Comprehensive Cancer Network, Inc. All Rights Reserved.

nodes, liver, and bones. When evaluating locoregional advanced and/or metastatic NETs of the GI tract, lung, and thymus, or for suspected carcinoid syndrome, multiphasic abdomen/pelvis CT or MRI scans with IV contrast are recommended. Chest CT scans with or without contrast are recommended as clinically indicated (without contrast is acceptable when evaluating for metastases from primary tumors in other sites).

SSTR-based imaging, if not already done, is recommended to assess the baseline SSTR status of locoregional advanced and/or metastatic NETs of the GI tract, lung, or thymus. SSTR-based imaging should be repeated at the time of progressive disease on cross-sectional imaging. Additional indications for periodic SSTR imaging may include monitoring of patients with bone-predominant disease and establishing a new baseline after completion of PRRT.

If carcinoid syndrome is suspected, a baseline echocardiogram is recommended, along with a cardiology consultation if carcinoid heart disease (CHD) is present. The transthoracic echocardiogram should include morphologic evaluation of the valves (especially tricuspid and pulmonary) and a comprehensive assessment of the right heart size and function using two-dimensional color-flow and continuous wave Doppler assessment, and two-dimensional and color-flow assessment of the atrial septum with an agitated saline injection if valve disease is present to determine whether there is an atrial level shunt.[148-150] The comprehensive assessment of the right-sided valves has two components: 1) tricuspid valve assessment using parasternal inflow, short axis, and apical 4-chamber views; and 2) pulmonary valve assessment using parasternal outflow, short axis, and apical or subcoastal outflow views. Following valve replacement, patients should be followed with serial echocardiograms according to institutional practice. If the valves are abnormal by echocardiogram, consider the potential for clots requiring resumption of anticoagulants versus recurrent CHD. See *Principles of Imaging* in the algorithm for recommendations for repeat transthoracic echocardiogram for patients with NETs.

Twenty-four-hour urine or plasma 5-HIAA may also be considered, and then repeated over time to monitor subsequent disease progression. As previously mentioned, if carcinoid syndrome is suspected, evaluation of serotonin secretion, using a 24-hour urine or plasma collection for 5-HIAA, is recommended. Lung and thymic tumors may also be associated with hypersecretion of ACTH that causes the development of Cushing syndrome;[151] therefore, if clinically indicated, patients should be screened for Cushing syndrome. If Cushing syndrome is suspected, see discussion below [see *Evaluation and Treatment of Hypercortisolemia (± Cushing Syndrome)*, below]. Tumor/somatic molecular profiling should be considered for patients with lung/thymic NETs (atypical carcinoids) with locoregional unresectable/metastatic disease who are candidates for anticancer therapy to identify actionable alterations. Testing on tumor tissue is preferred; however, liquid biopsy can be considered if tumor testing is not feasible.

Management of Locoregional Advanced Disease and/or Distant Metastases of the Gastrointestinal Tract (Well-Differentiated Grade 1/2 Neuroendocrine Tumors)

Surgical Treatment of Resectable Disease

In some cases, patients with limited hepatic metastases or other sites of disease can undergo surgical cytoreduction of the primary tumor and metastases. If surgical cytoreduction of metastases is possible, surgical treatment of the primary and distant disease is recommended. If complete surgical cytoreduction of metastases is not possible, the Panel recommends consideration of resection for the primary tumor and regional lymph node to reduce future obstruction, mesenteric ischemia, bleeding, or perforation, particularly if the patient is symptomatic; and/or octreotide LAR or lanreotide. Observation with serial imaging is an option if the

Version 3.2025 © 2025 National Comprehensive Cancer Network© (NCCN©), All rights reserved. NCCN Guidelines® and this illustration may not be reproduced in any form without the express written permission of NCCN.

patient has a low tumor burden. If the patient has clinically significant tumor burden, an alternative front-line therapy may be used. In select cases, it may be appropriate to proceed to front-line systemic therapy or locoregional therapy prior to or concurrently with octreotide LAR or lanreotide. A retrospective study did not find a survival improvement of resecting asymptomatic primary small bowel tumors.[152] However, it is not uncommon for patients with small bowel primary tumors to experience symptoms of intermittent abdominal pain from episodic bowel obstruction or bowel ischemia related to the primary tumor and surrounding fibrosis. Palliative small bowel resection is recommended in these patients. Noncurative debulking surgery can also be considered in select cases, especially if the patient is symptomatic either from tumor bulk or hormone production.

In a long-term follow-up of 546 patients with well-differentiated NET (mostly small intestine and pancreas) liver metastases treated with cytoreductive hepatectomy from 2000 to 2020, the median OS and median PFS were 122 months and 17 months, respectively.[153] One multi-institutional analysis reported an improvement in the median (not reached vs. 87 months; $P < .001$) and 5-year survival (85.2% vs. 60.7%; $P < .001$) of patients with neuroendocrine liver metastases who underwent an R0/R1 resection compared to those who underwent a debulking R2 procedure.[154] Primary tumors were in the pancreas, small intestine, and large intestine. Ninety-six percent of patients reported symptom relief (median symptom-free interval, 41 months). In another study, the median OS and PFS were 89.4 months and 22.5 months, respectively, in patients with GEP-NETs with liver metastases who underwent hepatic cytoreductive procedures.[155] The authors report that >70% cytoreduction resulted in improved outcomes in terms of OS and PFS. In another study that used a liver debulking threshold of 70% in patients with NETs, the median PFS was 72 months and the disease-specific survival was 90%.[156]

If resection is performed and long-term treatment with SSAs is anticipated, a prophylactic cholecystectomy can be considered given the association between long-term treatment with SSAs and the development of biliary symptoms and gallstones.[157]

Control of Tumor Growth in the Setting of Locally Advanced/Unresectable Disease (Well-Differentiated Grade 1/2 Neuroendocrine Tumors of the Gastrointestinal Tract)

For patients with locoregional advanced disease and/or distant metastases of the GI tract with clinically significant disease progression, cabozantinib (category 1 if prior treatment with everolimus or lutetium Lu 177 dotatate), everolimus (category 1 for nonfunctional tumors), PRRT with lutetium Lu 177 dotatate (if SSTR-positive and progression on octreotide LAR/lanreotide) (category 1 for progressive midgut tumors), octreotide LAR, and lanreotide are preferred regimens. Above-label dose octreotide LAR or lanreotide (for SSTR-positive disease and progression on standard SSA doses), consideration of radiation therapy (RT) with or without concurrent fluoropyrimidine-based chemotherapy for locally advanced unresectable disease (excluding small bowel mesenteric), and consideration of the cytotoxic chemotherapy regimens discussed below (category 3) are useful in certain circumstances. These therapies can also be used as alternative front-line therapies for patients with clinically significant tumor burden if surgical cytoreduction of metastases is not possible. First-line PRRT with lutetium Lu 177 dotatate (if SSTR-positive, Ki-67 ≥10%, and clinically significant tumor burden) is also a preferred alternative front-line systemic therapy.

Somatostatin Analogs (Well-Differentiated Grade 1/2 Neuroendocrine Tumors of the Gastrointestinal Tract)

In patients with GI tract primary tumors who have clinically significant tumor burden or progressive disease, initiation of either octreotide LAR or lanreotide is recommended to potentially control tumor growth. Treatment

Version 3.2025 © 2025 National Comprehensive Cancer Network© (NCCN©), All rights reserved. NCCN Guidelines® and this illustration may not be reproduced in any form without the express written permission of NCCN.

with octreotide LAR or lanreotide will likely be of greatest benefit in patients with SSTR-positive tumors. The recommendation for octreotide LAR in these patients is based on the results of the PROMID study, a placebo-controlled phase III trial of 85 patients with metastatic midgut NETs (proliferative index, Ki-67, ≤2%), which showed median times to tumor progression of 14.3 and 6 months in the octreotide LAR and placebo groups, respectively (P = .000072).[158] After 6 months of treatment, stable disease was observed in 66.7% of patients in the octreotide LAR group and in 37.2% of patients in the placebo group. Results of long-term survival of patients in the PROMID study found that median OS was not significantly different between the arms (83.7 months in the placebo arm and 84.7 months in the octreotide arm; HR, 0.83; 95% CI, 0.44–1.46; P = .51).[159] However, post-study treatment included octreotide LAR in 38 of 43 patients in the placebo arm, possibly confounding interpretation of long-term survival results.

The recommendation for lanreotide for control of tumor growth in patients with clinically significant tumor burden or progressive disease is based on results of the CLARINET study. The CLARINET study randomized 204 patients with locally advanced or metastatic nonfunctioning pancreatic or intestinal NETs (proliferative index, Ki-67, ≤10%) to receive either lanreotide or placebo and followed patients for PFS. Results from this trial showed that treatment with lanreotide for 2 years resulted in an improvement in PFS over placebo (PFS, not reached vs. 18 months; HR, 0.47; 95% CI, 0.30–0.73; P < .001).[160] Subsequent data from a pre-planned interim analysis of the open-label extension of the CLARINET study estimated PFS in patients treated with lanreotide at 32.8 months (95% CI, 30.9–68.0).[161] The difference in the reported median PFS between the PROMID and CLARINET studies is likely explained by a difference in the study populations, as the majority of the patients enrolled in the CLARINET trial had stable disease in the 3 to 6 months before randomization.[160]

Higher (above-label) doses of SSAs may also have activity in patients with progression on standard doses. The phase II CLARINET FORTE study, which enrolled patients with locally advanced or metastatic grade 1/2 midgut NETs or PanNETs with progression on lanreotide (120 mg every 28 days), demonstrated that a reduction in the dosing interval was feasible.[162] The median PFS was 8.3 months (95% CI, 5.6–11.1) in patients with midgut NETs treated with lanreotide at a dose of 120 mg every 14 days for up to 96 weeks. The long-term efficacy and safety of lanreotide was demonstrated in a 48-week phase II trial with Japanese patients with NETs.[163] Stable disease was observed in 71.4% of patients while progressive disease was observed in 21.4% of patients. Patients in the control arms of the NETTER-1 and NETTER-2 trials received high-dose octreotide LAR (60 mg every 4 weeks).[164-166] In the NETTER-1 trial, the estimated rate of PFS at 20 months was 65.2%, with a response rate of 3% and a median OS of 36.3 months in patients with advanced SSTR-positive midgut NETs treated with octreotide LAR.[164,165] In the NETTER-2 trial, the median PFS was 8.5 months in patients with well-differentiated grade 2–3 SSTR-positive GEP-NETs treated with first-line high-dose octreotide LAR.[166]

If injection site-related complications occur, consider switching to another SSA. After clinical, symptomatic, or radiographic progression on standard SSA doses, for symptom and/or tumor control, above-label dosing octreotide LAR (up to 60 mg once a month) or lanreotide (up to 120 mg every 14 days) may be useful in select cases.[162,165,166]

Everolimus (Well-Differentiated Grade 1/2 Neuroendocrine Tumors of the Gastrointestinal Tract)

For patients with GI NETs with clinically significant disease progression, everolimus (category 1 for nonfunctional GI NETs) is a recommended treatment option. However, the effectiveness of everolimus in the treatment of patients with carcinoid syndrome has not been established.

Version 3.2025 © 2025 National Comprehensive Cancer Network© (NCCN©), All rights reserved. NCCN Guidelines® and this illustration may not be reproduced in any form without the express written permission of NCCN.

PLEASE NOTE that use of this NCCN Content is governed by the End-User License Agreement, and you MAY NOT distribute this Content or use it with any artificial intelligence model or tool.
Printed by Galya Basol Kochav on 1/7/2026 1:55:52 PM. Copyright © 2026 National Comprehensive Cancer Network, Inc. All Rights Reserved.

Everolimus is an inhibitor of mTOR and was well tolerated and showed evidence of antitumor effect in patients with advanced NETs when given with octreotide LAR in a phase II trial.[167] In the randomized phase III RADIANT-2 trial, 429 patients with advanced NETs and carcinoid syndrome were randomized to receive octreotide LAR with everolimus or placebo.[168] Based on central review, patients receiving octreotide plus everolimus had a median PFS of 16.4 months, compared with 11.3 months for patients receiving octreotide alone (P = .026). This difference in the primary endpoint of PFS did not, however, meet the predefined threshold for statistical significance. An open-label extension of the RADIANT-2 trial allowed patients who had progressed or completed the double-blind core phase to take everolimus plus octreotide LAR. The median OS was not statistically different for patients receiving everolimus plus octreotide LAR (29.2 months) or placebo plus octreotide LAR (during the open-label extension; 35.2 months) at the final cutoff date.[169] Adverse events associated with everolimus included stomatitis, rash, fatigue, and diarrhea.[168,169] Other side effects have also been described.[170-172]

A subsequent trial, RADIANT-4, was an international, double-blind, placebo-controlled, phase 3 trial that randomized 302 patients with progressive, non-functional lung or GI NETs 2:1 to receive everolimus or placebo.[173] In contrast to RADIANT-2, patients in RADIANT-4 were not receiving an SSA at the time of study enrollment and concurrent SSA was not a study requirement. Median PFS was 11.0 months (95% CI, 9.2–13.3) in the everolimus arm and 3.9 months (95% CI, 3.6–7.4) in the placebo arm. The HR for progression or death was 0.48 (95% CI, 0.35–0.67; P < .001). Drug-related grade 3/4 adverse events included stomatitis (9% vs. 0%), infections (7% vs. 0%), diarrhea (7% vs. 2%), anemia (4% vs. 1%), fatigue (3% vs. 1%), and hyperglycemia (3% vs. 0%). A real-world report highlights the outcomes of 169 pretreated patients with advanced NETs of the pancreas (n = 85) or other sites (n = 84) who received everolimus through a compassionate use program.[174] An increased risk of adverse events in patients who had received previous radiolabeled peptide therapy or chemotherapy was noted. An exploratory analysis of a subgroup of patients with advanced, progressive, well-differentiated, non-functional lung NETs from RADIANT-4 reported improved PFS by central review (HR, 0.50; 95% CI, 0.28–0.88) in the everolimus arm (9.2 months) compared to the placebo arm (3.6 months).[175] Additionally, a secondary endpoint analysis of RADIANT-4 found that health-related quality-of-life (QOL) outcomes were maintained in patients receiving everolimus and placebo, with no significant difference between them.[176]

Cabozantinib (Well-Differentiated Grade 1/2 Neuroendocrine Tumors of the Gastrointestinal Tract)

Cabozantinib (category 1 if prior treatment with everolimus or lutetium Lu 177 dotatate) is an option for patients with GI NETs, having demonstrated efficacy in the phase III CABINET trial in patients with progressive, well-differentiated, locally advanced or metastatic pancreatic or extrapancreatic NETs.[177] Patients were randomized 2:1 to receive cabozantinib or placebo. In the extrapancreatic cohort, the median PFS was 8.4 months in the cabozantinib arm and 3.9 months in the placebo arm (stratified HR for progression or death, 0.38; 95% CI, 0.25–0.59; P < .001). Patients who received cabozantinib had an overall response rate (ORR) of 5% (vs. 0% with placebo) and a median OS of 21.9 months (vs. 19.7 months with placebo; HR, 0.86). Sixty-two percent of patients in the cabozantinib arm had a grade 3–5 adverse event possibly related to treatment, compared to 27% of patients in the placebo arm. Cabozantinib was approved for PanNETs and extrapancreatic NETs in 2025.

Cytotoxic Chemotherapy (Well-Differentiated Grade 1/2 Neuroendocrine Tumors of the Gastrointestinal Tract)

Version 3.2025 © 2025 National Comprehensive Cancer Network© (NCCN©), All rights reserved. NCCN Guidelines® and this illustration may not be reproduced in any form without the express written permission of NCCN.

PLEASE NOTE that use of this NCCN Content is governed by the End-User License Agreement, and you MAY NOT distribute this Content or use it with any artificial intelligence model or tool.
Printed by Galya Basol Kochav on 1/7/2026 1:55:52 PM. Copyright © 2026 National Comprehensive Cancer Network, Inc. All Rights Reserved.

The benefits associated with cytotoxic chemotherapy in patients with advanced GI NETs appear, at best, to be modest. Tumor response rates are generally low, and no PFS benefit has been clearly demonstrated.[178]

Capecitabine was tested in patients with metastatic NETs in a phase II trial; no objective responses were reported, although 13 of 19 patients were reported to have experienced stable disease.[179] Treatment with FOLFOX resulted in a partial response (PR) rate of 12.5% in patients with advanced small intestine NETs, 14% in those with advanced gNETs, and 17% in those with advanced rectal NETs.[180] Responses to temozolomide in advanced GI NETs are rare.[181]

A phase II trial assessed bevacizumab plus capecitabine and included 49 patients with advanced and/or metastatic GI NETs.[182] A PFS of 23.4 months was reported, with 18% of patients achieving a PR and 70% achieving stable disease. Similar results were seen in two small trials of FOLFOX (fluorouracil, leucovorin, and oxaliplatin) and CAPEOX (capecitabine and oxaliplatin) combined with bevacizumab where a PFS of 19.3 months and 16.7 months, respectively, was reported.[183] However, these findings have not been confirmed in phase III studies.

The Panel lists cytotoxic chemotherapy (namely 5-FU, capecitabine, dacarbazine, oxaliplatin, and temozolomide) for progressive NETs of the GI tract as a category 3 recommendation. While some panelists believe the toxicity of systemic therapy does not warrant its widespread use in this population, others believe that it is an important alternative for patients without other options for treatment.

Radiolabeled Somatostatin Analogs (Well-Differentiated Grade 1/2 Neuroendocrine Tumors of the Gastrointestinal Tract)

Several early studies initially reported that treatment with radiolabeled SSAs was associated with tumor responses in patients with advanced NETs.[184-188] A prospective phase II study of radiopeptide therapy in 90 patients with metastatic NETs refractory to octreotide showed that treatment was associated with improvement in symptoms; radiographic regression, however, was relatively uncommon.[189] Numerous large, non-randomized cohort analyses have also reported encouraging survival rates with this approach.[190-192]

The phase III NETTER-1 study randomized 229 patients with advanced midgut NETs to receive treatment with either lutetium Lu 177 dotatate with octreotide LAR or high-dose octreotide. Results of this study showed that treatment with lutetium Lu 177 dotatate was associated with a significant improvement in PFS (not reached vs. 8.4 months; $P < .0001$).[164] Objective tumor responses were observed in 18% of patients who received lutetium Lu 177 dotatate versus 3% in the control group ($P < .001$). However, data from the final analysis showed that treatment with lutetium Lu 177 dotatate did not result in a significant improvement in median OS (lutetium Lu 177 dotatate, 48.0 months; high-dose octreotide, 36.3 months; HR, 0.84; $P = .30$).[165] Results from a long-term phase II study that enrolled patients with advanced GI NETs determined that the median OS and PFS were 71.0 months and 59.8 months, respectively, in patients who received PRRT with 177Lu-DOTA-octreotate (18.5 Gbq), and 97.6 months and 59.8 months, respectively, in patients who received a 27.5 Gbq dosage.[193]

PRRT with lutetium Lu 177 dotatate is approved by the FDA for the treatment of adult and pediatric patients ≥12 years of age with SSTR-positive unresectable, low- or intermediate-grade, locally advanced or metastatic GEP-NETs.[194] Treatment with lutetium Lu 177 dotatate is a recommended option for patients with unresectable GI NETs with SSTR-positive tumors and clinically significant disease progression on octreotide LAR or lanreotide (category 1 for progressive mid-gut tumors).

More recently, the NETTER-2 study enrolled patients with advanced high-risk SSTR+ GEP-NET (Ki-67 index 10%–55%) in the first-line setting.[166] A total of 226 patients were randomized 2:1 to lutetium Lu 177 dotatate plus

Version 3.2025 © 2025 National Comprehensive Cancer Network© (NCCN©), All rights reserved. NCCN Guidelines® and this illustration may not be reproduced in any form without the express written permission of NCCN.

octreotide LAR or octreotide LAR 60 mg/month in the first-line setting. The median Ki-67 index was 16% (range 12%–25%), 65% had G2 disease, and 46% had a GI primary. The primary endpoint was PFS by central review, which was 22.8 months (95% CI, 19.4 months–not estimated) in the lutetium Lu 177 dotatate group and 8.5 months (95% CI, 7.7–13.8) in the control arm ($P < .0001$). Consistent benefit was observed across all subgroups, including G2 versus G3, pancreas versus non-pancreas versus small intestine primary, providing additional support for PRRT in GI NETs. OS data were not mature at the time of the analysis. Time to deterioration in QOL was similar in both groups. One case of myelodysplasia was noted in the lutetium Lu 177 dotatate plus octreotide LAR group, although further follow-up is needed to fully assess long-term safety.

Please see *Principles of Peptide Receptor Radionuclide Therapy with Lutetium Lu 177 Dotatate* in the algorithm for practical guidance and information, including patient eligibility, patient preparation for treatment, dose and administration of lutetium Lu 177 dotatate, post-treatment instructions, and timing of SSAs.

Use of Somatostatin Analogs with Lutetium Lu 177 Dotatate

Most patients treated with PRRT will have progressed on first-line SSA treatment. Patients with hormonally functional tumors should continue octreotide LAR or lanreotide along with lutetium Lu 177 dotatate. It is unclear whether patients with nonfunctional tumors benefit from continuation of SSA treatment during and after lutetium Lu 177 dotatate treatment. The Panel recommends discontinuing treatment with octreotide LAR or lanreotide for nonfunctional tumors if there is clinically significant disease progression. A study looked at whether 68Ga-DOTATATE uptake before or after long-acting SSA treatment was affected in patients with NETs and found that the uptake in the primary tumor and metastatic sites were not compromised.[114] However, there are still theoretical concerns regarding the competition between SSAs and lutetium Lu 177 dotatate for SSTR binding. SSA treatment interruption may not be necessary, but the Panel recommends the following adjustments. Concomitant use of long-acting SSAs is not recommended in the 4 weeks prior to each treatment with lutetium Lu 177 dotatate. Additionally, short-acting SSAs should be stopped 24 hours before each lutetium Lu 177 dotatate treatment. SSAs (short- and long-acting) can be resumed 4 to 24 hours after each lutetium Lu 177 dotatate treatment. IV infusion of amino acids is a critical part of lutetium Lu 177 dotatate therapy for nephroprotection.

Control of Tumor Growth in the Setting of Locoregional Unresectable Disease or Distant Metastatic Lung or Thymic Neuroendocrine Tumors (Atypical and Typical Carcinoid Tumors)

Lung NETs include a spectrum from low-grade typical NETs to intermediate-grade atypical NETs.[195] First-line therapy options for locoregional unresectable low-grade disease (typical carcinoid) include observation (if asymptomatic), everolimus, octreotide LAR or lanreotide (if SSTR-positive and/or has hormonal symptoms), temozolomide with or without capecitabine, or RT. First-line therapy options for locoregional unresectable intermediate-grade disease (atypical carcinoid) include observation (if asymptomatic and non-progressive); cytotoxic chemotherapy with cisplatin with etoposide, carboplatin with etoposide, or temozolomide with or without capecitabine; everolimus; octreotide LAR or lanreotide (if SSTR-positive and/or has hormonal symptoms); or RT with or without concurrent cisplatin with etoposide or carboplatin with etoposide. Subsequent therapy for either low-grade or intermediate-grade disease includes clinical trial (preferred), cabozantinib (category 1 if prior treatment with everolimus), consideration of an alternate primary therapy, or consideration of PRRT with lutetium Lu 177 dotatate (if SSTR-positive and progression on octreotide LAR/lanreotide).

Version 3.2025 © 2025 National Comprehensive Cancer Network© (NCCN©), All rights reserved. NCCN Guidelines® and this illustration may not be reproduced in any form without the express written permission of NCCN.

PLEASE NOTE that use of this NCCN Content is governed by the End-User License Agreement, and you MAY NOT distribute this Content or use it with any artificial intelligence model or tool.
Printed by Galya Basol Kochav on 1/7/2026 1:55:52 PM. Copyright © 2026 National Comprehensive Cancer Network, Inc. All Rights Reserved.

For patients with distant metastases who are asymptomatic with low tumor burden and low-grade disease (typical carcinoid), observation (with chest CT with contrast and multiphasic abdomen/pelvis CT or MRI every 3 to 6 months) or octreotide LAR or lanreotide (if SSTR-positive and/or has hormonal symptoms) are recommended. For patients with distant metastases, a clinical trial is preferred for patients with clinically significant tumor burden and low-grade (typical carcinoid) disease, evidence of disease progression, intermediate-grade (atypical carcinoid) disease, or symptomatic disease. Observation can be considered in select patients with low burden of disease and favorable prognostic features (with chest CT scans with contrast and multiphasic abdomen/pelvis CT or MRI scans every 3 to 6 months). If systemic therapy is indicated, cabozantinib (category 1 if prior treatment with everolimus), everolimus (category 1 for nonfunctional lung NETs), and octreotide LAR or lanreotide (if SSTR+ tumor and/or hormonal symptoms) are preferred regimens. Carboplatin + etoposide, cisplatin + etoposide, PRRT with lutetium Lu 177 dotatate (if SSTR-positive and progression on octreotide LAR or lanreotide), temozolomide with or without capecitabine, and above-label dose octreotide LAR or lanreotide (for SSTR-positive disease and/or hormonal symptoms and progression on standard SSA doses) (category 2B) are considered useful in certain circumstances. Liver-directed therapy for liver-predominant disease is also an option. See *Principles of Liver-Directed Therapy for Neuroendocrine Tumor Metastases* in the algorithm. For symptom control, the addition of focal therapy, such as radiation, endobronchial therapy, or ablation, can be considered.

Somatostatin Analogs for Advanced Lung/Thymic Neuroendocrine Tumors

The phase III SPINET trial randomized 77 patients with bronchopulmonary NETs (typical and atypical carcinoids) to receive either lanreotide plus best supportive care (N = 51) or placebo plus best supportive care (N = 26).[196] Due to a protocol amendment, patients in the double-blind phase of the study were able to transition to the open-label phase to receive lanreotide plus best supportive care. The primary endpoint of the study was modified to be the centrally confirmed PFS during the double-blind or open-label phase of the study for patients randomized to the lanreotide arm. The median PFS during both phases of the study was 16.6 months (95% CI, 11.3–21.9 months). In the double-blind phase of the study, the median PFS was 16.6 months (95% CI, 11.3–21.9 months) for those treated with lanreotide compared to 13.6 months (95% CI, 8.3 months–not calculable) for those treated with placebo (HR, 0.94; P = .866). The median centrally assessed PFS was 21.9 months for patients with typical carcinoids treated with lanreotide (placebo, 13.9 months) and was 13.8 months for those with atypical carcinoids treated with lanreotide (placebo, 11.0 months). Fourteen percent of those treated with lanreotide achieved an objective response, by central assessment, compared to 0% for placebo. However, this was not statistically significant.

Patients can be considered for treatment with octreotide LAR or lanreotide if the tumor is SSTR-positive and/or associated with hormonal symptoms. No clear consensus exists on the timing of octreotide or lanreotide initiation in asymptomatic patients with metastatic NETs and low tumor burden. Although initiation of octreotide LAR or lanreotide is an option in these patients, deferring initiation until evidence of tumor progression is seen may also be appropriate in selected patients. In patients with SSTR-positive disease and/or hormonal symptoms, after clinical, symptomatic, or radiographic progression on standard SSA doses, for symptom and/or tumor control, above-label dosing octreotide LAR (up to 60 mg once a month) or lanreotide (up to 120 mg every 14 days) may be useful in select cases.[162,165,166,196]

Everolimus for Advanced Lung/Thymic Neuroendocrine Tumors

The RADIANT-4 double-blind, placebo-controlled, phase 3 trial randomized 302 patients with progressive, non-functional lung or GI NETs 2:1 to receive everolimus or placebo.[173] As previously described, patients

Version 3.2025 © 2025 National Comprehensive Cancer Network© (NCCN©), All rights reserved. NCCN Guidelines® and this illustration may not be reproduced in any form without the express written permission of NCCN.

were not receiving an SSA at the time of study enrollment and concurrent SSA was not a study requirement. Overall, 90/302 patients had a lung primary (N = 63 in the everolimus arm and N = 27 in the placebo arm). The median PFS was 11.0 months (95% CI, 9.2–13.3) in the everolimus arm and 3.9 months (95% CI, 3.6–7.4) in the placebo arm. Overall, the HR for progression or death was 0.48 (95% CI, 0.35–0.67; $P < .00001$). An exploratory analysis of a subgroup of patients with lung NETs reported improved PFS by central review (HR, 0.50; 95% CI, 0.28–0.88) in the everolimus arm (9.2 months) compared to the placebo arm (3.6 months).[175] The phase 3 RADIANT-2 trial in patients with carcinoid syndrome included 44/429 patients with lung NETs, including nine with atypical carcinoids.[197] This study did not stratify according to the type of tumor; 33 patients received octreotide LAR + everolimus and 11 patients received octreotide LAR + placebo. Median PFS by central review was 13.63 (95% CI, 5.55–14.29) months in the everolimus plus octreotide LAR group and 5.59 (95% CI, 2.79–27.76) months in the placebo plus octreotide LAR group (HR, 0.72; 95% CI, 0.31–1.68), although this did not meet the prespecified boundary (one-sided log-rank test $P = .228$). Taken together, the data suggest that everolimus is a reasonable treatment option for patients with lung/thymic NETs with clinically significant tumor burden, disease progression, and/or intermediate grade (atypical carcinoid) (category 1 for nonfunctional tumors).

Cabozantinib for Advanced Lung/Thymic Neuroendocrine Tumors

Cabozantinib is an option for those with advanced lung/thymic NETs with clinically significant tumor burden and low-grade disease (typical carcinoid), evidence of disease progression, intermediate-grade disease (atypical carcinoid), or symptomatic disease (category 1 if prior treatment with everolimus). Cabozantinib demonstrated efficacy in the phase III CABINET trial in patients with progressive, well-differentiated, locally advanced or metastatic pancreatic or extrapancreatic NETs and was approved for these indications in 2025.[177] In the extrapancreatic NET cohort, lung/thymic NETs accounted for 33/134 patients in the cabozantinib arm and 16//69 patients in the placebo arm. The median PFS was 8.4 months in the cabozantinib arm and 3.9 months in the placebo arm (stratified HR for progression or death, 0.38; 95% CI, 0.25–0.59; $P < .001$). In the lung/thymic subgroup specifically, stratified HR for progression/death was 0.17 (95% CI, 0.07–0.42).

Chemotherapy for Advanced Lung/Thymic Neuroendocrine Tumors

Temozolomide either administered alone or in combination with capecitabine is an option to manage tumor burden and any associated symptoms in patients with lung/thymic NETs.[198,199] In a retrospective study of 31 patients with progressive metastatic bronchial NETs, temozolomide monotherapy was associated with PRs in 14% of patients.[199] A small retrospective study examined the combination of temozolomide and capecitabine in patients with advanced lung NETs. The results showed an ORR of 30%, with a median OS of 68 months (95% CI, 35.3 months–100.7 months) and a median PFS of 13 months (95% CI, 4.4 months–21.6 months).[200] Another study comprising 33 patients with advanced pulmonary carcinoids treated with temozolomide and capecitabine reported a median OS of 30.4 months and a median PFS of 9.0 months.[201] Carboplatin/etoposide,[198,202] cisplatin/etoposide,[198,202,203] or temozolomide[199] with or without capecitabine[200,201] can be considered for intermediate-grade (atypical tumors) disease with Ki-67 proliferative index and mitotic index in the higher end of the defined spectrum.[198]

PRRT with Lutetium Lu 177 Dotatate for Advanced Lung/Thymic Neuroendocrine Tumors

Treatment with lutetium Lu 177 dotatate is also a recommended option for patients with SSTR+ lung or thymic distant metastatic NETs with disease progression on octreotide LAR or lanreotide. A tumor is deemed to be SSTR-positive if the uptake in measurable lesions is greater than the liver. While prospective randomized studies are lacking, a meta-analysis of 18

Version 3.2025 © 2025 National Comprehensive Cancer Network© (NCCN©), All rights reserved. NCCN Guidelines® and this illustration may not be reproduced in any form without the express written permission of NCCN.

PLEASE NOTE that use of this NCCN Content is governed by the End-User License Agreement, and you MAY NOT distribute this Content or use it with any artificial intelligence model or tool.
Printed by Galya Basol Kochav on 1/7/2026 1:55:52 PM. Copyright © 2026 National Comprehensive Cancer Network, Inc. All Rights Reserved.

studies with 1920 patients with unresectable metastatic GEP-NETs and lung NETs treated with lutetium Lu 177 dotatate PRRT found a pooled disease response rate of 29% to 31% and a combined disease control rate of 74% to 81%.[194] Another study examined the long-term efficacy, survival, and toxicity of lutetium Lu 177 dotatate in a group of 610 Dutch patients with metastatic GEP-NETs and bronchial NETs.[204] PFS and OS for all patients were 29 months (95% CI, 26–33 months) and 63 months (95% CI, 55–72 months), respectively. Other studies noted OS (58.8 months, n = 114)[205] and median PFS (20.1 months in patients with typical bronchial carcinoid and 15.7 months in patients with atypical bronchial carcinoid; n = 34)[206] with PRRT treatment.[207]

Control of Symptoms from Carcinoid Syndrome and Related Complications

Somatostatin Analogs

Patients who have symptoms of carcinoid syndrome should be treated with octreotide LAR or lanreotide.[157] The LAR formulation of octreotide is commonly used for the chronic management of symptoms in patients with carcinoid syndrome. Standard doses of octreotide LAR are 20 to 30 mg intramuscularly every 4 weeks. Higher doses have been shown to be safe.[162,165,166] Therapeutic levels would not be expected to be reached for 10 to 14 days after LAR injection. Short-acting octreotide (100–250 mcg subcutaneously three times daily) can be added to octreotide LAR or lanreotide for rapid relief of symptoms or for breakthrough symptoms.[208-210]

Lanreotide has a similar mechanism of action as octreotide LAR, but is administered as a deep subcutaneous injection. The standard dose of lanreotide is 120 mg every 4 weeks. Several studies have shown it to be effective at controlling symptoms of hormone secretion in patients with GI NETs, gastrinomas, or tumors secreting vasoactive intestinal polypeptide (VIPomas).[211-215] The multinational phase III ELECT trial randomized 115 patients with carcinoid syndrome who were either naïve to or responsive to octreotide to receive 120 mg of lanreotide or placebo and evaluated the number of days patients required use of short-acting octreotide.[216] Patients in the lanreotide arm required less frequent short-acting octreotide than those in the placebo arm (33.7% vs. 48.5%; $P = .017$). Overall, lanreotide treatment improved symptom control, irrespective of prior octreotide use.[216,217]

Telotristat

If carcinoid syndrome is poorly controlled, telotristat may be considered as an additional therapy for persistent diarrhea after ruling out non-carcinoid syndrome causes. Patients should be evaluated for pancreatic exocrine deficiency and bile acid diarrhea. Telotristat or telotristat ethyl is a small-molecule tryptophan hydroxylase (TPH) inhibitor, which decreases urinary 5-HIAA levels and the frequency of bowel movements (BMs) in patients with carcinoid syndrome.[218-221] It was approved by the FDA in February 2017 and the recommendation to use telotristat for persistent diarrhea in this context is based on the results of the TELESTAR study. The TELESTAR study was a multicenter, randomized, double-blind, placebo-controlled phase III trial of 135 patients with metastatic NETs and a documented history of carcinoid syndrome, who were experiencing an average of ≥4 BMs a day while receiving stable-dose SSA therapy for at least 3 months prior to enrollment in the study.[220] Patients were randomized to receive placebo, telotristat ethyl (250 mg), or telotristat ethyl (500 mg) in a 1:1:1 ratio three times per day orally for 12 weeks during a double-blind treatment period. From baseline to week 12, mean BM frequency reductions per day for placebo, telotristat ethyl (250 mg), and telotristat ethyl (500 mg) were -0.9, -1.7, and -2.1, respectively. In addition, both telotristat dosages significantly decreased mean urinary 5-HIAA compared to placebo at week 12 ($P < .001$).[220] Compared to placebo, treatment with telotristat at either dosage did not result in a statistically significant change in the number of observed flushing episodes; therefore, additional options should be considered to manage other symptoms associated with carcinoid syndrome. In the TELEPRO

Version 3.2025 © 2025 National Comprehensive Cancer Network© (NCCN©), All rights reserved. NCCN Guidelines® and this illustration may not be reproduced in any form without the express written permission of NCCN.

and TELEPRO-II real-world study, patients given telotristat ethyl had a decrease in diarrhea and other carcinoid syndrome symptoms.[221,222] Results from the nonrandomized phase III TELEPATH study suggest that long-term use of telotristat ethyl in patients with carcinoid syndrome was well tolerated.[223] Treatment-related adverse events were reported in 45.2% of patients.

Additional Considerations Related to Carcinoid Syndrome

Other therapies that may be considered to achieve symptom control by reducing tumor burden include hepatic arterial embolization, cytoreductive surgery for liver-predominant disease, or other systemic therapy based on disease site.[224]

In the setting of carcinoid syndrome, an echocardiogram should also be performed every 1 to 3 years or as clinically indicated for patients without CHD, and at least annually for patients with established CHD. Cardiac heart disease is frequent in patients with carcinoid syndrome; in one study, 59% of patients with carcinoid syndrome were diagnosed with tricuspid regurgitation.[225,226] A study of 250 patients with carcinoid syndrome showed that patients with 5-HIAA levels of ≥300 µmol (57 mg) over 24 hours and with ≥3 flushing episodes per day were more likely to have CHD.[227] To monitor disease control and/or progression, surveillance imaging with multiphasic abdomen/pelvis CT or MRI every 12 weeks to 12 months and chest CT scans (with or without contrast) should be performed as clinically indicated.

Diffuse Idiopathic Pulmonary Neuroendocrine Cell Hyperplasia (DIPNECH)

Although rare, some patients may present with multiple lung nodules or tumorlets and widespread peripheral airway neuroendocrine cell hyperplasia. In this case, a diagnosis of DIPNECH can be made.[195] This condition is generally indolent, and patients can be observed with chest CT scans without contrast every 12 to 24 months or as clinically indicated. If chronic cough/dyspnea is not responsive to inhalers or conventional treatment, a trial of octreotide LAR or lanreotide for symptom control is a recommended option.[228,229] A referral to pulmonary medicine should be considered for symptom management.

Neuroendocrine Tumors of the Pancreas (Well-Differentiated Grade 1/2)

According to a population-based study, malignant PanNETs account for approximately 1% of pancreatic cancers by incidence and 10% of pancreatic cancers by prevalence.[230] Based on an analysis of the SEER database from 2000 to 2016, the peak incidence of occurrence is between ages 45 to 64 years, and the incidence is rising over time.[231] In an analysis of the SEER database from 2000 to 2021, the overall incidence of PanNETs during this time frame was 0.8 per 100 000 people.[5] An estimated >60% to 91% of PanNETs are nonfunctional.[14,73] The remainder manifest with clinically evident hormonal symptoms. Consistent with these numbers, analysis of the NCCN NETs Outcomes Database found that 22% of patients with PanNETs have a hormonal syndrome.[102] Of these functioning tumors, ≤70% are insulinomas, and only 10% are associated with metastases. Approximately 15% are glucagonomas. Gastrinomas and somatostatinomas account for another 10%; gastrinomas and somatostatinomas (80%–90%) are associated with a relatively high risk for metastases.[232] The remaining rare PanNETs include VIPoma and cholecystokinin-producing tumors.[233]

PanNETs are most commonly sporadic, but emerging data suggest germline mutations are present in 16% to 21% of patients.[95-97] PanNETs occurring in patients with MEN1 syndrome are typically multiple and require different treatment strategies from those used for patients with sporadic PanNETs, which are usually solitary (see *MEN1*, below). Gastrinoma and insulinoma are the most common PanNETs in patients with MEN1.[234] PanNETs can also occur in patients with germline

Version 3.2025 © 2025 National Comprehensive Cancer Network© (NCCN©), All rights reserved. NCCN Guidelines® and this illustration may not be reproduced in any form without the express written permission of NCCN.

mutations in *MEN4, VHL,* and other genes.[235] See *Principles of Hereditary Cancer Risk Assessment and Genetic Counseling* in the algorithm.

Evaluation of Neuroendocrine Tumors of the Pancreas (Well-Differentiated Grade 1/2)

The recommended evaluation includes a multiphasic abdomen CT or MRI scan (with or without pelvis). A chest CT scan with or without contrast may be included as appropriate. SSTR-based imaging and EUS, with or without biopsy, can also be considered if additional imaging is needed.[236] A multidisciplinary discussion is recommended prior to biopsy. Consideration of genetic counseling and testing for inherited genetic syndromes is recommended for all patients with PanNETs. Personal and family history should also be evaluated in all patients with PanNETs for the possibility of MEN1 (see *Multiple Endocrine Neoplasia*, below) or other hereditary syndromes as appropriate.

Hormone-secreting tumors, even when very small, may result in significant clinical symptoms, and lesion identification can be difficult.[237] These cases often require additional imaging, such as EUS and SSTR-based imaging. Because many PanNETs secrete hormones, biochemical evaluation should also be considered in patients with PanNETs.[232] Biochemical evaluation is generally guided by the presence of symptoms that might indicate excess hormone secretion. Screening for hormones in asymptomatic individuals is not routinely recommended. The range of symptoms associated with hormonal secretion is diverse. Classic syndromes include those associated with insulinomas, which secrete insulin, resulting in fasting or nocturnal hypoglycemia. Gastrinomas secrete gastrin, and patients often present with recurrent peptic ulcers. Glucagonomas are associated with the development of hyperglycemia or diabetes mellitus and/or migratory necrolytic erythema. Patients with somatostatinomas may also present with hyperglycemia or diabetes mellitus and/or diarrhea/steatorrhea. VIPomas are characterized by watery diarrhea, hypokalemia, and achlorhydria (WDHA syndrome) from secretion of VIP. The guidelines describe appropriate tests for each of these situations.

Chromogranin A levels are elevated in ≥60% of patients with either functioning or nonfunctioning pancreatic endocrine tumors.[238-240] Levels elevated to twice the normal limit or higher are associated with shorter survival times for patients with metastatic NETs (HR, 2.8; 95% CI, 1.9–4.0; $P < .001$).[241] Chromogranin A was also found to be a prognostic factor in a prospective study of patients treated with everolimus.[242] However, care should be taken in measuring chromogranin A and interpreting the results, because spuriously elevated levels of chromogranin A have been reported in patients using PPIs, those with renal or liver failure, those with hypertension, and those with chronic gastritis.

Evaluation of Gastrinomas

Gastrinoma should be suspected in patients with severe and refractory gastroduodenal ulcers or symptoms such as dyspepsia, usually accompanied by diarrhea. Evaluation of a patient with suspected gastrinoma includes measurement of serum gastrin levels.[243] Diagnosis of gastrinoma can be confounded by the concurrent use of PPIs, which will elevate serum gastrin levels. Importantly, most patients who are found to have an elevated level of serum gastrin do not have a gastrinoma but have achlorhydria or are receiving PPIs or antacids. To confirm diagnosis, serum gastrin levels should ideally be checked when fasting and after the patient is off PPI therapy for >1 week.[244] However, PPIs or H2 blockers should be continued in patients with overt clinical symptoms of gastrinoma and/or risks of complications. Including input from a gastroenterologist familiar with the disease is encouraged when crafting a plan for the diagnosis and management of gastrinoma. Genetic counseling and testing for inherited genetic syndromes is recommended.

Version 3.2025 © 2025 National Comprehensive Cancer Network© (NCCN©), All rights reserved. NCCN Guidelines® and this illustration may not be reproduced in any form without the express written permission of NCCN.

Imaging with multiphasic abdomen, with or without pelvis, CT or MRI scan with IV contrast is recommended. Other tests, such as SSTR-based imaging, chest CT scan with or without contrast, EUS, and other biochemical tests may be performed as appropriate. Approximately 70% of patients with MEN1 and gastrinoma have tumors situated in the duodenum.

Evaluation of Insulinomas

Insulinomas should be suspected in people who have hypoglycemia (generally fasting or nocturnal) and a pancreatic mass. However, some insulinomas can be small and not visible on imaging and so should be suspected in persons presenting with hypoglycemia. Evaluation with a 72-hour fast, which tests serum insulin, pro-insulin, and C-peptide during concurrent hypoglycemia, is the gold standard.[245] An insulin level >3 mcIU/mL (usually >6 mcIU/mL), C-peptide concentrations of at least 0.6 ng/mL, and proinsulin levels of ≥5 pmol/L when fasting blood glucose is <55 mg/dL is suspicious for insulinoma.[245] The Panel also recommends evaluating fasting blood glucose levels if clinically feasible. Other biochemical tests may be performed as appropriate. Other causes of hypoglycemia, such as adrenal insufficiency and malnutrition, and other causes of non–insulin-mediated hypoglycemia should be ruled out prior to performing a 72-hour fast. The Endocrine Society Guidelines on Hypoglycemia have details regarding the general workup for hypoglycemia.[245]

Imaging with multiphasic abdomen, with or without pelvis, CT with contrast or MRI is recommended to localize insulinomas. Some insulinomas are too small to be imaged with CT or MRI, and in those cases EUS can be useful. If imaging is negative, then insulinomas can often be localized by injecting calcium into selective pancreatic arteries and measuring the insulin levels in the right (usually) or left hepatic vein (Imamura-Doppman procedure).[246] Most experts recommend this test only for patients with persistent or recurrent insulin-mediated hypoglycemia and when other localization tests are equivocal or negative.

Ninety percent of insulinomas pursue an indolent course and can be cured surgically. To rule out metastatic disease, chest CT scans with or without contrast and SSTR-based imaging can also be done. Historically insulinomas have demonstrated less SSTR expression by 111In-octreotide scintigraphy (sensitivity 20%–60%) than other PanNETs, reducing the value of SSTR-based imaging as an imaging technique in some patients with insulinoma.[247] However, recent studies suggest the majority of insulinomas (ie, >70%) are evident on SSTR PET imaging.[247-251] Genetic counseling and testing for inherited genetic syndromes should be considered.

Evaluation of Glucagonomas and VIPomas

For patients with recent-onset diabetes, cachexia, and/or a necrolytic erythematous skin rash and a pancreatic mass, the Panel recommends a blood test for glucagon and blood glucose. For suspected VIPomas with characteristic watery diarrhea, testing for VIP and electrolytes is recommended. For both glucagonomas and VIPomas, multiphasic abdomen, with or without pelvis CT or MRI scans with IV contrast is recommended to identify the primary tumors. Chest CT scans with or without contrast can be performed. SSTR-based imaging and EUS can be performed as appropriate if the tumor is not able to be localized or there is concern for metastatic disease. Biochemical evaluation can be performed as clinically indicated. Genetic counseling and testing for inherited genetic syndromes should be considered.

Treatment of Locoregional Resectable Neuroendocrine Tumors of the Pancreas (Well-Differentiated Grade 1/2)

Resection is the first-line treatment approach for localized PanNETs when possible, and can result in excellent outcomes. Exceptions to surgery

Version 3.2025 © 2025 National Comprehensive Cancer Network© (NCCN©), All rights reserved. NCCN Guidelines® and this illustration may not be reproduced in any form without the express written permission of NCCN.

include patients with other life-limiting comorbidities or high surgical risk, particularly if tumors are small and indolent. There is no established role for adjuvant therapy, although there is an ongoing randomized clinical trial exploring the utility of chemotherapy after resection (NCT05040360).

Nonoperative Management

Most patients with localized PanNETs should undergo surgical resection (including pancreatectomy or enucleation in select cases), absent any contraindications. Exceptions include patients with other life-limiting comorbidities, high surgical risk, or widely metastatic disease. Additionally, several studies have suggested that patients with incidentally discovered tumors <1 cm in size may be safely followed in some cases, depending on the site of the tumor.[252,253] Other studies, including an analysis of the SEER database, suggest that some small tumors (measuring <2 cm in size in these studies) can pursue a more aggressive course.[254-256] Other studies suggest that nonoperative management can be safe for small nonfunctioning PanNETs.[257-260] Based on these limited data, the Panel recommends observation for small nonfunctioning tumors that are ≤1 cm. See *PanNET-11* in the algorithm for more information. For tumors >1 cm to ≤2 cm, observation alone can be considered for selected cases of incidentally discovered, low-grade, non-functional PanNETs.

Consideration of belzutifan is also an option for the very uncommon situation of resectable nonfunctioning tumors in the setting of germline *VHL* alteration. Belzutifan is an oral, hypoxia-inducible factor-2 alpha (HIF-2α) inhibitor that was approved by the FDA in 2021 for the treatment of adults with VHL disease-associated tumors that do not require immediate surgery (renal cell carcinoma, central nervous system hemangioblastomas, or PanNETs). A phase II study evaluated belzutifan in 61 patients with germline *VHL* alterations with localized/nonmetastatic renal cell carcinoma with germline VHL disease-associated tumors in other organ systems.[261] The study excluded patients with prior systemic anticancer therapy, including anti-vascular endothelial growth factor (VEGF) therapy, patients needing immediate surgical intervention for tumor treatment, or patients with evidence of metastatic disease on screening imaging, but included patients with PanNETs and central nervous system hemangioblastomas. Treatment with belzutifan resulted in an ORR of 91% in 22 patients with PanNETs, as assessed by an independent review committee using RECIST, version 1.1. Fourteen percent of patients achieved a complete response (CR). The median time to response and median duration of response for these patients were 5.5 months (range, 2.5 months–16.4 months) and not reached (range, 2.9+ months–22.3+ months), respectively, with responses still ongoing at the time to data cutoff (median follow-up of 21.8 months [range, 20.2 months–30.1 months] for all patients). The most common grade 3 adverse events were anemia (8%), hypertension (8%), and fatigue (5%) across all patients. A follow-up report on the 22 patients with measurable PanNET (median size 19 mm, range 10–52 mm) after a median follow-up of 37.8 months confirmed the ORR of 91% in PanNETs including CR in 7/22 (32%) consistent with significant activity in VHL-associated PanNET.[262] Of note, the decision to use belzutifan in small resectable tumors needs to be individualized. Data for the use of belzutifan for larger tumors, locally advanced unresectable tumors, and distant disease are extremely limited and clinical trials are ongoing (NCT04924075).

Preoperative Management

Surgical resection is the optimal treatment for locoregional pancreatic endocrine tumors. Before excision, however, any symptoms of hormonal excess must be treated. Octreotide LAR or lanreotide can be used for symptom control in most PanNET subtypes.[157] Octreotide LAR or lanreotide can be considered for patients with insulinoma but only if the tumor expresses SSTRs, because they can suppress counterregulatory hormones such as growth hormone, glucagon, and catecholamines. In this situation, octreotide LAR and lanreotide can precipitously worsen

Version 3.2025 © 2025 National Comprehensive Cancer Network© (NCCN©), All rights reserved. NCCN Guidelines® and this illustration may not be reproduced in any form without the express written permission of NCCN.

hypoglycemia and can result in fatal complications.[263] Octreotide LAR and lanreotide should not be used in patients with insulinoma who have a negative result by SSTR-based imaging.

In addition, specific measures are often recommended based on symptoms. For insulinomas, it is important to stabilize glucose levels with diet and/or diazoxide and/or everolimus.[264-266] For gastrinomas, gastrin hypersecretion may be treated with high-dose PPIs. For patients with glucagonoma, treatment of hyperglycemia and diabetes is necessary, especially to control blood sugar level prior to surgery. All patients who might require splenectomy should receive preoperative vaccination against pneumococcus, *haemophilus influenzae* type b, and meningococcal group c. Care should be taken to ensure appropriate boosters are given within the recommended time frame.

Surgical Management of Non-functioning Pancreatic Neuroendocrine Tumors (Well-Differentiated Grade 1/2)

For tumors >1 cm to ≤2 cm, other recommended options include pancreatectomy, or enucleation in select cases. As appropriate, central pancreatectomy or spleen-preserving surgery should be considered. The Panel recommends surgical resection for larger tumors absent contraindications. Pancreatectomy is recommended for larger (>2 cm), invasive, node-positive, nonfunctional tumors. Pancreatectomies should have negative margins (including adjacent organs) and include a regional lymphadenectomy unless risk of nodal metastasis is low. Lymph node resection should be considered for tumors 1 to 2 cm, because there is a small but real risk of lymph node metastases.[267,268] Surveillance imaging is recommended for 10 years and MRI over CT should be considered to minimize radiation risks.

Surgical Management of Gastrinomas

The treatment approach for gastrinoma usually depends on the results of preoperative localization studies and on findings during exploratory laparotomy. In patients with occult gastrinoma (ie, no primary tumor or metastasis is seen on imaging), the Panel recommends either observation or exploratory surgery, including duodenotomy and intraoperative ultrasound with enucleation or local resection/enucleation of tumors if identified at operation, and removal of periduodenal nodes. A pancreatoduodenectomy without tumor localization is not recommended by the Panel.

Gastrinomas in the duodenum are treated with duodenotomy and intraoperative ultrasound with local resection or enucleation of tumors and periduodenal node dissection. Gastrinomas in the head of the pancreas should be managed with pancreatoduodenectomy. Although rare, gastrinomas in the distal pancreas are treated with distal pancreatectomy and splenectomy and removal of the regional lymph nodes. Gastrinomas have high metastatic potential,[269] which is the rationale for splenectomy.

Surgical Management of Insulinomas

The treatment for exophytic or peripheral insulinomas, because they are usually benign, is enucleation. Sporadic tumors are usually solitary, whereas familial tumors are multiple. If enucleation is not possible because of invasion or tumor location within the pancreas, then pancreatoduodenectomy for tumors in the head of the pancreas or distal pancreatectomy with preservation of the spleen for smaller tumors not involving splenic vessels may be performed. A minimally invasive resection can be considered.

Surgical Management of Glucagonomas

Most glucagonomas are malignant and calcified and located in the tail of the pancreas, with regional node involvement. The recommended

Version 3.2025 © 2025 National Comprehensive Cancer Network© (NCCN©), All rights reserved. NCCN Guidelines® and this illustration may not be reproduced in any form without the express written permission of NCCN.

PLEASE NOTE that use of this NCCN Content is governed by the End-User License Agreement, and you MAY NOT distribute this Content or use it with any artificial intelligence model or tool.
Printed by Galya Basol Kochav on 1/7/2026 1:55:52 PM. Copyright © 2026 National Comprehensive Cancer Network, Inc. All Rights Reserved.

treatment is distal pancreatectomy with splenectomy and resection of the peripancreatic lymph nodes. For tumors in the pancreatic head, pancreatoduodenectomy with resection of the peripancreatic lymph nodes is recommended. Small (<2 cm) peripheral glucagonomas are rare; enucleation or local excision with peripancreatic lymph dissection may be considered for small peripheral tumors of the head or distal pancreas. A hypercoagulable state has been reported in 10% to 33% of patients with glucagonoma.[270,271] Therefore, perioperative anticoagulation can be considered because of the increased risk of pulmonary emboli.

Surgical Management of VIPomas

Distal VIPomas are treated with distal pancreatectomy with resection of peripancreatic lymph nodes and with or without splenectomy. Pancreatoduodenectomy with dissection of peripancreatic nodes is recommended for tumors in the head of the pancreas. Small (<2 cm) peripheral VIPomas are rare; enucleation or local excision with peripancreatic lymph dissection may be considered for small peripheral tumors of the head or distal pancreas.

Surgical Management of Other Pancreatic Neuroendocrine Tumors (Well-Differentiated Grade 1/2)

The treatment recommendations for tumors secreting hormones such as somatostatinoma, ACTH, parathyroid hormone-related peptide (PTHrP), and pancreatic polypeptide (PP) are similar to those for nonfunctioning tumors.

Surgical Management of Well-Differentiated Grade 1/2

PanNETs in the Setting of a Hereditary Cancer Syndrome

Patients with germline mutations are treated based on the same considerations as sporadic tumors. Functional tumors should be considered for resection and nonfunctional tumors should be offered resection if >2 cm in size, invasive, or node-positive. Additional consideration should be given to tumors >1 cm to ≤2 cm in size given likelihood for multifocality of disease and potential need for additional resection in the future.

Surveillance of Resected Pancreatic Neuroendocrine Tumors (Well-Differentiated Grade 1/2)

Disease recurrence has been observed in 21% to 42% of patients with PanNETs and can occur after many years.[272-274] Higher lymph node ratio and Ki-67 status may indicate a higher chance of recurrence.[272] Patients should undergo follow-up 12 weeks to 12 months after resection, or earlier if the patient presents with symptoms. After 1-year post-resection, follow-up should occur every 6 to 12 months for up to 10 years post-resection with an H&P, follow-up with biochemical markers as clinically indicated for functional tumors, and imaging. After 10 years, surveillance should be considered as clinically indicated.[275] Multiphasic abdomen, with or without pelvis, CT or MRI should be performed. Chest CT scans (with or without contrast) can be performed as clinically indicated. These surveillance recommendations may also apply to cases where observation of patients has been chosen. Less frequent surveillance may be appropriate for low-risk tumors such as well-differentiated stage I PanNETs. SSTR-based imaging or FDG-PET/CT scans are not recommended for routine surveillance.

The optimal duration of surveillance is unknown. In one study of 123 patients with resected sporadic PanNETs, most recurrences occurred within 5 years of resection, and all recurrences occurred within 10 years.[276] In select cases, including resectable locoregional or oligometastatic recurrence, surgical resection may be considered.

Version 3.2025 © 2025 National Comprehensive Cancer Network© (NCCN©), All rights reserved. NCCN Guidelines® and this illustration may not be reproduced in any form without the express written permission of NCCN.

PLEASE NOTE that use of this NCCN Content is governed by the End-User License Agreement, and you MAY NOT distribute this Content or use it with any artificial intelligence model or tool.
Printed by Galya Basol Kochav on 1/7/2026 1:55:52 PM. Copyright © 2026 National Comprehensive Cancer Network, Inc. All Rights Reserved.

Management of Locoregional Advanced and/or Metastatic Neuroendocrine Tumors of the Pancreas (Well-Differentiated Grade 1/2)

To evaluate the extent of locoregional advanced disease and/or distant metastases, multiphasic abdomen, with or without pelvis, CT or MRI scans with IV contrast should be performed. SSTR-based imaging is also recommended. A chest CT scan with or without contrast and appropriate biochemical evaluation may be carried out as clinically indicated.

Resection of Locoregional Advanced and/or Distant Metastatic Disease

Metastases in patients with NETs of the pancreas, when they develop, often occur first in the liver. In patients with limited hepatic disease for whom cytoreduction is possible, surgical excision of both the primary tumor and liver metastases with curative intent is recommended when possible and can be performed in a staged or synchronous fashion. See *Principles of Surgical Management of Neuroendocrine Tumors* in the algorithm. A meta-analysis reported that 5-year OS ranges from 41% to 100% in this patient population.[277] When performing staged pancreatoduodenectomy and liver resection, hepatectomy should be considered before pancreatic resection to reduce the risk of perihepatic sepsis from the contaminated biliary tree.[278] Alternatively, use of belzutifan for resectable tumors in the setting of germline *VHL* alteration needs to be individualized (category 2B). Although resection may provide clinical benefit, nearly all patients with metastatic disease will experience recurrence.[279,280] Additional resection or ablation may be possible. A study of 172 patients who had liver resection of metastatic NETs (55 with the primary tumor in the pancreas) showed that significant long-term survival can be achieved after recurrence in many patients, with a 10-year OS rate of 50.4%.[281] If resection is performed for advanced NETs and future treatment with octreotide or lanreotide is anticipated, cholecystectomy is recommended given the association between long-term treatment with SSAs and the development of biliary symptoms and gallstones.[157]

Management of Unresectable Disease- Locally Advanced and/or Distant Metastatic Well-Differentiated Grade 1/2 PanNET

Unfortunately, most patients who present with advanced PanNETs have unresectable disease. For selected patients who are asymptomatic and have low tumor burden and stable disease, observation can be considered, with marker assessment and multiphasic abdomen and pelvis CT or MRI scans every 12 weeks to 12 months until clinically significant disease progression occurs. Chest CT scans with or without contrast may also be performed as clinically indicated. In addition, treatment with octreotide LAR or lanreotide can be considered. The optimal time to begin therapy in this patient population is not known.

For those who initially present with symptomatic disease, clinically significant tumor burden, or clinically significant disease progression, clinically significant symptoms should be managed as appropriate. Octreotide LAR or lanreotide are the most commonly used first-line options. Alternative front-line therapy may be considered in select cases (eg, systemic therapy [discussed below] or locoregional therapy prior to or concurrently with octreotide LAR or lanreotide). First-line PRRT with lutetium Lu 177 dotatate (if SSTR-positive, Ki-67 ≥10%, and clinically significant tumor burden) is also a preferred alternative front-line systemic therapy.

For patients with disease progression, preferred systemic therapy options are cabozantinib (category 1 if prior treatment with everolimus, lutetium Lu 177 dotatate or sunitinib), everolimus (category 1 for progressive disease), sunitinib (category 1 for progressive disease), octreotide LAR or lanreotide (if tumor is SSTR-positive), PRRT with lutetium Lu 177 dotatate (if tumor is SSTR-positive by imaging and progressive on octreotide LAR or lanreotide), and temozolomide plus capecitabine (preferred when tumor response is needed for symptoms or cytoreduction). Other recommended regimens include FOLFOX or CAPEOX for patients with bulky,

Version 3.2025 © 2025 National Comprehensive Cancer Network© (NCCN©), All rights reserved. NCCN Guidelines® and this illustration may not be reproduced in any form without the express written permission of NCCN.

symptomatic, and/or progressive disease. Regimens considered useful in certain circumstances include high-dose (above-label) octreotide LAR or lanreotide if the disease progresses on standard-dose SSA and is SSTR-positive; octreotide LAR or lanreotide for SSTR-negative tumors; consideration of belzutifan in the setting of germline *VHL* alteration in patients with progressive PanNETs; and consideration of RT with or without concurrent fluoropyrimidine-based chemotherapy for locally advanced unresectable disease (excluding small bowel mesenteric). Of note, data for the use of belzutifan for larger tumors, locally advanced tumors, and distant disease are extremely limited. Clinical trials are ongoing (NCT04924075).

Locoregional therapy is also an option (ie, liver-directed therapy for liver-predominant disease; consideration of RT; with or without concurrent fluoropyrimidine-based chemotherapy for locally advanced unresectable disease [excluding small bowel mesenteric]; and palliative RT for oligometastatic disease and/or symptomatic masses [excluding mesenteric masses]).[282]

Symptom Control

Somatostatin Analogs

Patients with PanNETs and symptoms of hormone hypersecretion should, in most cases, receive treatment with either octreotide LAR or lanreotide and/or other medication to manage their symptoms as previously described. The one exception is patients with insulin-producing tumors that are SSTR-negative by imaging (in whom SSA treatment can paradoxically worsen symptoms).[283] For symptom and/or tumor control, octreotide LAR 20–30 mg intramuscularly or lanreotide 120 mg subcutaneously every 4 weeks is recommended. Higher doses have been shown to be safe. Subcutaneous octreotide 100–250 mcg three times daily can be considered for breakthrough symptoms. If injection site-related complications occur, consider switching to another SSA. After clinical, symptomatic, or radiographic progression on standard SSA doses, for symptom and/or tumor control, above-label dosing octreotide LAR (up to 60 mg once a month) or lanreotide (up to 120 mg every 14 days) may be useful in select cases. For patients with insulinoma, octreotide LAR or lanreotide should be used only if SSTR-based imaging is positive, given the risk of worsening hypoglycemia in some patients.

Additional Strategies

Additional strategies may also be considered for control of hormone-mediated symptoms as described in the previous sections, including debulking surgery, locoregional therapy, and agents like PPIs for gastrinomas, and diazoxide, everolimus, and/or cornstarch supplementation for insulinoma.[283,284] For example, the hyperglycemia associated with everolimus can be leveraged to stabilize glucose levels in patients with insulinomas.[285]

Tumor Control

Somatostatin Analogs

Results from the CLARINET study, in which 204 patients with GEP-NETs (including both carcinoid and PanNETs) were randomized to receive treatment with either lanreotide or placebo, showed that treatment with lanreotide was associated with in an improvement in PFS (PFS, not reached vs. 18 months; HR, 0.47; 95% CI, 0.30–0.73; $P < .001$).[160] Although no randomized studies to date have directly shown an antitumor effect of octreotide in PanNETs, the PROMID trial showed an improvement in time to tumor progression (14.3 vs. 6 months; $P = .000072$) compared to placebo in patients with midgut NETs.[158]

Above-Label Dosing

Version 3.2025 © 2025 National Comprehensive Cancer Network© (NCCN©), All rights reserved. NCCN Guidelines® and this illustration may not be reproduced in any form without the express written permission of NCCN.

The phase II CLARINET FORTE study included patients with locally advanced or metastatic grade 1/2 midgut NETs or PanNETs with progression on standard-dose lanreotide (120 mg every 28 days), and demonstrated that a reduction in the dosing interval was feasible.[162] The median PFS was 5.6 months (95% CI, 5.5–8.3) in patients with PanNETs treated with lanreotide at a dose of 120 mg every 14 days for up to 48 weeks. The randomized NETTER-1 (midgut tumors) and NETTER-2 (GEP-NET with Ki-67 index 10%–55%) both compared lutetium Lu 177 dotatate/standard-dose octreotide LAR to above-label octreotide LAR 60 mg/month.[164,166] While PRRT appeared to be superior to high-dose octreotide in both studies, the median PFS in the control arms was 8.4 months in NETTER-1 and 8.5 months in NETTER-2; treatment appeared to be safe with possible cytostatic effect.

Choice of SSA Therapy

Octreotide LAR and lanreotide share the same mechanism of action, and the Panel believes that either octreotide LAR or lanreotide are appropriate options for tumor control. Additional therapies can be given in place of or in addition to octreotide LAR or lanreotide, as discussed below.

SSTR-Negative Disease

A retrospective study by Refardt et al investigated the outcomes of patients with SSTR-negative and SSTR-positive metastatic grade 1 or 2 NETs.[286] In a subgroup analysis of patients treated with SSAs, patients with SSTR-negative NETs were matched to those with SSTR-positive NETs by propensity score. The median OS of patients with SSTR-negative NETs was 39 months, compared to 72 months ($P = .14$) in those with SSTR-positive NETs. PFS was significantly inferior in the former group (15 months vs. 47 months, $P = .006$). The optimal therapy for patients with SSTR-negative disease is unknown, but traditional Lu177 dotatate PRRT is not an option, and the value of SSAs is questionable.

Molecularly Targeted Therapies

The molecularly targeted agents everolimus, sunitinib, and cabozantinib have been confirmed to have antitumor activity and to improve PFS in patients with advanced PanNETs. In addition, as previously noted, belzutifan has activity in localized PanNETs not requiring immediate surgery, in the setting of germline *VHL*.

Everolimus, administered orally at a dose of 10 mg once daily, was evaluated in the randomized phase III RADIANT-3 study, to which 410 patients with advanced, progressive PanNETs were enrolled.[287] In this study, the median PFS duration for patients randomized to everolimus was 11.0 months compared with 4.6 months for patients receiving placebo ($P < .001$; HR, 0.35; 95% CI, 0.27–0.45). The median OS was 44.0 months (95% CI, 35.6–51.8 months) for those treated with everolimus compared to 37.7 months (95% CI, 29.1–45.8 months) to those receiving placebo (HR, 0.94; 95% CI, 0.73–1.20; $P = .30$).[288] A subset analysis of RADIANT-3 suggested that the PFS benefit associated with everolimus is independent of prior or concurrent SSA therapy or prior chemotherapy.[289] Adverse events associated with everolimus include stomatitis, hyperglycemia, rash, diarrhea, and, in rare cases, pneumonitis.[287,288] Other side effects have also been described.[170-172] One report highlighted the outcomes of 169 pretreated patients with advanced NETs of the pancreas (n = 85) or other sites (n = 84) who received everolimus through a compassionate use program.[174] A higher risk of adverse events was noted in patients with previous radiolabeled peptide therapy and chemotherapy.

Sunitinib, an oral VEGF receptor tyrosine kinase inhibitor (TKI) also has activity in PanNETs. In a multicenter randomized study, sunitinib 37.5 mg once daily was compared with placebo in 171 patients with advanced, progressive, metastatic PanNETs.[290] Those assigned to sunitinib had a median PFS duration of 12.6 months (95% CI, 11.1–20.6 months), compared to 5.8 months in patients receiving placebo (95% CI, 3.8–7.2

Version 3.2025 © 2025 National Comprehensive Cancer Network© (NCCN©), All rights reserved. NCCN Guidelines® and this illustration may not be reproduced in any form without the express written permission of NCCN.

PLEASE NOTE that use of this NCCN Content is governed by the End-User License Agreement, and you MAY NOT distribute this Content or use it with any artificial intelligence model or tool.
Printed by Galya Basol Kochav on 1/7/2026 1:55:52 PM. Copyright © 2026 National Comprehensive Cancer Network, Inc. All Rights Reserved.

months; HR, 0.32; 95% CI, 0.18–0.55; *P* = .000015), by blinded independent central review. In the intention-to-treat population, there was no significant difference in OS; median OS was 38.6 months (95% CI, 25.6–56.4 months) for those treated with sunitinib and 29.1 months (95% CI, 16.4–36.8 months) for those treated with placebo (HR, 0.73; 95% CI, 0.50–1.06; *P* = .094), recognizing that 69% of patients on the placebo arm subsequently received sunitinib. Long-term treatment (median 87.1 weeks) did not alter the safety profile.[291] Adverse events associated with sunitinib included fatigue and, in rare cases, congestive heart failure.[292] Other side effects have also been described, including diarrhea, mucositis, and weakness.[293]

More recently, cabozantinib, given at a dose of 60 mg daily, was investigated in the phase III CABINET trial in patients with moderately differentiated or well-differentiated locally advanced or metastatic pancreatic or extrapancreatic NETs. Patients were randomized 2:1 to receive cabozantinib or placebo.[177] Patients with PanNETs had to have had prior treatment with everolimus, sunitinib, or lutetium Lu 177 dotatate PRRT. In the pancreatic cohort, the median PFS was 13.8 months in the cabozantinib arm and 4.4 months in the placebo arm (stratified HR for progression or death, 0.23; 95% CI, 0.12–0.42; *P* < .001). Patients who received cabozantinib had an ORR of 19% (vs. 0% with placebo) and a median OS of 40.0 months (vs. 31.1 months with placebo; HR, 0.95). Overall, 65% of patients in the cabozantinib arm had a grade 3/4 adverse event possibly related to treatment, compared to 23% of patients in the placebo arm. Everolimus and sunitinib received FDA approval for PanNETs in 2011. Cabozantinib was approved for this indication in 2025.

While belzutifan was approved in 2021 for the treatment of VHL disease-associated tumors including PanNETs, the original study focused on patients with renal cell carcinoma (with other germline VHL disease-associated neoplasms) and did not include patients with advanced disease.[261] See the section on nonoperative management for additional information on belzutifan. Treatment with belzutifan yielded an impressive ORR of 91% in 22 patients with concurrent PanNETs.[262] However, limited data exist to support the use of belzutifan in patients with metastatic or locally advanced PanNET.[294] Furthermore, the role of belzutifan in the setting of somatic (but not germline) *VHL* alterations is similarly unclear. Clinical trials are ongoing (eg, NCT04924075).

Cytotoxic Chemotherapy for Advanced Pancreatic Neuroendocrine Tumors (Well-Differentiated Grade 1/2)

Cytotoxic chemotherapy is another option for patients with locoregional advanced or metastatic PanNETs. Oral temozolomide-based therapy is the most commonly used chemotherapy regimen for PanNET, typically in combination with capecitabine. Temozolomide has been administered using different schedules, either alone or in combination with other agents.[181,295-298] In a randomized phase II study (ECOG-ACRIN E2211), patients with advanced low-grade or intermediate-grade PanNETs treated with temozolomide and capcitabine had a median PFS of 22.7 months, compared to 14.4 months for those treated with temozolomide alone (HR, 0.58; *P* = .022).[299] However, the median OS was not significantly different (temozolomide with capecitabine, 58.7 months; temozolomide, 53.8 months; HR, 0.82; *P* = .42). A meta-analysis of 384 patients with advanced NENs reported an OS >12 months and a 73% disease control rate.[300]

Other temozolomide-based combination regimens have been explored. One small study assessed the safety and efficacy of temozolomide administered with bevacizumab, a monoclonal antibody targeted against VEGF.[295] Five of the 15 patients (33%) with PanNETs had a radiographic response (with no responses in the 19 patients with carcinoid tumors), and the toxicity was acceptable. In another single-arm study, the combination of temozolomide (150 mg/m^2 on Days 1–7 and 15–21 of every 28-day

Version 3.2025 © 2025 National Comprehensive Cancer Network© (NCCN©), All rights reserved. NCCN Guidelines® and this illustration may not be reproduced in any form without the express written permission of NCCN.

cycle) plus everolimus (10 mg/day) was found to be safe, with PRs observed in 40% of patients with PanNETs.[301] It should be noted, however, that use of temozolomide was limited to 6 months due to concerns about the risk of selective lymphopenia with the biweekly schedule, and all patients received prophylaxis against *pneumocystis jirovecii* pneumonia (PJP). Currently, the most commonly used regimen remains the 5-day temozolomide regimen alone or in combination with capecitabine, with most capping therapy at 13 cycles.[299]

Other cytotoxic agents also have activity in PanNETs. One study with 89 patients with PanNETs found a PR rate of 30%, a median PFS of 9 months, and a median OS of 30 months,[180] while a smaller study obtained a disease control rate of 78% with the use of FOLFOX.[302] Another study with 48 patients with metastatic enteropancreatic NETs, 33 of whom had PanNETs, reported a disease control rate of 83.3%, a median PFS of 12.6 months, and a median OS of 29.4 months.[303] An ORR of 45.2% was demonstrated in patients with aggressive PanNETs who received multiple prior therapies and were treated with FOLFOX (n = 25) or FOLFOX and bevacizumab (n = 6).[304] The disease control rate was 93.5%, with a median PFS of 6 months (95% CI, 5.0 months–7.0 months), and a median OS of 16 months (95% CI, 11.3 months–20.7 months) and 67 months (95% CI, 49.8 months–84.2 months) from the start of the study and from the time of diagnosis, respectively. The combination of capecitabine and oxaliplatin was assessed in a phase II study, with response rates of 23% in patients with poorly differentiated NETs and 30% in well-differentiated disease.[305] As oxaliplatin-based chemotherapy has shown some promising results,[306] more studies are needed to expand these findings.

Radiolabeled Somatostatin Analogs for Advanced Pancreatic Neuroendocrine Tumors (Well-Differentiated Grade 1/2)

Treatment with radiolabeled SSAs has been reported to result in tumor responses in patients with advanced PanNETs.[184-188] Numerous large, non-randomized cohort analyses have also reported encouraging survival rates with this approach.[191,192,204] In general, these studies have enrolled only patients with evidence of high tumoral SSTR expression. One retrospective study of lutetium Lu 177 dotatate in a group of 610 Dutch patients with metastatic GEP-NETs and bronchial NETs included 133 patients with PanNETs.[204] Patients with a primary NET in the pancreas had the longest OS (71 months) and the ORR was 54% with six patients experiencing a CR. These data, coupled with the results of the randomized NETTER-1 study of high-dose octreotide versus lutetium Lu 177 dotatate plus octreotide LAR in advanced midgut NETs (NETTER-1), led to the approval of lutetium Lu 177 dotatate for SSTR+ GEP-NETs in 2018.[164] Since then, there have been additional reports that treatment with lutetium Lu 177 dotatate can also lead to symptomatic and biochemical responses in patients with functional metastatic PanNETs.[307]

Data from two prospective studies have confirmed the activity of lutetium Lu 177 dotatate-based SSTR PRRT in PanNETs. The OCLURANDOM study was a prospective, randomized, noncomparative phase II study in which patients with SSTR+ PanNETs were randomized to receive lutetium Lu 177 or sunitinib.[308] Overall, 84 patients were enrolled, 37% with a Ki-67 index >10%. The primary endpoint was 12-month PFS by central review. The lutetium Lu 177 dotatate arm was associated with a 12-month PFS rate of 80.5% (90% CI, 67.5%–89.9%) and median PFS of 20.7 months (90% CI, 17.2–23.7 months); the sunitinib arm was associated with a 12-month PFS rate of 42% (90% CI, 29.1%–55.5%) and median PFS of 11 months (90% CI, 8.8–12.4 months). Grade 3/4 adverse events occurred in both groups (lutetium Lu 177 dotatate, sunitinib), with fatigue (7% vs. 12%, respectively), decreased blood counts (12% vs. 24%), and hypertension (12% vs. 19%) being the most common toxicities.

The NETTER-2 study also enrolled patients with PanNETs in a prospective randomized trial for patients with advanced high-risk SSTR+

Version 3.2025 © 2025 National Comprehensive Cancer Network© (NCCN©), All rights reserved. NCCN Guidelines® and this illustration may not be reproduced in any form without the express written permission of NCCN.

GEP-NET (Ki-67 index 10%–55%).[166] A total of 226 patients were randomized 2:1 to lutetium Lu 177 dotatate plus octreotide LAR or octreotide LAR 60 mg/month in the first-line setting. The median Ki-67 index was 16% (range 12%–25%), 65% had G2 disease, and 54% had a PanNET. The primary endpoint was PFS by central review, which was 22.8 months (95% CI, 19.4–not estimated) in the lutetium Lu 177 dotatate group and 8.5 months (95% CI, 7.7–13.8) in the control arm ($P < .0001$). Consistent benefit was observed across all subgroups, including G2 versus G3, pancreas versus non-pancreas versus small intestine primary, providing additional support for PRRT in PanNETs. OS data were not mature at the time of the analysis. Time to deterioration in QOL was similar in both groups. One case of myelodysplasia was noted in the lutetium Lu 177 dotatate plus octreotide LAR group, although further follow-up is needed to fully assess long-term safety.

The Panel recommends PRRT with lutetium Lu 177 dotatate as a treatment option for patients with locoregional advanced PanNETs and/or distant metastases who have symptomatic disease, clinically significant tumor burden, or clinically significant progressive disease, and disease progression on octreotide LAR or lanreotide and with positive SSTR imaging. In the absence of a clear survival benefit and long-term safety data, the use of lutetium Lu 177 dotatate plus octreotide LAR or lanreotide in the first-line setting should be individualized, recognizing that a number of other treatment options have not been directly compared to PRRT (eg, chemotherapy, liver-directed therapy).

Locoregional Therapies for Advanced Neuroendocrine Tumors of the Gastrointestinal Tract and Pancreas (Well-Differentiated Grade 1/2) and Lung/Thymus

Liver-directed therapies are recommended for patients with GI NETs with locoregional advanced and/or distant metastatic, liver-predominant, progressive disease and for those with distant metastatic lung/thymic NETs with clinically significant tumor burden and low grade (typical carcinoid), or evidence of disease progression, or intermediate-grade disease (atypical carcinoid), or symptomatic disease, mainly with the palliative goals of reducing tumor bulk and relieving hormonal symptoms.[309-312] They may also be considered for patients with PanNETs with locoregional advanced and/or distant metastatic, liver-predominant, progressive disease.

Cytoreductive surgery and/or ablative therapies such as radiofrequency ablation (RFA) or cryoablation may be considered if near-complete treatment of tumor burden can be achieved.[313-317] While some groups report that the risks of cytoreductive surgery outweigh its benefits,[318] others have reported good outcomes and marked palliation of hormone-mediated symptoms.[319-321] Debulking therapy in this setting is non-curative, with nearly 100% of patients progressing/recurring by 10 years.[153,279]

Additional options include focal RT (SBRT[322] and stereotactic ablative radiotherapy [SABR]) and hepatic arterial therapies including bland transarterial embolization (TAE),[323] transarterial chemoembolization (TACE),[324-327] and transarterial radioembolization (TARE).[326,328-332]

Data on the use of these interventions are emerging. Whereas embolization in general is considered an effective approach in patients with liver-predominant disease,[309,310,312] only limited data compare the various embolization techniques, and the optimal embolization approach remains uncertain.

Objective radiologic response rates vary widely in retrospective studies, but range from 11% to 100% (TAE/TACE) and 22% to 71% (TARE), with symptom palliation in approximately 39% to 95% of patients with hormonal syndromes.[333-335] The results of one systematic review, encompassing 101 studies and 5545 patients with NENs treated with liver embolization,

Version 3.2025 © 2025 National Comprehensive Cancer Network© (NCCN©), All rights reserved. NCCN Guidelines® and this illustration may not be reproduced in any form without the express written permission of NCCN.

revealed a pooled response rate of 37% and symptom control in approximately 55% of patients.[333] The median PFS was 18 months. No single modality of embolization therapy has been shown to be superior to another, but there is a difference in both long-term and short-term toxicities among the different modalities. Relative contraindications include significant baseline liver dysfunction (eg, jaundice, ascites) and a liver tumor burden >70%. After any prior biliary instrumentation, there are increased risks of infectious complications associated with liver-directed therapies.[336] A study by El-Haddad et al showed that prior Whipple surgery or biliary instrumentation (ie, sphincterotomy, stent) increases the risk of liver abscess due to biliary bacterial colonization; infectious complications occur in about 20% of patients following TAE/TACE and 8% after TARE, even with broad-spectrum antibiotic coverage.[337]

For patients with progressive GI NETs or PanNETs, RT, with or without concurrent fluoropyrimidine-based chemotherapy, may be considered for locally advanced unresectable disease (excluding small bowel mesenteric).[282,338-340] Palliative RT is recommended for oligometastatic disease and/or symptomatic metastases (excluding mesenteric masses). See *Principles of Radiation Therapy* in the algorithm for additional details. For patients with locoregional unresectable lung/thymic NETs, RT is a recommended option for low-grade disease (typical carcinoid), and RT with or without concurrent cisplatin plus etoposide or carboplatin plus etoposide is an option for intermediate-grade disease (atypical carcinoid).

Liver Transplantation Considered Investigational for Liver Metastases of Neuroendocrine Tumors of the Gastrointestinal Tract and Pancreas (Well-Differentiated Grade 1/2)

Several reviews have now reported the results of liver transplantation patients with NETs whose metastases are confined to the liver.[341-345] Results from a multicenter database of 85 patients at 28 centers who underwent liver transplantation for NETs were also reported.[346] A meta-analysis showed that, while 5-year survival rates are encouraging, the majority of patients undergoing liver transplantation ultimately develop recurrence.[347] The Panel acknowledged the considerable associated risks and deemed liver transplantation to be investigational and not part of routine care at this time.

Neuroendocrine Tumors Neoplasms of Unknown Primary

The incidence rate for NETs of an unknown primary site is 0.84 per 100,000 persons according to a SEER database analysis.[1,2] Identification of the primary site can help guide treatment decisions, although there is growing overlap in the treatment of NETs arising in different organ sites.[348,349] If the primary tumor cannot be identified, treatment decisions are generally guided by tumor histology (see *Histologic Classification and Staging of Neuroendocrine and Adrenal Tumors*, above). Metastatic well-differentiated NETs are often treated like midgut tumors, since it is well documented that occult primary tumors can be often be found in the small bowel.[350,351]

Evaluation of Neuroendocrine Neoplasms of Unknown Primary

The initial evaluation of a patient with biopsy-proven NENs of unknown primary includes family history, clinical manifestations, laboratory studies, imaging studies, and/or immunohistochemical studies.

Given some differences in systemic treatment approaches for extrapancreatic NETs and PanNETs, establishing whether a patient has a primary PanNET can have important treatment implications (eg, greater role for chemotherapy). Tumor-localizing studies include imaging studies, such as chest CT scans with or without contrast, and multiphasic abdomen and pelvis CT or MRI scans. SSTR-based imaging may be very helpful in localizing primary NETs.[107,352] An FDG-PET/CT or PET/MRI scan with or without brain imaging with contrast (CT or MRI) can occasionally be useful in finding a primary tumor, but are less sensitive in well-

Version 3.2025 © 2025 National Comprehensive Cancer Network© (NCCN©), All rights reserved. NCCN Guidelines® and this illustration may not be reproduced in any form without the express written permission of NCCN.

differentiated NETs and should only be considered in cases of poorly differentiated tumors.

EGD or EUS and/or colonoscopy can be considered in selected cases. Most of the time, primary tumors are obvious on DOTA PET scans. See *Principles of Imaging* in the algorithm. It is common for small bowel NETs to be small and difficult to visualize, although in some cases imaging may demonstrate an associated, sometimes calcified, mesenteric mass. Exploratory surgery is not routine for purely diagnostic purposes. However, if a small bowel primary tumor is suggested by symptoms and radiologic findings and if metastases can be optimally debulked, surgery can be considered (being careful to run the small bowel to assess for occult, and sometimes multiple primary tumors).[351] Biochemical testing should be done as appropriate.

Treatment of Neuroendocrine Neoplasms of Unknown Primary

In the absence of a primary tumor identified in the pancreas, well-differentiated grade 1/2 tumors should be treated similarly to locoregional advanced disease and/or distant metastases of the GI tract, as described above. This is especially true for patients with liver-dominant metastases and/or prominent mesenteric lymphadenopathy. If the primary tumor is found, treatment should be according to the specific tumor type. If the primary tumor is not identified, poorly differentiated NENs should be treated as described for *Extrapulmonary Poorly Differentiated: Neuroendocrine Carcinoma/Large or Small Cell Carcinoma/Mixed Neuroendocrine-Non-Neuroendocrine Neoplasm*, below.
Well-differentiated grade 3 tumors should be managed and treated as described below in the *Well-Differentiated Grade 3 Neuroendocrine Tumors* section.

Well-Differentiated Grade 3 Neuroendocrine Tumors

Well-differentiated G3 NETs were introduced as a new category in the 2017 WHO classification update of pancreatic NENs, and in the 2019 WHO classification for digestive system (GEP) NENs (including unknown primary tumors).[14,353] These encompass tumors that have a high proliferation rate, with a mitotic index >20 mitoses per 2 mm^2 or a Ki-67 index >20%, and a well-differentiated morphology.[354] These occur mostly in the pancreas, stomach, and colon, although they can occur at any primary site. Well-differentiated G3 tumors have an intermediate prognosis compared to PDNECs and G1–G2 well-differentiated NETs.[2,45,355] Well-differentiated G3 tumors have an intermediate prognosis compared to PDNECs and G1–G2. The results from two studies showed that patients with well-differentiated G3 NETs had a significantly higher median OS (41–99 months vs. 17 months) compared to patients with PDNECs.[356,357]

Evaluation of Well-Differentiated Grade 3 Neuroendocrine Tumors

Imaging with multiphasic abdomen/pelvis CT or MRI scans with contrast, chest CT scans (as clinically indicated), and SSTR-based PET imaging (SSTR-PET) is recommended. SSTR-based PET imaging should include PET/CT or PET/MRI of the skull vertex to mid-thigh with multiphase IV contrast (both arterial and portal venous phase), when possible. FDG-PET/CT scans can be performed if SSTR-PET imaging is negative. And, both FDG-PET and DOTATATE-PET should be considered if treatment with lutetium Lu 177 dotatate PRRT is being considered, given the potential impact of FDG avidity on prognosis.[358-360] Biochemical evaluation should be performed as clinically indicated if the patient has symptoms suggestive of a secretory tumor. Pathology review is also recommended, recognizing the potential difficulty distinguishing G3 NET from large cell NEC (see *Principles of Pathology* in the algorithm).[4,361] A subgroup of G3 NETs arises in the setting of apparent grade progression over time; as such, a prior history of G1 or G2 NET strongly favors G3 NET (over NEC)

Version 3.2025 © 2025 National Comprehensive Cancer Network© (NCCN©), All rights reserved. NCCN Guidelines® and this illustration may not be reproduced in any form without the express written permission of NCCN.

if G3 disease is confirmed. Assessment of p53, Rb, and p16, by histopathologic analysis or molecular profiling, can be considered if there is uncertainty about the tumor's degree of differentiation, as a mutation in these genes would suggest a PDNEC.[4,362-364] SSTR 2A staining may also be helpful.[365] Tumor/somatic molecular profiling should be considered for patients with locoregional unresectable or metastatic disease who are candidates for anti-cancer therapy to identify actionable alterations. Testing on tumor tissue is preferred; however, liquid biopsy can be considered if tumor tissue testing is not feasible. As appropriate, genetic counseling and testing for inherited genetic syndromes is recommended for duodenal NETs or PanNETs.

Treatment of Well-Differentiated Grade 3 Neuroendocrine Tumors

Treatment recommendations are based on the biology of the tumor. A tumor with favorable biology typically possesses Ki-67 <55%, is slower-growing, and has a positive SSTR-based PET result. A tumor with unfavorable biology typically has Ki-67% ≥55%, is faster-growing, and may yield a negative SSTR-based PET result (and shows positive uptake on FDG-PET). Importantly, the data informing the appropriate Ki-67 cutoff are limited and variability/heterogeneity of Ki-67 in a given tumor and over time in serial biopsies makes decision-making less straightforward in this entity compared to other NENs. The clinical course can be heterogeneous and treatment considerations need to account for both pathologic and clinical features.

Locoregional Resectable Disease

For locoregional (resectable) disease, upfront resection is recommended, along with regional lymphadenectomy, if feasible, regardless of tumor biology but is particularly recommended if there is favorable tumor biology (slow-growing, positive SSTR-based PET imaging, Ki-67 index <55%).[366] Patient factors should also be considered. For resectable locoregional disease with unfavorable biology, a clinical trial is preferred. Neoadjuvant chemotherapy can be given on a case-by-case basis for these patients and options include cisplatin/etoposide or carboplatin/etoposide, oxaliplatin-based therapy (FOLFOX or CAPEOX), or temozolomide with or without capecitabine. Temozolomide, with or without capecitabine, may have more activity in tumors arising in the pancreas compared to GI NETs. Following the completion of neoadjuvant chemotherapy, the patient should undergo resection with regional lymphadenectomy if feasible.

Locally Advanced/Metastatic Grade 3 NET-Favorable Biology

For resectable locally advanced or metastatic disease with favorable biology, resection of the primary and metastatic sites may be performed, if feasible, with acceptable risk and toxicity profile. The treatment for unresectable locally advanced or metastatic tumors with favorable biology depends on the degree of tumor burden and the primary site (if primary tumor in place). If the patient is asymptomatic with low tumor burden, there are several options: observation with a short-interval follow-up scan is an option for select patients; octreotide LAR or lanreotide is an option if the patient has SSTR-positive tumors and/or has hormonal symptoms; PRRT with lutetium 177 dotatate is an option for SSTR-positive tumors (category 2B); and palliative RT is an option for oligometastatic disease and/or symptomatic metastases (excluding mesenteric masses).[367]

There are multiple treatment modalities if the patient has favorable biology but clinically significant tumor burden or evidence of disease progression. Enrollment in a clinical trial is preferred. Other recommended treatment options include systemic therapy or locoregional therapy. Systemic therapy options include cabozantinib[177]; chemotherapy (temozolomide, with or without capecitabine,[368,369] FOLFOX, CAPEOX, cisplatin/etoposide, or carboplatin/etoposide); everolimus; octreotide LAR or lanreotide (if the patient has SSTR-positive disease and/or has hormonal symptoms); consideration of pembrolizumab for patients with microsatellite instability-high (MSI-H), mismatch repair deficient (dMMR), or advanced

Version 3.2025 © 2025 National Comprehensive Cancer Network© (NCCN©), All rights reserved. NCCN Guidelines® and this illustration may not be reproduced in any form without the express written permission of NCCN.

tumor mutational burden-high (TMB-H) tumors (≥10 mutations/megabase [mut/Mb] and as determined by an FDA-approved test) that have progressed following prior treatment and have no satisfactory alternative treatment options[370,371]; PRRT with lutetium Lu 177 dotatate (if the tumor is SSTR-positive); sunitinib (pancreas only); and consideration of RT, with or without concurrent fluoropyrimidine-based chemotherapy for locally advanced unresectable disease. For symptom and/or tumor control, octreotide LAR 20–30 mg intramuscularly or lanreotide 120 mg subcutaneously every 4 weeks is recommended. Higher doses have been shown to be safe and above-label octreotide LAR (60 mg/month) was the control arm for the NETTER-2 study, which included grade 3 NET (Ki-67 >20 to ≤55%).[166] Subcutaneous octreotide 100–250 mcg three times daily can be considered for breakthrough symptoms. If injection site-related complications occur, consider switching to another SSA.

In the phase III CABINET trial, patients with pancreatic or extrapancreatic NETs were randomized 2:1 to receive cabozantinib or placebo.[177] Although the numbers were small (N = 13 extrapancreatic G3 NET, N = 11 pancreatic G3 NET), a subgroup analysis showed that treatment with cabozantinib improved the HR for disease progression or death in patients with grade 3 NETs in both the pancreatic (HR, 0.02) and extrapancreatic (HR, 0.79) cohorts. As such, cabozantinib is an option for patients with locally advanced/metastatic G3 NETs (unresectable with clinically significant tumor burden or evidence of disease progression) with favorable biology.

Emerging data suggest SSTR-based PRRT also has activity in G3 NETs.[372,373] One small study reported outcomes in patients with heavily pretreated, progressive, well-differentiated G3 NETs treated with lutetium Lu 177 dotatate.[374] Out of 18 evaluable patients, 28% had a PR, 44% had stable disease, and 28% experienced disease progression. The disease control rate was 72% and the median PFS was 13.1 months. PRRT has also been evaluated in the first-line setting (NETTER-2 study) in patients with advanced high-risk SSTR+ GEP-NETs (Ki-67 index 10%–55%).[166] A total of 226 patients were randomized 2:1 to lutetium Lu 177 dotatate plus octreotide LAR or octreotide LAR 60 mg/month in the first-line setting. The median Ki-67 index was 16% (range 12%–25%), 65% had G2 disease, and 54% had a PanNET. The primary endpoint was PFS by central review, which was 22.8 months (95% CI, 19.4–not estimated) in the lutetium Lu 177 dotatate-treated group and 8.5 months (95% CI, 7.7–13.8) in the control arm ($P < .0001$). Consistent benefit was observed across all subgroups, including G2 versus G3 NET, and pancreas versus non-pancreas versus small intestine primary. OS data were not mature at the time of the analysis. Time to deterioration in QOL was similar in both groups. One case of myelodysplasia was noted in the lutetium Lu 177 dotatate plus octreotide LAR group, although further follow-up is needed to full assess long-term safety.

After clinical, symptomatic, or radiographic progression on standard SSA doses, for symptom and/or tumor control, above-label dosing of octreotide LAR (up to 60 mg once a month) or lanreotide (up to 120 mg every 14 days) may be useful in selected cases (category 2B). However, it should be noted that most studies assessing high-dose SSAs have focused on patients with low-risk tumors.[162,164,165] In contrast, the NETTER-2 study enrolled patients with G2 and G3 GEP-NET (Ki-67 index 20%–55%), although the median Ki-67 index was only 17%.[166] Furthermore, octreotide LAR 60 mg/month was inferior to Lu 177 dotatate PRRT (as measured by PFS) in that study.

Temozolomide, with or without capecitabine, may have more activity in tumors arising in the pancreas compared to GI NETs. Evolving data suggest that well-differentiated tumors with intermediate Ki-67 levels (in the 20%–55% range) may not respond as well to platinum/etoposide as patients with higher Ki-67 (>55%).[51] A few studies reported that treatment

Version 3.2025 © 2025 National Comprehensive Cancer Network© (NCCN©), All rights reserved. NCCN Guidelines® and this illustration may not be reproduced in any form without the express written permission of NCCN.

PLEASE NOTE that use of this NCCN Content is governed by the End-User License Agreement, and you MAY NOT distribute this Content or use it with any artificial intelligence model or tool.
Printed by Galya Basol Kochav on 1/7/2026 1:55:52 PM. Copyright © 2026 National Comprehensive Cancer Network, Inc. All Rights Reserved.

with platinum-based chemotherapy yielded almost no response (0%–2% response rate).[356,357,375]

In a retrospective study of patients with grade 3 NETs evaluating the efficacy of various first-line therapies, FOLFOX was found to have the highest ORR (56.4%).[376] Treatment with platinum (carboplatin or cisplatin)/etoposide or capecitabine/temozolomide resulted in ORRs of 35.1% and 27.3%, respectively. However, capecitabine/temozolomide had the longest median PFS (12.0 months). The median PFS was 6.9 months for platinum/etoposide and FOLFOX. Another retrospective study investigated the efficacy of capecitabine/temozolomide in patients with unresectable/metastatic grade 3 GEP NENs.[369] Ninety-two percent of patients were treated with capecitabine/temozolomide and 8% of patients were treated with temozolomide monotherapy. Among patients with well-differentiated grade 3 NETs, the time to treatment failure was 5.7 months. The OS was 31.7 months and the response rate was 41%. In a retrospective study of 35 patients with advanced high-grade NENs of gastroenteropancreatic origin or of unknown origin treated with frontline mFOLFIRINOX, 77% of patients achieved an objective response (79% in 14 patients with Ki-67 <55%).[377] The median OS and median PFS were 20.6 months (95% CI, 17.2–30.6 months) and 12 months (95% CI, 9.2–16.2 months) respectively. However, only 2 out of 35 patients had grade 3 NETs; thus, the efficacy in this group is not known.

Locoregional therapy options are liver-directed therapy for favorable biology liver-dominant disease; palliative RT for oligometastatic disease and/or symptomatic metastases[367]; and consideration of RT, with or without concurrent fluoropyrimidine-based chemotherapy for locally advanced unresectable disease.[378]

Locally Advanced/Metastatic Grade 3 NET- Unfavorable Biology

In the event of locally advanced or metastatic disease with unfavorable biology, a clinical trial is a preferred option. Cytostatic agents like oral small molecules (everolimus, sunitinib, SSAs) are predicted to be less effective in the setting of G3 NETs with unfavorable biology, although formal studies are lacking in this specific population. Chemotherapy is often employed. In addition to regimens used for G3 NETs with favorable biology, other options in this setting include irinotecan-based therapies (eg, FOLFIRI, cisplatin/irinotecan, FOLFIRINOX), extrapolating from NEC,[377,379-382] although the data for G3 NETs specifically are limited. Other options include the combination of nivolumab and ipilimumab (category 2B) (ORR approximately 15%–25%), recognizing that some of the studies assessing this combination did not distinguish between G3 NETs and NECs.[383-386] Nivolumab and hyaluronidase-nvhy is not approved for concurrent use with IV ipilimumab; however, for nivolumab monotherapy, nivolumab and hyaluronidase-nvhy subcutaneous injection may be substituted for IV nivolumab. Nivolumab and hyaluronidase-nvhy has different dosing and administration instructions compared to IV nivolumab. Single-agent pembrolizumab can be considered for patients with MSI-H, dMMR, or advanced TMB-H tumors (≥10 mut/Mb and as determined by an FDA-approved test) that have progressed following prior treatment and have no satisfactory alternative treatment options.[370,371]

For patients with locally advanced or metastatic disease with unfavorable biology, locoregional therapy options include consideration of RT, with or without concurrent fluoropyrimidine-based chemotherapy, for locally advanced unresectable disease; consideration of liver-directed therapies[322] for selected cases of liver-predominant disease after systemic therapy; and palliative RT for oligometastatic disease and/or symptomatic metastases (excluding mesenteric masses).

Version 3.2025 © 2025 National Comprehensive Cancer Network© (NCCN©), All rights reserved. NCCN Guidelines® and this illustration may not be reproduced in any form without the express written permission of NCCN.

Surveillance of Well-Differentiated Grade 3 Neuroendocrine Tumors

Surveillance for resectable locoregional or locally advanced disease consists of a routine patient H&P examination along with appropriate imaging studies (multiphasic abdomen/pelvis CT or MRI scans with contrast and chest CT scans [as clinically indicated]) every 12 to 24 weeks for the first 2 years and every 6 to 12 months thereafter, for up to 10 years. Patients with unresectable locally advanced or metastatic disease with favorable biology should be monitored every 12 to 24 weeks (depending on tumor biology), with an H&P and multiphasic abdomen/pelvis CT or MRI with contrast. A chest CT, with or without contrast, as well as SSTR-PET/CT or SSTR-PET/MRI or FDG-PET/CT scans, and biochemical markers, are also recommended as clinically indicated. Patients with unresectable locally advanced or metastatic disease with unfavorable biology should be followed similarly (except for SSTR imaging), and the interval for initial scans should be every 8 to 12 weeks (depending on tumor biology).

Extrapulmonary Poorly Differentiated: Neuroendocrine Carcinoma/Large or Small Cell Carcinoma/Mixed Neuroendocrine-Non-Neuroendocrine Neoplasm

Although rare, extrapulmonary PDNECs can occur in a wide variety of organs. They are characterized by a high mitotic index and high Ki-67 index. The most aggressive of these tumors histologically resemble classic small cell carcinoma of the lung. The most frequent organs involved are the cervix, esophagus, pharynx and larynx, colon, rectum, prostate, pancreas, and bladder.[387] Most extrapulmonary PDNECs are aggressive and require combined multimodality treatment, usually following a treatment paradigm that parallels the treatment of small cell lung cancer. These tumors are rarely associated with a hormonal syndrome. Gastrointestinal tumors with mixed histology of poorly differentiated adenocarcinoma can be treated according to the NCCN Guidelines for Colon Cancer and Pancreatic Adenocarcinoma (available at www.NCCN.org) depending on their clinical course.

Results from a SEER database analysis of NECs found that 9% were extrapulmonary.[387] The median survival for all NECs was 7.7 months. Compared to other primary NECs (26.0%), the survival was lower for lung NECs (5.6%) and GI NECs (13.1%) at 5 years. The median survival of patients with GI NECs was 7.5 months, with patients with small intestine tumors doing better (25.1 months) than patients with pancreatic NECs (5.7 months) and those arising in an unknown primary site (2.5 months).

Evaluation of Extrapulmonary Poorly Differentiated: Neuroendocrine Carcinoma/Large or Small Cell Carcinoma/Mixed Neuroendocrine-Non-Neuroendocrine Neoplasm

Multiphasic chest/abdomen/pelvis CT or chest CT and abdomen/pelvis MRI are recommended as baseline staging studies. Brain imaging with MRI or CT scan with contrast and/or FDG-PET should be performed as clinically indicated, and should be considered routinely in PDNECs of the thorax and neck. Biochemical markers are recommended if symptoms are suggestive of a secretory tumor. SSTR-based imaging is not part of the routine evaluation of PDNECs. Tumor/somatic molecular profiling should be considered for patients with locoregional unresectable or metastatic disease who are candidates for anticancer therapy to identify actionable alterations. Testing can be specifically considered for potentially actionable somatic findings including, but not limited to: *NTRK* fusions, *RET* fusions, *BRAF* V600E mutations, MSI-H, MMR deficiency, and TMB-H. Testing on tumor tissue is preferred; however, liquid biopsy can be considered if tumor tissue testing is not feasible.

Version 3.2025 © 2025 National Comprehensive Cancer Network© (NCCN©), All rights reserved. NCCN Guidelines® and this illustration may not be reproduced in any form without the express written permission of NCCN.

PLEASE NOTE that use of this NCCN Content is governed by the End-User License Agreement, and you MAY NOT distribute this Content or use it with any artificial intelligence model or tool.
Printed by Galya Basol Kochav on 1/7/2026 1:55:52 PM. Copyright © 2026 National Comprehensive Cancer Network, Inc. All Rights Reserved.

Treatment of Extrapulmonary Poorly Differentiated: Neuroendocrine Carcinoma/Large or Small Cell Neuroendocrine Carcinoma/Mixed Neuroendocrine-Non-Neuroendocrine Neoplasm

Poorly differentiated NECs are often associated with non-neuroendocrine components such as adeno or squamous cell carcinoma. Management of these tumors is controversial. Chemotherapy regimens for non-neuroendocrine components may be considered, although platinum-based therapy remains standard.

For resectable extrapulmonary poorly differentiated NECs/large or small cell carcinomas/MiNENs, treatment options depend on the disease site. Such options may include surgical resection and adjuvant chemotherapy with or without RT; neoadjuvant chemotherapy with or without RT and with resection; chemotherapy alone; and definitive chemoradiation (with cisplatin/etoposide or carboplatin/etoposide). For locoregional unresectable disease, concurrent or sequential RT in combination with chemotherapy, or chemotherapy alone are recommended. Chemoradiation options include capecitabine (when etoposide in combination with platinum is not feasible), carboplatin plus etoposide, or cisplatin plus etoposide.[378,388-392]

If metastatic disease is present, chemotherapy alone is recommended. Cytotoxic chemotherapy regimens for resectable, locoregional unresectable, or metastatic disease include carboplatin/etoposide,[393] cisplatin/etoposide,[203,394] FOLFIRI,[379] FOLFOX,[395] and temozolomide[396] with or without capecitabine.[397] For locoregional unresectable or metastatic disease, additional chemotherapy options include carboplatin/irinotecan, cisplatin/irinotecan,[394] and FOLFIRINOX.[377,381,382] Carboplatin/etoposide[393] and cisplatin/etoposide are most commonly used in first-line therapy.[203,394]

While the use of concomitant immunotherapy is standard in small cell lung cancer, it remains experimental in extrapulmonary NEC, although studies are ongoing (NCT05058651). The phase II NICE-NEC trial investigated the use of nivolumab in combination with carboplatin and etoposide in patients with advanced grade 3 NENs of GEP or unknown origin, 67.6% of whom had poorly differentiated NECs and/or Ki-67 index >55%.[398] The ORR was 56.8% among evaluable patients and 60.0% among those with NECs. The median OS and PFS were 13.9 months and 5.7 months, respectively. In addition, carboplatin/irinotecan and cisplatin/irinotecan[394] have potential utility.[377,381,382] The phase III TOPIC-NEC randomized trial comparing the effectiveness of etoposide plus cisplatin or irinotecan plus cisplatin in patients with advanced NECs of the digestive system showed that both regimens were comparable in terms of the median OS (etoposide/cisplatin: 12.5 months, irinotecan/cisplatin: 10.9 months; HR, 1.04; P = .80) and median PFS (etoposide/cisplatin: 5.6 months, irinotecan/cisplatin: 5.1 months; HR, 1.06; P = .80).[380] The authors noted that grade 3 and 4 adverse events occurred more frequently in patients treated with etoposide plus cisplatin.

It should be noted though that the efficacy of second-line or later lines of chemotherapy is very limited and survival is short.[399] Available data are insufficient to guide selection of one chemotherapy regimen over another, although comorbidities, mutation profile, and site of primary often factor in to the decision.

The combination of ipilimumab and nivolumab (category 2B) is also an option for metastatic disease if the disease progresses following chemotherapy.[384-386,400] The results of one phase II study (S1609 DART) revealed an ORR of 44% in patients with non-pancreatic high-grade NECs (including lung primaries) treated with combined ipilimumab and nivolumab.[385] Subsequent data from an additional cohort of patients (N = 19) with high-grade NENs (median Ki-67, 80%) revealed an ORR of 26% and a 6-month PFS of 32%.[386] The median PFS was 2.0 months and the median OS was 8.7 months. The subgroup analysis of the CA209-538

Version 3.2025 © 2025 National Comprehensive Cancer Network© (NCCN©), All rights reserved. NCCN Guidelines® and this illustration may not be reproduced in any form without the express written permission of NCCN.

PLEASE NOTE that use of this NCCN Content is governed by the End-User License Agreement, and you MAY NOT distribute this Content or use it with any artificial intelligence model or tool.
Printed by Galya Basol Kochav on 1/7/2026 1:55:52 PM. Copyright © 2026 National Comprehensive Cancer Network, Inc. All Rights Reserved.

trial, centered on patients with advanced NENs who received the combined treatment, demonstrated an ORR of 24%.[384] The median PFS was 4.8 months and the OS was 14.8 months. Immune-related toxicity occurred in 66% of cases. Importantly, data from the multi-cohort phase II DUNE study (N = 123) of durvalumab plus tremelimumab for patients with advanced NENs of GEP or lung origin suggested only modest activity (irRECIST ORR 9.1%) in G3 GEP NENs.[401] The OS rate for these patients at 9 months was 36.1%. Furthermore, results of the NIPINEC study in which single-agent nivolumab was compared to combination therapy with nivolumab/ipilimumab revealed an ORR of 7.2% (median OS, 7.2 months; median PFS, 1.8 months) at 8 weeks with nivolumab, compared to an ORR of 14.9% (median OS, 5.8 months; median PFS, 1.9 months) with nivolumab/ipilimumab. Nivolumab and hyaluronidase-nvhy is not approved for concurrent use with IV ipilimumab; however, for nivolumab monotherapy, nivolumab and hyaluronidase-nvhy subcutaneous injection may be substituted for IV nivolumab. Nivolumab and hyaluronidase-nvhy has different dosing and administration instructions compared to IV nivolumab.

Some extrapancreatic NECs harbor an actionable mutation. Finally, pembrolizumab can also be considered for patients with dMMR, MSI-H, or TMB-H (≥10 mut/Mb as determined by an FDA-approved test) tumors that have progressed following prior treatment and have no satisfactory alternative treatment options.[370,371,402 401]

Targeted therapy is recommended based on the molecular alteration. Dabrafenib in combination with trametinib can be considered for patients with *BRAF* V600E mutation-positive tumors that have progressed following prior treatment and have no satisfactory alternative treatment options.[403] Entrectinib, larotrectinib, and repotrectinib can be considered for patients with *NTRK* gene fusion-positive tumors without a known acquired resistance mutation, that are metastatic or where surgical resection is likely to result in severe morbidity, and that have no satisfactory alternative treatments or that have progressed following treatment.[404-407] Repotrectinib can also be considered for patients with *NTRK* gene fusion-positive tumors that progressed on a prior *NTRK*-targeted treatment.[407] Selpercatinib can be considered for patients with *RET* gene fusion-positive tumors that have progressed on or following prior systemic treatment or who have no satisfactory alternative treatment options.[408]

Surveillance of Extrapulmonary Poorly Differentiated: Neuroendocrine Carcinoma/Large or Small Cell Carcinoma/Mixed Neuroendocrine-Non-Neuroendocrine Neoplasm

For patients with resectable disease, surveillance after treatment completion consists of a routine H&P along with appropriate imaging studies (chest CT with or without contrast and abdomen/pelvis MRI with contrast or multiphasic chest/abdomen/pelvis CT) every 12 weeks for the first year and every 6 months thereafter. However, patients with locoregional, unresectable disease and with metastatic disease should be monitored more closely every 6 to 16 weeks with an H&P and appropriate imaging studies as described above.

Adrenal Gland Tumors

Approximately 60% of patients present with evidence of adrenal steroid hormone excess, with or without virilization.[21] Signs and symptoms associated with hypersecretion of cortisol, called hypercortisolemia (± Cushing syndrome), include weight gain, weakness (primarily in proximal muscles), hypertension, psychiatric disturbances, hirsutism, centripetal obesity, purple striae, dorsocervical fat pad and supraclavicular fat pad enlargement, hyperglycemia, and hypokalemia. Aldosterone-secreting tumors may present with hypertension, weakness, and hypokalemia. Androgen-secreting tumors in females may induce hirsutism, virilization, deepening of the voice, and oligo/amenorrhea.[21] In males, estrogen-secreting tumors may induce gynecomastia and testicular

Version 3.2025 © 2025 National Comprehensive Cancer Network© (NCCN©), All rights reserved. NCCN Guidelines® and this illustration may not be reproduced in any form without the express written permission of NCCN.

PLEASE NOTE that use of this NCCN Content is governed by the End-User License Agreement, and you MAY NOT distribute this Content or use it with any artificial intelligence model or tool.
Printed by Galya Basol Kochav on 1/7/2026 1:55:52 PM. Copyright © 2026 National Comprehensive Cancer Network, Inc. All Rights Reserved.

atrophy. Hormonally inactive ACCs typically produce symptoms related to tumor burden, including abdominal pain, back pain, early satiety, and weight loss.[21]

Evaluation and Treatment of Adrenal Gland Tumors

All patients with adrenal gland tumors need biochemical evaluation and appropriate imaging. Biochemical evaluation to evaluate for primary aldosteronism, hypercortisolemia (± Cushing syndrome), PCC, and androgen excess should be done with every adrenal mass. Comprehensive guidelines for the workup of adrenal tumors, adrenal incidentalomas, hyperaldosteronism, Cushing syndrome, and PCC and PGL are published through the Endocrine Society[409,410] and the European Society of Endocrinology (ESE).[18,411]

NCCN recommends doing a morphologic evaluation of adrenal nodules with adrenal protocol CT scan: non-contrast CT (if Hounsfield unit [HU] <+10, no further imaging and no screening for PCC is needed; if HU >+10, proceed with contrast CT with washout [depending on HU and imaging characteristics, additional imaging and workup may be indicated])[412] or MRI with and without contrast. Functional evaluation should be done as noted above. ACCs can oftentimes secrete multiple hormones; therefore, if imaging is suspicious for ACC, evaluation for sex steroid in addition to the above evaluation is indicated. If several hormones are over-secreted, ACCs are more likely.

History of a primary cancer outside of the adrenal gland raises the question of metastatic disease to the adrenals. However, it is very important that PCC is ruled out prior to considering diagnostic biopsy of the adrenal mass. In these patients, an image-guided needle biopsy can be considered only if clinical suspicion for PCC is low; plasma or urine fractionated metanephrines, with or without catecholamines, are normal; and the results will impact disease management. False-negative biopsies are possible; therefore, proceeding directly to surgery should be considered in some cases. If the tumor is determined to be a metastasis from another site, treatment should be according to the appropriate NCCN disease-specific treatment guideline (to see Treatment by Cancer Type, go to www.NCCN.org). If biopsy reveals adrenocortical tissue, then functional evaluation should proceed as described here.

Evaluation and Treatment of Primary Aldosteronism

When primary aldosteronism is suspected, plasma aldosterone and plasma renin activity should be assessed. Patients with primary aldosteronism have elevated plasma levels of aldosterone and low levels of renin activity. The plasma aldosterone-to-renin ratio in patients with primary aldosteronism is usually >30.[409] Confirmatory testing is recommended if positive results are obtained. Oral or IV salt loading and measurement of urine or plasma aldosterone is recommended to test for adequate suppression.[413] Serum electrolytes should also be measured, because excessive aldosterone production causes both sodium retention and potassium excretion. The Endocrine Society has developed detailed guidelines for the detection, diagnosis, and treatment of primary aldosteronism,[409] and these guidelines have been modified over time.[414,415]

Benign primary aldosteronism is much more common and can be caused by a unilateral adrenal adenoma or bilateral adrenal hyperplasia. Adrenal vein sampling for aldosterone can be considered for distinguishing these two causes of benign primary aldosteronism and should be considered if the patient is a surgical candidate, because CT imaging cannot always differentiate between an adenoma and hyperplasia. It may be reasonable, however, to exclude adrenal vein sampling in patients <40 years when imaging only shows one affected gland, because bilateral hyperplasia is rare in this population. Cortisol measurement in the catheterization samples is used to confirm proper catheter placement. Minimally invasive adrenalectomy is recommended for adenoma,[416] whereas medical management with spironolactone or eplerenone for hypertension and

Version 3.2025 © 2025 National Comprehensive Cancer Network© (NCCN©), All rights reserved. NCCN Guidelines® and this illustration may not be reproduced in any form without the express written permission of NCCN.

hypokalemia is recommended for patients with bilateral adrenal hyperplasia and for nonsurgical candidates.

Evaluation and Treatment of Hypercortisolemia (± Cushing Syndrome)

Patients who present with symptoms of hypercortisolemia (± Cushing syndrome) should be evaluated for evidence of hypercortisolemia with one of the following tests: 1) overnight 1-mg dexamethasone suppression test; 2) 2 to 3 midnight salivary cortisol measurements; or 3) free cortisol in a 24-hour urine sample.[410,417] Elevated levels of cortisol are indicative of hypercortisolemia (± Cushing syndrome). If a diagnosis of hypercortisolemia (± Cushing syndrome) is confirmed, plasma ACTH should be checked in the morning to determine if it is ACTH-dependent or ACTH-independent (ACTH <5 pg/mL). Adrenal masses that secrete cortisol are not mediated by ACTH (ACTH independent), and ACTH-dependent tumors can arise in the pituitary or ectopic NET sources. If a clear pituitary adenoma is not visible by MRI, inferior petrosal sinus vein sampling can be considered to differentiate adrenal from pituitary and ectopic causes in ACTH-dependent hypercortisolemia (± Cushing syndrome). Endocrinology referral should be considered for the biochemical workup, localization of hypercortisolemia, and medical therapy for hypercortisolism until more definitive therapy can be arranged.

Hypercortisolemia (± Cushing syndrome) can be associated with either benign adrenal tumors (adrenal adenoma) or malignant adrenal tumors. Malignancy should be suspected if the tumor is >4 cm or is inhomogeneous with irregular margins and/or has local invasion or other malignant imaging characteristics. Some centers may use 6 cm as a cutoff instead of 4 cm. For these tumors, FDG-PET/CT scans, chest CT scans with or without contrast, and adrenal protocol CT scan (as previously described or MRI with and without contrast) are recommended. Benign adrenal tumors (ie, <4 cm, contralateral gland normal, circumscribed tumor, other benign imaging characteristics) should be resected. It is important that patients who have cortisol-secreting adrenal tumor receive perioperative glucocorticoids since the contralateral adrenal secretion will be transiently suppressed. For more details, see the Endocrine Society's Clinical Practice Guidelines for the Treatment of Cushing Syndrome.[410]

Treatment of Nonfunctioning, Benign Adrenal Tumors

Adrenal tumors that do not secrete hormones are often discovered incidentally during scans for unrelated reasons (incidentalomas). It is still important to evaluate for biochemical secretion of hormones for primary aldosteronism, hypercortisolemia (± Cushing syndrome), and PCC and PGL as listed above to confirm they are non-secreting. Most nonfunctioning tumors are benign and can be left untreated. Masses showing radiographic features of myelolipoma are considered benign. In addition, tumors <4 cm that are homogenous, with smooth margins, and that appear lipid-rich according to CT or MRI criteria are also usually benign. A minimally invasive adrenalectomy is preferred for tumors <4 cm and benign-appearing lesions if resection is indicated due to tumor growth.[416] If malignancy is suspected and the disease is localized, locally resectable, or regionally advanced, an open adrenalectomy is recommended. Metastatic disease should be treated similar to ACC.

Evaluation of Adrenocortical Carcinoma

ACC should be strongly suspected in tumors >4 cm with irregular margins or that are internally heterogeneous and if they secrete multiple hormones.[21] On CT scans with IV contrast, adjacent lymph nodes or liver metastases may be present. On unenhanced CTs, the HU number is typically higher in carcinomas than in adenomas, and a threshold value of 10 HU has been proposed as a means of distinguishing benign from malignant adrenal tumors.[21] If the HU attenuation value is <10 on unenhanced CT, then the tumor is probably benign. If the HU attenuation value is >10 on unenhanced CT, then enhanced CT and washout at 15 minutes is recommended. If the absolute washout value is >60% at 15

Version 3.2025 © 2025 National Comprehensive Cancer Network© (NCCN©), All rights reserved. NCCN Guidelines® and this illustration may not be reproduced in any form without the express written permission of NCCN.

minutes, the tumor is likely benign; if <60%, the tumor is possibly malignant.[418-420] MRIs more clearly document local invasion and involvement of the inferior vena cava than CT scans.[21] Whether CT or MRI scans are performed, they should be performed using an adrenal protocol.

FDG-PET/CT, chest CT scans with or without contrast, abdomen/pelvis CT or MRI scans with contrast, and a biochemical evaluation for hypercortisolemia (± Cushing syndrome), primary aldosteronism, and androgen excess are also recommended for resectable, unresectable, or suspected metastatic disease.

One study found that 5.8% of adults with ACC tested positive for Li Fraumeni syndrome (*TP53* gene) and genetic testing should be routinely offered to all patients with ACC.[421] Another analysis found that approximately 3% of patients with ACC have Lynch syndrome, leading the authors to recommend that patients with ACC also undergo genetic testing for Lynch syndrome.[27] Patients with ACC may also consider MSI, MMR, and TMB (by an FDA-approved test) testing. Genetic counseling and testing for inherited genetic syndromes is also recommended.

Treatment and Surveillance of Localized Adrenocortical Carcinoma

Surgical resection of the tumor with removal of radiographically or clinically evident lymph nodes is recommended in patients with localized ACC, and may require removal of adjacent structures such as the liver, kidney, pancreas, spleen, and/or diaphragm for complete resection. Open adrenalectomy is recommended in tumors with a high risk of being malignant because of increased risk for local recurrence and peritoneal spread when performed laparoscopically.[416,422] It is thus important to achieve negative margins and avoid breaching the tumor capsule.

Because of the rarity of ACCs, no randomized, prospective trials of adjuvant therapy have been published. Most retrospective reports have examined the use of adjuvant mitotane, an oral adrenocorticolytic agent.[423] A systematic review and meta-analysis of the benefits of mitotane after resection of ACC in patients without distant metastasis included five retrospective studies reporting on 1249 patients.[424] The meta-analysis found benefit of adjuvant mitotane, with significantly longer relapse-free survival (RFS) and OS, suggesting that adjuvant mitotane may be an effective postoperative strategy. The phase III multicenter ADIUVO trial randomized 91 patients with ACCs considered to be at low to intermediate risk for recurrence in a 1:1 ratio to assess the efficacy of adjuvant mitotane compared to surveillance.[425] RFS is the primary endpoint. In the mitotane group, the 5-year RFS was 79%, compared to 75% in the surveillance group (HR, 0.74; 95% CI, 0.30–1.85). There was no significant difference in terms of the 5-year OS (mitotane, 95%; surveillance, 86%). The study ended early due to slow recruitment.

There are three treatment options if the patient is at high risk for local recurrence based on positive margins, ruptured capsule, large size, and high grade. A clinical trial is recommended if available. Adjuvant external beam RT to the tumor bed can also be considered in these cases, particularly if concern exists regarding tumor spillage or close margins after surgery. Additionally, based on the available data, adjuvant mitotane therapy can be considered. Adjuvant mitotane therapy can also be considered after resection of ACC, although its use in this setting is controversial (category 3) and the optimal duration is unknown. Mitotane blood levels should be monitored. Some institutions recommend target levels of 14 to 20 mcg/mL if tolerated. Steady-state levels may be reached several months after initiation of mitotane. Because of the adrenolytic effects of mitotane, replacement doses of corticosteroids (hydrocortisone with or without fludrocortisone) should be prescribed to treat adrenal insufficiency if it is used; corticosteroids usually are required for the rest of the patient's life. Because of the potential risks and uncertain benefits of adjuvant mitotane, several NCCN Member Institutions do not advocate its use in the adjuvant treatment of patients with resected ACCs. The role of

Version 3.2025 © 2025 National Comprehensive Cancer Network© (NCCN©), All rights reserved. NCCN Guidelines® and this illustration may not be reproduced in any form without the express written permission of NCCN.

chemotherapy in the adjuvant setting is unproven, although enrollment to the ongoing ADIUVO-2 study of adjuvant mitotane with or without chemotherapy is encouraged (NCT03583710) for patients at high risk of recurrence post-resection.

A follow-up should be performed every 12 weeks to 12 months for up to 5 years, and then as clinically indicated. Recurrences after 5 years are thought to be very rare. A chest CT scan, with or without contrast, and an abdomen CT or MRI scan with contrast and biomarkers (if the tumor is initially functional) should be considered.

Management of Locoregional Unresectable or Metastatic Adrenocortical Carcinoma

Observation with chest CT scans with or without contrast, and abdomen/pelvis CT or MRI scans with contrast, every 12 weeks, and relevant biomarkers (if the tumor is initially functional) can be considered for clinically indolent disease, with systemic treatment initiated at tumor progression. Resection may be considered if >90% of the primary tumor and metastases can be removed, particularly if the tumor is initially functional. In the case of bulky disease or if <90% of the tumor is removable, surgery can be reconsidered following a response to systemic therapy.

For locoregional unresectable or metastatic disease, local therapy may be considered (ie, SBRT,[322] thermal ablative therapies, liver-directed therapies). Commonly, however, systemic therapy should be considered, preferably in a clinical trial. Preferred options include cisplatin or carboplatin in combination with etoposide, with or without doxorubicin, and with or without mitotane; other recommended regimens include cabozantinib, mitotane monotherapy, and pembrolizumab with or without mitotane; useful in certain circumstances options include nivolumab plus ipilimumab and osilodrostat (for symptom control). Nivolumab and hyaluronidase-nvhy is not approved for concurrent use with IV ipilimumab; however, for nivolumab monotherapy, nivolumab and hyaluronidase-nvhy subcutaneous injection may be substituted for IV nivolumab. Nivolumab and hyaluronidase-nvhy has different dosing and administration instructions compared to IV nivolumab.

Mitotane monotherapy has been studied in the setting of locally advanced or metastatic disease.[426-428] PR rates are thought to occur in 10% to 30% of patients.[429] The optimal doses and duration of mitotane treatment for metastatic disease have not yet been standardized, but some institutions recommend target levels of 14 to 20 mcg/mL, if tolerated. Higher doses may be difficult for patients to tolerate, whereas lower doses may be less effective.[429] Steady-state levels may be reached several months after initiation of mitotane. As noted above, because of the adrenolytic effects of mitotane, replacement doses of corticosteroids (hydrocortisone with or without fludrocortisone) should be prescribed to treat adrenal insufficiency. This replacement therapy is usually required for the remainder of the patient's lifetime.

Several studies have evaluated the combination of mitotane with other cytotoxic agents, including cisplatin and etoposide. One of the larger studies analyzed the combination of mitotane with cisplatin, etoposide, and doxorubicin in 72 patients with unresectable adrenal carcinoma, yielding an ORR of 49% (according to WHO criteria) and a complete hormonal response in 16 of 42 patients with functioning tumors.[430] A retrospective study with 43 patients in Asia with metastatic ACC treated with the same regimen reported a median OS of 15.4 months (95% CI, 11.6 months – not reached) and a median PFS of 6.2 months (95% CI, 4.3–10.0 months).[431] Analysis of results from the international randomized controlled phase III FIRM-ACT trial comparing treatment of metastatic ACC with etoposide, doxorubicin, cisplatin, and mitotane versus treatment with streptozotocin and mitotane with a crossover design found no

Version 3.2025 © 2025 National Comprehensive Cancer Network© (NCCN©), All rights reserved. NCCN Guidelines® and this illustration may not be reproduced in any form without the express written permission of NCCN.

difference between the regimens in the primary endpoint of OS (14.8 vs. 12.0 months; HR, 0.79; 95% CI, 0.61–1.02; $P = .07$).[432] However, response rates (23.2% vs. 9.2%, $P < .001$) and PFS (median PFS, 5.0 months vs. 2.1 months; HR, 0.55; 95% CI, 0.43–0.69; $P < .001$) were improved with the 4-drug regimen and an OS benefit (17.1 vs. 4.7 months) was seen in those who did not cross over to the other combination. Rates of serious adverse events were similar in the two arms. However, the toxicity of concurrent chemotherapy plus mitotane should be considered when making treatment decisions, and mitotane monotherapy may still be appropriate in selected patients.

In a single-arm phase II trial with 18 patients with advanced ACC treated with cabozantinib, the median PFS was 6 months (95% CI, 4.3 months – not reached).[433] At 4 months, 72.2% of patients (95% CI, 46.5%–90.3%) achieved PFS. A small phase II study investigating the use of pembrolizumab in patients with advanced ACCs found an ORR of 23% and a disease control rate of 52%.[434] The median OS was 24.9 months. Another small study with 16 patients with advanced ACC demonstrated an ORR of 14% (95% CI, 2%–43%).[435] One phase II study reported a 15% ORR and a 54% clinical benefit rate.[436]

Nivolumab plus ipilimumab was investigated in the phase II NCI/SWOG S1609 trial in patients who were previously treated.[437] In the adrenocortical cohort, which consisted of 21 patients, the ORR was 14%. The median PS and median PFS were 15.8 months (95% CI, 6.6–28.9 months) and 1.8 months (95% CI, 1.7–7.1 months), respectively. Studies have demonstrated the efficacy of osilodrostat for symptom control in the setting of cortisol excess in states like adrenal adenomas, adrenal carcinomas, and ectopic ACTH syndrome.[438,439]

A follow-up with chest CT scans, with or without contrast, and abdomen/pelvis CT or MRI scans, with contrast, or FDG-PET/CT scans should be performed every 12 weeks to 12 months, up to 5 years, and then as clinically indicated.

Pheochromocytomas/Paragangliomas

The peak incidence of occurrence for PCCs is between the third and fifth decades of life, but they generally occur at a younger age and are more likely to be bilateral in patients with familial disease. Paragangliomas are more likely to be malignant than PCCs in the adrenal medulla (about 40% vs. 10%). Pheochromocytomas and PGLs associated with a familial syndrome tend to be more aggressive and more likely to metastasize than sporadic tumors.[440] In fact, a study showed that 87.5% of patients presenting with these tumors prior to age 20 harbored a germline mutation in one of several genes tested if they also had metastatic disease.[441] For those without metastases, the rate of identification of these mutations was still high, at 64.7%. The OS of patients with PCCs and PGLs can be heterogeneous, but a systematic review and meta-analysis of seven studies of 738 patients reported survival to be 63% at 5 years.[442] Predicting who will go on to develop metastasis is difficult, but some studies have reported that almost half of patients have not progressed a year after diagnosis.[443] Delays at a median of 5.5 years with a range from 0.3 to 53.4 years between initial diagnosis and metastasis have been reported in a retrospective study spanning 55 years of patients with PCCs or PGLs, and many such patients survive long term after treatment of metastatic disease.[444] Thus, patients presenting during childhood, adolescence, or young adulthood require careful, lifelong surveillance (see *Surveillance of Pheochromocytomas/Paragangliomas*, below).

Evaluation for Pheochromocytomas/Paragangliomas

A patient with possible PCCs should be evaluated with fractionated metanephrines and normetanephrines in 24-hour urine or free metanephrines in plasma. Elevated levels of metanephrines or normetanephrines are suggestive of PCC or PGL. In general, adrenal

Version 3.2025 © 2025 National Comprehensive Cancer Network© (NCCN©), All rights reserved. NCCN Guidelines® and this illustration may not be reproduced in any form without the express written permission of NCCN.

PLEASE NOTE that use of this NCCN Content is governed by the End-User License Agreement, and you MAY NOT distribute this Content or use it with any artificial intelligence model or tool.
Printed by Galya Basol Kochav on 1/7/2026 1:55:52 PM. Copyright © 2026 National Comprehensive Cancer Network, Inc. All Rights Reserved.

PCCs more commonly secrete metanephrines and PGLs secrete normetanephrines, with a few exceptions.[15,16] Concurrent medications should be reviewed before testing for those that interfere with plasma or blood metanephrine/normetanephrine evaluation, including acetaminophen, certain beta- and alpha-adrenoreceptor blocking drugs, serotonin-reuptake inhibitors, and monoamine oxidase inhibitors.[445] Elevations in metanephrine or normetanephrine levels that are three times above the upper limit of normal are diagnostic. Urine or plasma catecholamines are no longer routinely recommended for the evaluation of PCC as 15% to 20% of patients with PCC have normal levels of urine catecholamines due to intermittent secretion in some tumors and insignificant secretion by others.[446] Measurement of serum and/or 24-hour urine-fractionated catecholamines (for dopamine) or methoxytyramine (if available) may be appropriate for cervical PGLs. Methoxytyramine is helpful as the metabolite of dopamine in cervical tumors but it is not commercially available in many places. Both catecholamines and metanephrines/normetanephrines can represent false-positive results. Some investigators support the use of fractionated urinary and/or plasma catecholamines as a way to differentiate false-positive results and to differentiate epinephrine-secreting PCC.

Adrenal protocol CT or MRI is recommended, if not already done. Other imaging studies, including multiphasic abdomen/pelvis CT or MRI scans, SSTR-based imaging (PET/CT or PET/MRI), FDG-PET/CT scans (skull vertex to mid-thigh), chest CT scans with or without contrast, and metaiodobenzylguanidine (MIBG) scans with SPECT/CT should be performed as appropriate if metastatic or multifocal disease is suspected. Data on the role of functional imaging in PCC/PGL are evolving and the preferred method remains unclear. CT scans are most helpful for adrenal masses and PGLs. However, there are some instances where extra-adrenal PGLs are seen better with MRI scans. MIBG scans are less sensitive than FDG-PET and 68Ga-DOTATATE for metastatic and multifocal PCCs/PGLs (in patients with VHL and SDH syndromes but not in those with MEN1 or neurofibromatosis type 1 syndromes or some patients with sporadic PCCs).[447] SPECT/CT imaging of involved sites is recommended. Obtain an MIBG scan if considering treatment with I131-MIBG. Tumor/somatic molecular profiling should be considered as appropriate for patients with locoregional unresectable/metastatic disease who are candidates for anticancer therapy to identify actionable alterations. Testing on tumor tissue is preferred; however, liquid biopsy can be considered if tumor tissue testing is not feasible.

Genetic Counseling/Testing in Pheochromocytomas/Paragangliomas

While many PCCs and PGLs are thought to be sporadic, increasing evidence shows that a number of PCCs and PGLs are in fact associated with inherited genetic syndromes.[17,448] Pheochromocytomas occur in patients with MEN2A, MEN2B, and other familial diseases such as neurofibromatosis and VHL syndrome (see *Principles of Hereditary Cancer Risk Assessment and Genetic Counseling* in the algorithm). Paragangliomas are also associated with polycythemia-paraganglioma-somatostatinoma syndrome due to somatic mutations in the *HIF2A* gene.[449,450] In addition to germline mutations associated with these syndromes (ie, *RET, NF1*, *VHL*), germline mutations in *SDHB*, *SDHA*, *SDHAF2*, *SDHD*, *SDHC*, *TMEM127*, *MAX*, *FH,* and *MDH2* have also been associated with an increased incidence of PCCs and PGLs.[19,448-454] *SDHB* gene mutations are associated with a 40% to 60% risk of developing metastatic disease.[19] Patients <45 years of age or those with multifocal, bilateral, or recurrent lesions are more likely to have a heritable mutation, although many individuals with a hereditary syndrome present with solitary disease and no family history.[454] Because a significant proportion of patients with a PCC or PGL have a heritable mutation,[448] genetic counseling is recommended in patients with such a diagnosis and in those with a family history of these tumors, with genetic testing when appropriate.

Version 3.2025 © 2025 National Comprehensive Cancer Network© (NCCN©), All rights reserved. NCCN Guidelines® and this illustration may not be reproduced in any form without the express written permission of NCCN.

PLEASE NOTE that use of this NCCN Content is governed by the End-User License Agreement, and you MAY NOT distribute this Content or use it with any artificial intelligence model or tool.
Printed by Galya Basol Kochav on 1/7/2026 1:55:52 PM. Copyright © 2026 National Comprehensive Cancer Network, Inc. All Rights Reserved.

Individuals with known germline mutations associated with PCCs and PGLs should undergo lifelong biochemical and clinical screening. Surveillance should start at 6 to 10 years for patients with *SDHB* mutations and 10 to 15 years for those with all other forms of hereditary PCC/PGL.[454,455] The type and timing of the surveillance should be based on which gene is affected and take into account known genotype-phenotype relationships. MRI may be the preferable imaging modality for tumor detection in these individuals in order to limit radiation exposure.[15,16]

Treatment of Pheochromocytomas/Paragangliomas

Medical Preparation for Treatment

Surgical resection is the mainstay of treatment for both benign and malignant PCCs and PGLs. Surgery or stress can cause a sudden release of large amounts of catecholamines, causing very significant and sometimes life-threatening hypertension. Alpha blockade is necessary treatment for all hormonally secreting PCCs and PGLs regardless of clinical symptoms. If additional treatments are planned, patients may need medication adjustments. Therefore, patients with PCCs or PGLs should receive alpha-adrenergic blockade with aggressive volume repletion and high-salt diet for 7 to 14 days or until stable as medical preparation for treatment. Alpha 1-selective receptor blockers include terazosin, doxazosin, and prazosin, and non-selective receptor blockers include phenoxybenzamine. Medications that will precipitate a hormone-mediated crisis should be avoided. If the patient has a hypertensive crisis, consider the addition of nitroprusside, phentolamine, or nicardipine for the treatment of hypertension. Cardiac arrhythmias can be managed with esmolol or lidocaine. Hypoglycemia and hypotension can be seen postoperatively. Treatment with IV fluids for volume expansion with the inclusion of dextrose for glucose levels is recommended.

If additional blood pressure control is needed after alpha blockade, the addition of dihydropyridine calcium channel blockers can be used. Calcium channel blockers are not recommended as monotherapy unless the patient cannot tolerate alpha blockade. Metyrosine can be used in addition to alpha blockade to control blood pressure. Beta blockade (B1-selective blockers or non-selective beta-blockers) can also be added to alpha blockade to control tachycardia. Generally, alpha- and beta-blockers should be administered independently, and use of combination beta-/alpha-blockers is not recommended. Non-selective alpha blockade phentolamine (IV) can be used intraoperatively for additional blood pressure control. Doxazosin has a longer half-life and is oftentimes more available than some of the other agents.

Treatment Recommendations

Resection is the recommended treatment for patients with resectable tumors. A minimally invasive approach, when safe and feasible, is the preferred treatment for adrenal medullary tumors, including PCCs.[456-458]

For locally unresectable tumors or distant metastatic disease,[459] observation is recommended, if the disease is asymptomatic or is slow-growing with low volume. There are limited treatment options for advanced tumors. For locally unresectable or distant metastatic secreting tumors, alpha blockade should be continued along with one of the following options: enrollment in a clinical trial; RT with or without cytoreductive (R2) resection, when possible (for locally unresectable tumors); cytoreductive (R2) resection, when possible (for distant metastatic tumors); systemic therapy; or palliative RT (for oligometastatic disease and/or symptomatic metastases [excluding mesenteric masses]).

Systemic therapy options are belzutifan,[460] cabozantinib,[461] high-specific activity (HSA) iobenguane I-131 or other 131iodine-MIBG (131I-MIBG) if tumors are positive on MIBG scan,[462-464] selpercatinib,[465] sunitinib 37.5 mg

Version 3.2025 © 2025 National Comprehensive Cancer Network© (NCCN©), All rights reserved. NCCN Guidelines® and this illustration may not be reproduced in any form without the express written permission of NCCN.

PLEASE NOTE that use of this NCCN Content is governed by the End-User License Agreement, and you MAY NOT distribute this Content or use it with any artificial intelligence model or tool.
Printed by Galya Basol Kochav on 1/7/2026 1:55:52 PM. Copyright © 2026 National Comprehensive Cancer Network, Inc. All Rights Reserved.

once daily,[466] systemic chemotherapy [CVD or temozolomide],[296,467-470] PRRT with lutetium Lu 177 dotatate (if tumors are SSTR-positive),[471,472] or SSAs (octreotide LAR or lanreotide) (if tumors are SSTR-positive). Selpercatinib can be considered for patients with *RET* gene fusion-positive tumors that have progressed on or following prior systemic treatment or who have no satisfactory alternative treatment options.

In the LITESPARK-015 study (Cohort A1), patients with locally advanced, unresectable, or metastatic PCC or PGL were treated with belzutifan.[460] The results showed an ORR of 26% (95% CI, 17%–38%), with a median duration of response of 20.4 months (95% CI, 8.3 months–not reached). Thirty-two percent of the 60 patients taking baseline antihypertensive agents experienced a decrease of ≥50% in at least one antihypertensive agent.

Cabozantinib was investigated in the single-arm phase II Natalie trial.[461] Out of 17 patients with progressive and unresectable metastatic PCC or PGL, 25.0% (95% CI, 7.3%–52.4%) achieved the primary endpoint of overall response.

Selpercatinib was evaluated in the multicohort phase I/II LIBRETTO-1 study in patients with *RET* fusions.[465] Out of 6 patients with PCC (5 of whom had MEN2 syndrome), a PR/CR was reported in 4 patients and stable disease was reported in 2 patients.

Radioligand therapy has been studied for a number of years. A review of 48 patients with PCC or PGL treated with 131I-MIBG therapy at four centers showed that, while PRs were rare, stable disease was achieved after 83.1% of treatments.[473] Of 16 patients with refractory PCC and PGL treated with 131I-MIBG, 23.5% (90% CI, 8.5%–46.1%; $P = .009$) achieved a biochemical response, defined as a ≥50% reduction in urine catecholamines. Five point nine percent (90% CI, 0.3%–25.0%) and 29.4% (90% CI, 12.4%–52.2%) of patients achieved a radiographic response rate, as determined by CT/MRI based on RECIST version 1.1 and 123I-MIBG scintigraphy, respectively.[474] A meta-analysis of 17 studies that included a total of 243 patients with malignant PCC or PGL found a stable disease rate of 52% (95% CI, 0.41–0.62) after 131I-MIBG therapy.[475] PRs and CRs were seen in 27% and 3% of patients, respectively.

The results of a phase 2, open-label, multicenter study investigating HSA iobenguane I-131 to treat patients with malignant, recurrent, and/or unresectable PCC or PGL revealed that the primary endpoint (a reduction in antihypertension medication by at least half) was met by 25% of all patients who received at least one therapeutic dose (n = 68) and 32% of patients who received two therapeutic doses (n = 50).[464] The objective tumor response was evaluated as a secondary endpoint. Overall, 23% of patients had PR, which went up to 30% in patients who received two therapeutic doses, and 68% of patients had stable disease. The median OS was almost 37 months in patients who received at least one therapeutic dose. The most commonly reported side effects in patients who received any dose of HSA iobenguane I-131 were nausea, myelosuppression, and fatigue. In 2018, HSA iobenguane I-131 became an FDA-approved option for patients who have an MIBG-positive scan; have unresectable, locally advanced, or metastatic PCC or PGL; and require systemic anticancer therapy. However, the drug has not been available in the United States since 2024.

In the phase II FIRSTMAPPP study, patients with metastatic PCCs and PGLs were randomized 1:1 to receive sunitinib at a dose of 37.5 mg/day or placebo.[466] Sunitinib demonstrated antitumor activity in these patients. The 12-month PFS rate (primary endpoint) was 36% (90% CI, 23%–50%) in the sunitinib arm and 19% (90% CI, 11%–31%) in the placebo arm. Patients treated with sunitinib had a median PFS of 8.9 months (placebo, 3.6 months), median OS of 26.1 months (placebo, 49.5), and an ORR of

Version 3.2025 © 2025 National Comprehensive Cancer Network© (NCCN©), All rights reserved. NCCN Guidelines® and this illustration may not be reproduced in any form without the express written permission of NCCN.

36.1% (placebo, 8.3%). Sunitinib was also evaluated in the non-randomized SUTNET clinical trial in 50 patients with metastatic or unresectable PCCs/PGLs.[476] The 12-month PFS rate (primary endpoint) was 53.4% (5% CI, 41.1–69.3) and the median PFS was 14.1 months (95% CI, 8.9–25.7). The ORR was 15.6% and the median OS was 49 months (95% CI, 21.2–NA). Of note, sunitinib was used at a dose of 50 mg/day for 4 weeks, followed by a 2-week break, in this study. Other VEGF TKIs may also have activity in PCCs/PGLs and are currently under study.[477]

A retrospective review of 52 evaluable patients treated with various systemic chemotherapy regimens for metastatic PCCs or PGLs showed that patients with a response to chemotherapy (reduction in symptoms, antihypertensive medications, or tumor size) had a median survival of 6.4 years and non-responders had a median survival of 3.7 years.[468] Approximately 33% of patients exhibited a tumor response. In a long-term follow-up of 18 patients with metastatic PCCs or PGLs treated with CVD, 11% of patients had a CR, while 44% had a PR.[478] Temozolomide has also demonstrated efficacy in patients with PCCs or PGLs, especially in those with the *SDHB* mutation (although this finding needs to be validated). [469,479] A randomized study of temozolomide with or without a PARP inhibitor is ongoing (NCT04394858).

A study of 20 patients with high SSTR expressing PCC or PGL treated with lutetium Lu 177 dotatate assessed the effectiveness of PRRT in controlling hypertension.[480] Most patients receiving PRRT saw no change in medication to treat hypertension. The median PFS was 39 months and median OS was not reached with a median follow-up time of 28 months. A systematic review and meta-analysis of 201 patients with inoperable or metastatic PCCs or PGLs determined that treatment with PRRT led to an ORR of 25% (95% CI, 19%–32%) and a disease control rate of 84% (95% CI, 77%–89%).[481] Clinical responses were reported in 61% of patients. In a retrospective analysis of 15 patients with unresectable or metastatic PCC and PGL treated with PRRT with lutetium Lu 177 dotatate, 20% of patients had progressive disease, while 53% had stable disease.[471]

An ENETS Centre study with 22 patients with progressive or metastatic PCCs or PGLs treated patients with PRRT with either 90Y-dotatate or lutetium Lu 177 dotatate, and 131I-MIBG.[482] Patients treated with PRRT had increased PFS and treatment response compared to 131I-MIBG treatment, but no significant differences were seen in OS. Other studies have been published[481,483-487] that have also shown activity in patients with high SSTR expressing PCC or PGL treated with lutetium Lu 177 dotatate. A retrospective study of 22 patients (2 localized and 20 metastatic) with PCC and PGL determined that treatment with PRRT with lutetium Lu 177 dotatate resulted in improved outcomes.[472] The median OS and median PFS were 49.6 months and 21.6 months, respectively. Forty-seven percent of patients achieved a scintigraphic response of >50%. Forty percent of patients achieved a biochemical response (>50% reduction) for chromogranin A and 25% of patients achieved a biochemical response for catecholamines. In a subgroup analysis, Ki-67 <15% was associated with improved OS (P = .013) and PFS (P = .005). Prospective studies assessing the use of Lu 177 dotatate PRRT and other radioligand therapies in PCCs/PGLs are ongoing (NCT03206060, NCT06045260, NCT05636618). Data from an interim analysis published in an abstract showed that in a phase II trial, 86% of patients with PCCs and PGLs treated with lutetium Lu 17 dotatate achieved the primary endpoint of PFS at 6 months, with a mean PFS of 19.1 months.[488] Patients with sporadic PCCs and PGLs had a longer PFS compared to those with *SDHx* mutations (22.7 months vs. 15.4 months).

Extrapolating from established treatment for other types of functional NETs, the use of SSAs (octreotide LAR 20–30 mg intramuscularly or lanreotide 120 mg subcutaneously every 4 weeks) for hormone excess

Version 3.2025 © 2025 National Comprehensive Cancer Network© (NCCN©), All rights reserved. NCCN Guidelines® and this illustration may not be reproduced in any form without the express written permission of NCCN.

and symptom control can be considered. For breakthrough symptoms, octreotide 100–250 mcg subcutaneously three times daily can also be considered. Data about antiproliferative effects of SSAs in SSTR+ tumors are limited and clinical trials are ongoing (NCT03946527). Data from a phase II trial published in an abstract showed that out of 18 patients with PCCs and PGLs treated with lanreotide (14 of whom had an *SDHx* mutation), 15 had stable disease at one year and 3 had progressive disease, based on RECIST.[489] If injection site-related complications occur, consider switching to another SSA.

Surveillance of Pheochromocytomas/Paragangliomas

Surveillance intervals for patients with PCCs or PGLs are similar to those for other NETs. Following complete resection, H&P should be performed and blood pressure and tumor markers should be measured after 12 weeks to 12 months, then every 6 to 12 months for the first 3 years, and then annually for up to 10 years. After 10 years, surveillance should be considered as clinically indicated. In addition, chest CT scans with or without contrast, and abdomen/pelvis CT or MRI scans with contrast can be considered. Timing for these surveillance events and procedures can be earlier if symptoms dictate or less frequently if the disease is stable and there are no new symptoms. Concurrent medications should be reviewed to identify those that may interfere with plasma metanephrines evaluation. Evaluations that are 3 times above the upper limit of normal are diagnostic. Surveillance for cervical PGL should be done as previously described. For locally unresectable disease or distant metastases, H&P should be performed and blood pressure and plasma-free or 24-hour urine-fractionated metanephrines and normetanephrines should be measured. Chest/abdomen/pelvis CT scans with contrast; chest CT scans (with or without contrast) and abdomen/pelvis MRI scans without contrast (if the patient is at risk for a hypertensive episode); MIBG with SPECT/CT (if there is a previous MIBG-positive scan or concern for disease progression) prior to considering radionuclide therapy; FDG-PET/CT scans (for bone-dominant disease); or SSTR-based imaging (if there is a previous SSTR-positive scan or concern for disease progression prior to considering radionuclide therapy) can be considered. In addition, individuals with hereditary PCC/PGL may require more frequent and longer follow-up (see *Principles of Hereditary Cancer Risk Assessment and Genetic Counseling* in the algorithm). For cervical PGLs, surveillance recommendations are the same as described in the evaluation section.

Multiple Endocrine Neoplasia

The MEN syndromes are characterized by tumors that arise from endocrine organs and cells throughout the body. The two most common syndromes are MEN1 and MEN2. MEN1 is an autosomal-dominant inherited syndrome characterized by hyperparathyroidism (most commonly 4-gland hyperplasia), pituitary adenomas, and PanNETs; MEN1 may also be associated with NETs of the lung and thymus, adrenal tumors, multiple lipomas, and cutaneous angiomas. MEN2 is also an autosomal-dominant inherited syndrome and is associated with MTC (98%); PCC (50%), often bilateral; and hyperparathyroidism (25%). In addition, familial MTC occurs in patients without MEN2 and is inherited as an autosomal dominant disease.

MEN1 is associated with the germline mutation or inactivation of the tumor suppressor gene *MEN1* (chromosomal locus 11q13 encoding the menin protein),[490] whereas MEN2 and familial MTC are associated with germline mutations of the proto-oncogene, *RET* (chromosomal locus 10q11.2), that lead to activation of the tyrosine kinase receptor, RET.[491] Somatic mutation of the *MEN1* gene is also the most common known genetic alteration in sporadic parathyroid adenomas, gastrinomas, insulinomas, and bronchial NETs.[10] Somatic *RET* mutations are found in sporadic MTC.[492]

Version 3.2025 © 2025 National Comprehensive Cancer Network© (NCCN©), All rights reserved. NCCN Guidelines® and this illustration may not be reproduced in any form without the express written permission of NCCN.

PLEASE NOTE that use of this NCCN Content is governed by the End-User License Agreement, and you MAY NOT distribute this Content or use it with any artificial intelligence model or tool.
Printed by Galya Basol Kochav on 1/7/2026 1:55:52 PM. Copyright © 2026 National Comprehensive Cancer Network, Inc. All Rights Reserved.

MEN1

MEN1 (or Wermer syndrome) is typically characterized by tumors of the parathyroid and pituitary glands; NETs of the pancreas, thymus, bronchi, or GI tract; adrenal tumors; and/or multiple lipomas and skin angiomas. Over 98% of patients with MEN1 either have or will develop primary hyperparathyroidism, and about 50% will develop symptoms from functioning benign or malignant neoplasms of the pancreas.[10] About 30% to 40% of patients have functioning tumors of the pituitary, and 20% to 55% of patients also have or will develop nonfunctioning PanNETs.[493] Approximately 2% of patients with MEN1 develop thymic or bronchopulmonary NETs.[494] Thymic and duodenopancreatic neuroendocrine neoplasias are the leading cause of death in patients with MEN1.[495] Approximately 30% of patients with MEN1 die from NETs.[494]

Examples of functional syndromes include hypercalcemia related to parathyroid hyperplasia; galactorrhea or amenorrhea associated with a prolactinoma; Zollinger-Ellison syndrome associated with gastrinoma and hypersecretion of gastrin; and hypercortisolemia (± Cushing syndrome) or acromegaly related to a pituitary tumor or solitary or bilateral adrenal tumors. Ectopic hypercortisolemia (± Cushing syndrome) may be caused by a NET of the pancreas, thymus, or bronchus, or by an MTC. In addition, although rare, patients may develop symptoms as a result of an excess of several hormones from more than one gland, such as hyperparathyroidism and a simultaneous gastrinoma, insulinoma, or a functioning pituitary tumor. However, in most patients, a single hormonal syndrome dominates the clinical picture.

About 80% of patients with MEN1 and hypoglycemia related to insulinoma have multiple islet cell neoplasms. Patients with MEN1 and Zollinger-Ellison syndrome also frequently have more than one tumor. Of these tumors, 70% are gastrin-secreting NETs in the duodenum and/or periduodenal lymph nodes. Nonfunctioning PanNETs are usually larger when clinically detected, and are more likely to be associated with metastases at the time of presentation. The development of metastatic NETs of the pancreas or thymus are the most common causes of death associated with MEN1. The clinical characteristics of pancreatic endocrine tumors are summarized under *Neuroendocrine Tumors of the Pancreas (Well-Differentiated Grade 1/2)*, above.

Evaluation of MEN1 Syndromes

A clinical diagnosis for MEN1 can be made when an individual patient has two or more MEN1-associated tumors (ie, multigland parathyroid hyperplasia, enteropancreatic NETs, pituitary tumors).[494] For patients known or suspected to have MEN1, clinical evaluation includes biochemical evaluation of hormone levels and imaging to localize the site of tumors. In particular, patients should be evaluated for parathyroid tumors, PanNETs, pituitary tumors, and lung/thymic NETs (see below). In addition, genetic counseling and testing for inherited genetic syndromes should be provided (see *Genetic Counseling/Testing in MEN1*, below).

Evaluation for Parathyroid Tumors in MEN1

Primary hyperparathyroidism associated with parathyroid adenomas is the most common manifestation of MEN1. Measurement of serum calcium levels is recommended if hyperparathyroidism is suspected. If calcium levels are elevated, parathyroid hormone (PTH), 25-OH vitamin D, inorganic phosphate, 24-hour urine calcium, and creatine levels should be checked.

Imaging of parathyroid glands is less helpful in MEN1 because of the multiple gland hyperplasia.[494] Imaging of the parathyroid glands using neck ultrasound, four-dimensional (4D-CT), or sestamibi scanning with SPECT is recommended if calcium levels are elevated and may aid in identifying ectopically situated parathyroid glands. Preference of scan will depend on institutional practice/protocol.

Version 3.2025 © 2025 National Comprehensive Cancer Network© (NCCN©), All rights reserved. NCCN Guidelines® and this illustration may not be reproduced in any form without the express written permission of NCCN.

PLEASE NOTE that use of this NCCN Content is governed by the End-User License Agreement, and you MAY NOT distribute this Content or use it with any artificial intelligence model or tool.
Printed by Galya Basol Kochav on 1/7/2026 1:55:52 PM. Copyright © 2026 National Comprehensive Cancer Network, Inc. All Rights Reserved.

The technetium-99m (Tc-99m) sestamibi and ultrasound scanning are about 80% and 70% sensitive, respectively, for identifying solitary parathyroid adenomas found in most patients with sporadic hyperparathyroidism. However, these scans are only about 35% accurate in patients with familial hyperparathyroidism and 4-gland hyperplasia. Neither scan can distinguish between adenomatous and hyperplastic parathyroid glands. Because most patients with familial hyperparathyroidism have multiple abnormal parathyroid glands, preoperative localization studies are less accurate and abnormal parathyroid glands are best identified during surgery.[496,497] Tc-99m sestamibi with SPECT can improve sensitivity and specificity compared to planar scan.[498]

4D-CT is a method of multiphase CT imaging that uses a fourth dimension of changes in contrast attenuation over time and is increasingly used for preoperative imaging.[499] It has 60% to 87% sensitivity and allows for more robust diagnostic accuracy than traditional sonography or nuclear scintigraphy techniques. Three- or four-phase CT scanning protocols consist of precontrast, arterial, early-delayed, and late-delayed phases.

Evaluation for Pancreatic Neuroendocrine Tumors in MEN1

Approximately 75% of patients with MEN1 and PanNETs have associated symptoms of hormone hypersecretion. The various characteristics of endocrine tumors of the pancreas (eg, gastrinoma, insulinoma, glucagonoma, VIPoma, somatostatinoma) are summarized under *Neuroendocrine Tumors of the Pancreas (Well-Differentiated Grade 1/2)*, above. The workup for PanNETs in the context of MEN1 is similar to that for sporadic PanNETs. Biochemical evaluation as clinically indicated and multiphasic abdomen, with or without pelvis, CT or MRI are recommended. Imaging with EUS and SSTR-based imaging can be used as appropriate if there are equivocal CT findings. In particular, EUS is recommended if resection is being considered to preoperatively assess and localize tumors. For details on the evaluation for pancreatic tumors, see *Neuroendocrine Tumors of the Pancreas (Well-Differentiated Grade 1/2)*, above.

Evaluation for Pituitary Tumors in MEN1

Pituitary or sella MRI with contrast is recommended when evaluating for pituitary tumors. Various laboratory tests are also used to evaluate for suspected pituitary tumors. The Panel recommends testing serum insulin-like growth factor 1 (IGF-1) (category 2B), serum prolactin, luteinizing hormone (LH)/follicle-stimulating hormone, gonadotrophin with end-organ hormone, alpha subunits, thyroid-stimulating hormone and free T4, plasma ACTH/random cortisol, total and free (or bioavailable) testosterone in those assigned male at birth, estradiol in premenopausal patients assigned female at birth, overnight dexamethasone suppression test, and 24-hour urine for free cortisol (when there is clinical evidence of Cushing syndrome). Elevated prolactin levels are indicative of prolactinoma, and increased IGF-1 occurs in acromegaly.

Evaluation for Lung/Thymic Neuroendocrine Tumors in MEN1

Chest CT with contrast and multiphasic abdomen/pelvis CT or MRI are recommended to evaluate for lung or thymic NETs in patients with MEN1. Other biochemical evaluation should be done as clinically indicated.

Genetic Counseling/Testing in MEN1

Genetic counseling and testing for inherited genetic syndromes should be offered to individuals with a clinical diagnosis of MEN1 (see *Evaluation of MEN1 Syndromes*, above). Genetic risk evaluation and genetic testing for hereditary endocrine neoplasia syndromes is also recommended in a patient with clinical suspicion for MEN1 with ≥2 of the following, or 1 of the following and a family history of ≥1 of the following: primary hyperparathyroidism, duodenal NET/PanNET, pituitary adenoma, or foregut carcinoid (lung, thymic, or gastric). It should be noted that a

Version 3.2025 © 2025 National Comprehensive Cancer Network© (NCCN©), All rights reserved. NCCN Guidelines® and this illustration may not be reproduced in any form without the express written permission of NCCN.

germline *MEN1* mutation is uncommon in individuals with a single MEN1-associated tumor and no family history. Only 10% of patients with MEN1 have a *de novo* germline mutation in *MEN1*, and thus no family history of MEN1-associated tumors.

Treatment of MEN1 Syndromes

Primary therapy of locoregional disease in patients with MEN1 focuses on treatment of the specific hormonal syndrome and/or treatment of the underlying hyperplasia or tumor. When a patient presents with hyperparathyroidism and PanNETs, the hyperparathyroidism is usually treated first. A consultation with an endocrinologist for all patients with MEN1 should be considered.

Treatment of Parathyroid Tumors in MEN1

Treatment options for parathyroid hyperplasia in patients with MEN1 include subtotal parathyroidectomy with or without cryopreservation of parathyroid tissue with or without thymectomy (the bilateral upper thymus is a common site of ectopic parathyroid glands and thymic NETs). Total parathyroidectomy with autotransplantation of parathyroid tissue with or without cryopreservation of parathyroid glands, and with or without thymectomy, is another recommended option.[500-502] A randomized, prospective trial compared these surgical approaches in 32 patients with MEN1 and hyperparathyroidism.[503] No significant differences were observed in outcomes including recurrent hyperparathyroidism. Adverse outcomes include persistent hyperparathyroidism (2%–5%) and hypocalcemia (1%) because of inadequate or excessive resection, respectively, even by expert surgeons. Additionally, postoperative bleeding or hoarseness due to injury to the recurrent laryngeal nerve may occur in about 1% of patients.

Treatment of Pancreatic Neuroendocrine Tumors in MEN1

Treatment of PanNETs associated with MEN1 is similar to sporadic PanNETs and focuses on surgical excision preceded by medical management if necessary [see relevant site-specific recommendations in *Neuroendocrine Tumors of the Pancreas (Well-Differentiated Grade 1/2)*, above]. However, in contrast to patients with sporadic disease where a tumor is usually solitary, PanNETs associated with MEN1 are frequently multiple.[504] Removal of a single functioning tumor, although a reasonable approach for sporadic tumors, may miss additional tumors in the setting of MEN1. MEN1-associated metastatic PanNETs are often slower growing than metastatic sporadic tumors. Observation can be considered for non-functioning, indolent tumors. Surgical resection should be considered in cases of: 1) symptomatic functional tumors refractory to medical management; 2) a tumor >2 cm in size; or 3) a tumor with a relatively rapid rate of growth over 6 to 12 months. The Panel recommends endoscopy with EUS prior to pancreatic surgery to preoperatively assess and localize tumors.

For clinically significant progressive disease or symptomatic patients, treatment options are as for metastatic disease in the sporadic setting [see *Management of Locoregional Advanced and/or Metastatic Neuroendocrine Tumors of the Pancreas (Well-Differentiated Grade 1/2)*, above].

Furthermore, in patients with advanced NETs undergoing abdominal surgery in whom long-term SSA treatment is planned, prophylactic cholecystectomy is recommended due to a higher risk of cholelithiasis in patients receiving SSAs.[157] Metastatic disease in patients with MEN1 is treated as in patients with NETs arising sporadically, according to the appropriate tumor type.

Version 3.2025 © 2025 National Comprehensive Cancer Network© (NCCN©), All rights reserved. NCCN Guidelines® and this illustration may not be reproduced in any form without the express written permission of NCCN.

Treatment of Pituitary Tumors in MEN1

The Panel recommends considering a consultation with endocrinology for the treatment of patients with pituitary tumors associated with MEN1, including those with prolactinoma, hypercortisolemia (± Cushing syndrome), acromegaly, and nonfunctioning tumors.

Treatment of Lung/Thymic Neuroendocrine Tumors in MEN1

The recommendations for the workup and treatment of lung and thymic NETs are the same as for patients with sporadic disease [see *Neuroendocrine Tumors of the Gastrointestinal Tract (Well-Differentiated Grade 1/2), Lung, and Thymus* in the algorithm].

MEN1 Surveillance

All patients with MEN1 should be followed for the development or progression of MEN1-associated tumors, starting at 8 to 15 years of age,[505-509] regardless of previous tumors or treatments. In contrast to sporadic hyperparathyroidism, patients with familial hyperparathyroidism (including MEN1), isolated familial hyperparathyroidism, or hyperparathyroidism associated with jaw tumor syndrome are more likely to develop recurrent disease.[510] Consider referral to an endocrinologist. The patients are also more likely to have or develop new parathyroid carcinomas, PanNETs, pituitary tumors, and/or bronchial/thymic tumors. Carcinoid (neuroendocrine) tumors occur in approximately 3% of patients with MEN1.[494] Bronchial NETs occur more frequently in females, while thymic NETs occur more frequently in males. In addition, individuals who smoke appear to be at increased risk for the development of thymic NETs.[494] In one prospective study, the authors compared the use of lanreotide to active surveillance in patients with MEN1-associated PanNETs <2 cm.[511] The results revealed that lanreotide treatment significantly improves the median PFS (median not reached vs. 40 months).

The Panel recommends annual calcium levels to screen for parathyroid tumors. If calcium levels rise, PTH and 25-OH vitamin D should be measured and re-imaging with neck ultrasound and/or parathyroid sestamibi with SPECT scan (SPECT-CT preferred) or 4D-CT should be performed. Cross-sectional CT or MRI with contrast of the neck can also be considered. For prolonged surveillance, studies without radiation are preferred.

Surveillance for MEN-1–associated PanNETs is accomplished by following serum hormones as symptoms indicate or if they were previously elevated. Cross-sectional imaging with abdomen/pelvis CT or MRI with contrast every 1 to 3 years or serial EUS can also be considered in patients with MEN1. Surveillance for pituitary tumors includes a pituitary or sella MRI with contrast of the pituitary every 3 to 5 years. Prolactin, IGF-1, and other previously abnormal pituitary hormones should be followed every 3 to 5 years or as symptoms indicate. For surveillance of lung or thymic NETs, the Panel suggests that cross-sectional chest CT or MRI with contrast be considered every 1 to 3 years. For prolonged surveillance, studies without radiation are preferred. All close family members of patients with MEN1 should receive genetic counseling, and genetic testing should be considered as described above.

MEN2 and Familial MTC

MEN2 is caused by a germline mutation in the *RET* proto-oncogene and can be further subdivided into MEN2A (Sipple syndrome) and MEN2B based on the spectrum of accompanying endocrine tumors and disorders. MTC is seen in nearly all patients with MEN2A and MEN2B and is often the first manifestation of the syndrome.[232] Patients with MEN2A may also have or develop PCC (usually bilateral, 50%) and hyperparathyroidism (about 25%).[232] Some patients with MEN2A have lichen planus amyloidosis or Hirschsprung disease. Most patients with MEN2B have mucosal neuromas or intestinal ganglioneuromas in addition to MTC; 50%

Version 3.2025 © 2025 National Comprehensive Cancer Network© (NCCN©), All rights reserved. NCCN Guidelines® and this illustration may not be reproduced in any form without the express written permission of NCCN.

of these patients have PCC, but almost none have hyperparathyroidism (<1%).[232] Nearly all patients with MEN2B have Marfanoid habitus and/or poor dentition. Some patients also have ectopic lenses in the eye or very flexible joints.

MTC is a calcitonin-secreting tumor of the parafollicular or C cells of the thyroid, accounting for about 4% to 7% of thyroid cancers but about 15% of all thyroid cancer deaths. About 75% of MTC cases are sporadic, whereas approximately 25% are considered familial or hereditary. Familial MTC associated with MEN2 normally arises in the first to third decades of life, but sporadic MTC is typically diagnosed in the fourth to fifth decades of life. All types of familial MTC are typically multifocal and preceded by C-cell hyperplasia; however, sporadic MTC is usually unifocal. Familial MTC arising in the absence of other endocrine malignancies or disorders is the least aggressive, whereas MTC associated with MEN2B is the most aggressive. MEN2A, MEN2B, and familial MTC are all autosomal-dominant inherited diseases and are associated with germline mutations of the proto-oncogene, *RET*.[11,512]

The initial symptoms associated with MEN2A and MEN2B include a mass in the thyroid gland (with or without adjacent central or lateral cervical lymph node adenopathy) and, less frequently, symptoms of excess hormone production related to MTC (such as diarrhea and facial flushing), PCC (headaches, increased perspiration, and rapid heart rate), or hyperparathyroidism. For a full discussion of the management of MTC (including the use of selective RET inhibitors), consult the NCCN Guidelines for Thyroid Carcinoma (available at www.NCCN.org). The following discussion focuses on the presentation of MEN2 and on the issues unique to MTC in this setting.

Evaluation of MEN2A, MEN2B, and Familial MTC

A clinical diagnosis of MEN2A includes findings of ≥2 MEN2A-associated tumors (MTC, PCC, or parathyroid adenoma/hyperplasia) in a single individual or in close relatives.[513] A clinical diagnosis of MEN2B includes the presence of MTC, PCC, mucosal neuromas of the lips and tongue, medullated corneal nerve fibers, distinctive facies with enlarged lips, Marfanoid body habitus, or the inability to cry tears.[513,514] Genetic counseling and testing for inherited genetic syndromes should be offered to individuals with a clinical diagnosis of MEN2.

Before surgical resection of MTC in these patients, basal calcitonin and carcinoembryonic antigen (CEA) levels should be measured, because these test results help guide the extent of nodal dissection required, particularly in patients with occult disease detected by screening. Patients with low calcitonin and high CEA levels usually have more aggressive tumors. Neck ultrasound of thyroid and cervical lymph nodes should also be performed to document intrathyroidal tumors and to possibly identify cervical lymph node metastases.

For patients with MEN2 who have a parathyroid tumor, serum calcium level should be measured. If it is found to be elevated, PTH, 25-OH vitamin D, inorganic phosphate, 24-hour urine calcium, and creatinine levels should be measured. A neck ultrasound, parathyroid sestamibi scan with SPECT, or 4D-CT is also recommended. Preference of scan will depend on institutional practice/protocol.

Patients with MEN2 should be evaluated for a coexisting PCC (see *Evaluation for Pheochromocytomas/Paragangliomas*, above) before administration of anesthetic or before any invasive procedure. Patients should be evaluated with plasma-free or 24-hour urine-fractionated metanephrines and normetanephrines. Concurrent medications should be reviewed for those that may interfere with plasma metanephrines evaluation. Elevations that are three times above the upper limit of normal are diagnostic. Both catecholamines and metanephrines/normetanephrines can represent false-positive results. Some investigators support the use of fractionated urinary and/or plasma

Version 3.2025 © 2025 National Comprehensive Cancer Network© (NCCN©), All rights reserved. NCCN Guidelines® and this illustration may not be reproduced in any form without the express written permission of NCCN.

PLEASE NOTE that use of this NCCN Content is governed by the End-User License Agreement, and you MAY NOT distribute this Content or use it with any artificial intelligence model or tool.
Printed by Galya Basol Kochav on 1/7/2026 1:55:52 PM. Copyright © 2026 National Comprehensive Cancer Network, Inc. All Rights Reserved.

catecholamines as a way to differentiate false-positive results and to differentiate epinephrine-secreting PCC. Because patients with PCC have persistent vasoconstriction, medical therapy (ie, alpha blockade with volume repletion, high salt diet, additional therapy as needed) is required preoperatively (see *Treatment of Pheochromocytomas/Paragangliomas*, above).

Genetic Counseling/Testing in MEN2

Genetic counseling and testing for inherited genetic syndromes should be offered to individuals with a clinical diagnosis of MEN2 (see *Evaluation of MEN2A, MEN2B, and Familial MTC*, above). Surveillance PCC/PGL should start by age 11 for children in the American Thyroid Association high- and highest-risk categories and by age 16 in children in the moderate-risk category.[514] Surveillance comprises an annual measurement of plasma-free metanephrines or 24-hour urine for fractionated metanephrines and adrenal imaging with CT or MRI in patients with positive biochemical results.[514]

Treatment of MEN2A, MEN2B, and Familial MTC

The treatment of MTC associated with MEN2 is similar to the management of its sporadic counterpart (see the NCCN Guidelines for Thyroid Carcinoma, available at www.NCCN.org). However, patients with familial disease are much more likely to have bilateral thyroid carcinomas. In addition, patients may have synchronous PCC and MTC. In these cases, resection of PCC should take priority over thyroidectomy.

Patients with MEN2 and familial MTC may be prone to hypoparathyroidism because the thyroid gland is often already removed prophylactically or for treatment of C-cell hyperplasia or MTC. The consensus of the Panel is for parathyroidectomy of abnormal glands. Subtotal parathyroidectomy is recommended when all glands appear abnormal. Some surgeons recommend prophylactic parathyroidectomy of all normal parathyroid glands with immediate autotransplantation in patients with MTC, while others believe the risk of hypoparathyroidism with this approach (about 6%) is too high to warrant the procedure. If a normal parathyroid gland is not preserved in situ in patients with MEN2A, it can be autotransplanted to the forearm, since recurrent primary hyperparathyroidism occurs in almost 20% of these patients. If hyperparathyroidism recurs with a documented elevated PTH level in the ipsilateral basilic vein, the tumor can be removed or subtotally resected.

The comprehensive care of patients with PCC and MEN2 is similar to that of PCC in other settings.[515] As patients with MEN2 have an appreciable risk for bilateral tumors, a cortical-sparing adrenalectomy may be considered. For synchronous bilateral PCCs, a bilateral adrenalectomy is recommended. An interesting retrospective, population-based, observational study of 563 patients with MEN2 and PCC from 30 centers across three continents found that adrenal-sparing resections led to similar rates of recurrence with lower rates of adrenal insufficiency or steroid dependency (43% vs. 86%).[516] More studies are needed, however, before this approach can be routinely recommended.

Emerging data suggest that RET kinase inhibitors have activity in patients with locally advanced or metastatic PCC harboring a *RET* gene fusion that has progressed on or following prior systemic treatment.[465] Of six patients treated with selpercatinib in the LIBRETTO-001 trial, a PR or better was reported in 4 patients (67%).

MEN2 Surveillance

Follow-up surveillance is described in the NCCN Guidelines for Thyroid Carcinoma (available at www.NCCN.org) for patients with *RET* mutations treated for MTC or for patients who have undergone parathyroidectomy. Follow-up for treatment of PCCs in these patients is similar to patients who have sporadic disease (see *Surveillance of Pheochromocytomas/Paragangliomas* above).

Version 3.2025 © 2025 National Comprehensive Cancer Network© (NCCN©), All rights reserved. NCCN Guidelines® and this illustration may not be reproduced in any form without the express written permission of NCCN.

PLEASE NOTE that use of this NCCN Content is governed by the End-User License Agreement, and you MAY NOT distribute this Content or use it with any artificial intelligence model or tool.
Printed by Galya Basol Kochav on 1/7/2026 1:55:52 PM. Copyright © 2026 National Comprehensive Cancer Network, Inc. All Rights Reserved.

Future Trial Design

Recent successes have shown that large randomized controlled trials studying treatments for NETs can provide practice-changing results. Current recommendations for clinical trials in NETs stem from the 2021 National Cancer Institute NET clinical trials planning meeting and include the following[517]:

- Clinical trials for bronchial, midgut, and pancreatic NETs should be done separately and if not feasible, patients should be stratified according to site of origin and/or enrolled into cohorts of pancreatic and extrapancreatic NET.
- Well-differentiated NETs and poorly differentiated NECs should be studied in separate trials.
- Clinical trials for well-differentiated NETs should be stratified based on tumor grade or individuals should be enrolled into cohorts based on grade (eg, G1/2 vs. G3).
- Trials should take into account the number of previous lines or types of therapy.
- For randomized trials that use a placebo as control, crossover at the time of disease progression for individuals treated with placebo should be considered.
- Protocols of trials evaluating SSTR-targeted therapies should clearly define SSTR-positive disease and account for variability in SSTR expression.
- PFS is an appropriate primary endpoint for phase III trials in well-differentiated NETs.
- OS may be an appropriate endpoint for phase II and III trials in individuals with poorly differentiated NECs.
- Correlative studies can be included to identify potential biomarkers of efficacy.
- Patient-reported outcome measures should be included in clinical trials to provide additional assessment of the impact of treatment.

Rigorous studies will allow continued progress in the development of improved treatments for patients with NENs.

Version 3.2025 © 2025 National Comprehensive Cancer Network© (NCCN©), All rights reserved. NCCN Guidelines® and this illustration may not be reproduced in any form without the express written permission of NCCN.

PLEASE NOTE that use of this NCCN Content is governed by the End-User License Agreement, and you MAY NOT distribute this Content or use it with any artificial intelligence model or tool.
Printed by Galya Basol Kochav on 1/7/2026 1:55:52 PM. Copyright © 2026 National Comprehensive Cancer Network, Inc. All Rights Reserved.

References

1. Yao JC, Hassan M, Phan A, et al. One hundred years after "carcinoid": epidemiology of and prognostic factors for neuroendocrine tumors in 35,825 cases in the United States. J Clin Oncol 2008;26:3063–3072. Available at: https://www.ncbi.nlm.nih.gov/pubmed/18565894.

2. Dasari A, Shen C, Halperin D, et al. Trends in the incidence, prevalence, and survival outcomes in patients with neuroendocrine tumors in the United States. JAMA Oncol 2017;3:1335–1342. Available at: https://www.ncbi.nlm.nih.gov/pubmed/28448665.

3. Sultana Q, Kar J, Verma A, et al. A comprehensive review on neuroendocrine neoplasms: presentation, pathophysiology and management. J Clin Med 2023;12. Available at: https://www.ncbi.nlm.nih.gov/pubmed/37568540.

4. Rindi G, Mete O, Uccella S, et al. Overview of the 2022 WHO classification of neuroendocrine neoplasms. Endocr Pathol 2022;33:115–154. Available at: https://www.ncbi.nlm.nih.gov/pubmed/35294740.

5. Dasari A, Wallace K, Halperin DM, et al. Epidemiology of neuroendocrine neoplasms in the US. JAMA Netw Open 2025;8:e2515798. Available at: https://www.ncbi.nlm.nih.gov/pubmed/40553474.

6. Xu Z, Wang L, Dai S, et al. Epidemiologic trends of and factors associated with overall survival for patients with gastroenteropancreatic neuroendocrine tumors in the United States. JAMA Netw Open 2021;4:e2124750. Available at: https://www.ncbi.nlm.nih.gov/pubmed/34554237.

7. Hallet J, Law CH, Cukier M, et al. Exploring the rising incidence of neuroendocrine tumors: a population-based analysis of epidemiology, metastatic presentation, and outcomes. Cancer 2015;121:589–597. Available at: https://www.ncbi.nlm.nih.gov/pubmed/25312765.

8. Anlauf M, Garbrecht N, Bauersfeld J, et al. Hereditary neuroendocrine tumors of the gastroenteropancreatic system. Virchows Arch 2007;451 Suppl 1:S29–38. Available at: https://www.ncbi.nlm.nih.gov/pubmed/17684762.

9. Larson AM, Hedgire SS, Deshpande V, et al. Pancreatic neuroendocrine tumors in patients with tuberous sclerosis complex. Clin Genet 2012;82:558–563. Available at: https://www.ncbi.nlm.nih.gov/pubmed/22035404.

10. Marx S, Spiegel AM, Skarulis MC, et al. Multiple endocrine neoplasia type 1: clinical and genetic topics. Ann Intern Med 1998;129:484–494. Available at: https://www.ncbi.nlm.nih.gov/pubmed/9735087.

11. Donis-Keller H, Dou S, Chi D, et al. Mutations in the RET proto-oncogene are associated with MEN 2A and FMTC. Hum Mol Genet 1993;2:851–856. Available at: https://www.ncbi.nlm.nih.gov/pubmed/8103403.

12. Jenson RT, Norton JA. Carcinoid Tumors and Carcinoid Syndrome. In: DeVita VT, Hellman S, Rosenberg SA, eds. Cancer: Principles and Practice of Oncology Vol. Vol 2 (ed 6). Philadelphia, Pa: Lippincott Williams and Wilkins; 2001:1813–1826.

13. Joynt KE, Moslehi JJ, Baughman KL. Paragangliomas: etiology, presentation, and management. Cardiol Rev 2009;17:159–164. Available at: https://www.ncbi.nlm.nih.gov/pubmed/19525677.

14. WHO Classification of Tumours Editorial Board. Digestive system tumours [Internet]. Lyon (France): International Agency for Research on Cancer; 2019 [cited 2025 July 28]. (WHO classification of tumours series, 5th ed.; vol. 1). Available from: https://tumourclassification.iarc.who.int/chapters/31.

15. Nolting S, Bechmann N, Taieb D, et al. Personalized management of pheochromocytoma and paraganglioma. Endocr Rev 2022;43:199–239. Available at: https://www.ncbi.nlm.nih.gov/pubmed/34147030.

16. Taieb D, Wanna GB, Ahmad M, et al. Clinical consensus guideline on the management of phaeochromocytoma and paraganglioma in patients harbouring germline SDHD pathogenic variants. Lancet Diabetes

Version 3.2025 © 2025 National Comprehensive Cancer Network© (NCCN©), All rights reserved. NCCN Guidelines® and this illustration may not be reproduced in any form without the express written permission of NCCN.

PLEASE NOTE that use of this NCCN Content is governed by the End-User License Agreement, and you MAY NOT distribute this Content or use it with any artificial intelligence model or tool.
Printed by Galya Basol Kochav on 1/7/2026 1:55:52 PM. Copyright © 2026 National Comprehensive Cancer Network, Inc. All Rights Reserved.

Endocrinol 2023;11:345–361. Available at: https://www.ncbi.nlm.nih.gov/pubmed/37011647.

17. Chen H, Sippel RS, O'Dorisio MS, et al. The North American Neuroendocrine Tumor Society consensus guideline for the diagnosis and management of neuroendocrine tumors: pheochromocytoma, paraganglioma, and medullary thyroid cancer. Pancreas 2010;39:775–783. Available at: https://www.ncbi.nlm.nih.gov/pubmed/20664475.

18. Plouin PF, Amar L, Dekkers OM, et al. European Society of Endocrinology Clinical Practice Guideline for long-term follow-up of patients operated on for a phaeochromocytoma or a paraganglioma. Eur J Endocrinol 2016;174:G1–G10. Available at: https://www.ncbi.nlm.nih.gov/pubmed/27048283.

19. Lenders JWM, Eisenhofer G. Update on modern management of pheochromocytoma and paraganglioma. Endocrinol Metab (Seoul) 2017;32:152–161. Available at: https://www.ncbi.nlm.nih.gov/pubmed/28685506.

20. Fassnacht M, Kroiss M, Allolio B. Update in adrenocortical carcinoma. J Clin Endocrinol Metab 2013;98:4551–4564. Available at: https://www.ncbi.nlm.nih.gov/pubmed/24081734.

21. Fassnacht M, Dekkers OM, Else T, et al. European Society of Endocrinology Clinical Practice Guidelines on the management of adrenocortical carcinoma in adults, in collaboration with the European Network for the Study of Adrenal Tumors. Eur J Endocrinol 2018;179:G1–G46. Available at: https://www.ncbi.nlm.nih.gov/pubmed/30299884.

22. Else T, Kim AC, Sabolch A, et al. Adrenocortical carcinoma. Endocr Rev 2014;35:282–326. Available at: https://www.ncbi.nlm.nih.gov/pubmed/24423978.

23. Koch CA, Pacak K, Chrousos GP. The molecular pathogenesis of hereditary and sporadic adrenocortical and adrenomedullary tumors. J Clin Endocrinol Metab 2002;87:5367–5384. Available at: https://www.ncbi.nlm.nih.gov/pubmed/12466322.

24. Lynch HT, Radford B, Lynch JF. SBLA syndrome revisited. Oncology 1990;47:75–79. Available at: https://www.ncbi.nlm.nih.gov/pubmed/2300390.

25. Soon PS, McDonald KL, Robinson BG, Sidhu SB. Molecular markers and the pathogenesis of adrenocortical cancer. Oncologist 2008;13:548–561. Available at: https://www.ncbi.nlm.nih.gov/pubmed/18515740.

26. Brandi ML, Gagel RF, Angeli A, et al. Guidelines for diagnosis and therapy of MEN type 1 and type 2. J Clin Endocrinol Metab 2001;86:5658–5671. Available at: https://www.ncbi.nlm.nih.gov/pubmed/11739416.

27. Raymond VM, Everett JN, Furtado LV, et al. Adrenocortical carcinoma is a lynch syndrome-associated cancer. J Clin Oncol 2013;31:3012–3018. Available at: https://www.ncbi.nlm.nih.gov/pubmed/23752102.

28. Petr EJ, Else T. Genetic predisposition to endocrine tumors: Diagnosis, surveillance and challenges in care. Semin Oncol 2016;43:582–590. Available at: https://www.ncbi.nlm.nih.gov/pubmed/27899191.

29. Ohgaki H, Kleihues P, Heitz PU. p53 mutations in sporadic adrenocortical tumors. Int J Cancer 1993;54:408–410. Available at: https://www.ncbi.nlm.nih.gov/pubmed/8509216.

30. Reincke M, Karl M, Travis WH, et al. p53 mutations in human adrenocortical neoplasms: immunohistochemical and molecular studies. J Clin Endocrinol Metab 1994;78:790–794. Available at: https://www.ncbi.nlm.nih.gov/pubmed/8126158.

31. Gicquel C, Bertagna X, Schneid H, et al. Rearrangements at the 11p15 locus and overexpression of insulin-like growth factor-II gene in sporadic adrenocortical tumors. J Clin Endocrinol Metab 1994;78:1444–1453. Available at: http://www.ncbi.nlm.nih.gov/pubmed/7911125.

32. Gicquel C, Raffin-Sanson ML, Gaston V, et al. Structural and functional abnormalities at 11p15 are associated with the malignant phenotype in sporadic adrenocortical tumors: study on a series of 82

Version 3.2025 © 2025 National Comprehensive Cancer Network© (NCCN©), All rights reserved. NCCN Guidelines® and this illustration may not be reproduced in any form without the express written permission of NCCN.

PLEASE NOTE that use of this NCCN Content is governed by the End-User License Agreement, and you MAY NOT distribute this Content or use it with any artificial intelligence model or tool.
Printed by Galya Basol Kochav on 1/7/2026 1:55:52 PM. Copyright © 2026 National Comprehensive Cancer Network, Inc. All Rights Reserved.

tumors. J Clin Endocrinol Metab 1997;82:2559–2565. Available at: http://www.ncbi.nlm.nih.gov/pubmed/9253334.

33. PubMed Overview. Available at: https://pubmed.ncbi.nlm.nih.gov/about/. Accessed August 8, 2023.

34. Freedman-Cass DA, Fischer T, Alpert AB, et al. The value and process of inclusion: Using sensitive, respectful, and inclusive language and images in NCCN content. J Natl Compr Canc Netw 2023;21:434–441. Available at: https://www.ncbi.nlm.nih.gov/pubmed/37156485.

35. Rindi G, Kloppel G, Alhman H, et al. TNM staging of foregut (neuro)endocrine tumors: a consensus proposal including a grading system. Virchows Arch 2006;449:395–401. Available at: https://www.ncbi.nlm.nih.gov/pubmed/16967267.

36. Rindi G, Kloppel G, Couvelard A, et al. TNM staging of midgut and hindgut (neuro) endocrine tumors: a consensus proposal including a grading system. Virchows Arch 2007;451:757–762. Available at: https://www.ncbi.nlm.nih.gov/pubmed/17674042.

37. Marchevsky AM, Hendifar A, Walts AE. The use of Ki-67 labeling index to grade pulmonary well-differentiated neuroendocrine neoplasms: current best evidence. Mod Pathol 2018;31:1523–1531. Available at: https://www.ncbi.nlm.nih.gov/pubmed/29802361.

38. Rindi G, Klimstra DS, Abedi-Ardekani B, et al. A common classification framework for neuroendocrine neoplasms: an International Agency for Research on Cancer (IARC) and World Health Organization (WHO) expert consensus proposal. Mod Pathol 2018;31:1770–1786. Available at: https://www.ncbi.nlm.nih.gov/pubmed/30140036.

39. WHO Classification of Tumours Editorial Board. Endocrine and neuroendocrine tumours [Internet]. Lyon (France): International Agency for Research on Cancer; 2025 [cited 2025 July 28]. (WHO classification of tumours series, 5th ed.; vol. 10). Available from: https://tumourclassification.iarc.who.int/chapters/53.

40. Hochwald SN, Zee S, Conlon KC, et al. Prognostic factors in pancreatic endocrine neoplasms: an analysis of 136 cases with a proposal for low-grade and intermediate-grade groups. J Clin Oncol 2002;20:2633–2642. Available at: https://www.ncbi.nlm.nih.gov/pubmed/12039924.

41. Panzuto F, Boninsegna L, Fazio N, et al. Metastatic and locally advanced pancreatic endocrine carcinomas: analysis of factors associated with disease progression. J Clin Oncol 2011;29:2372–2377. Available at: https://www.ncbi.nlm.nih.gov/pubmed/21555696.

42. Panzuto F, Nasoni S, Falconi M, et al. Prognostic factors and survival in endocrine tumor patients: comparison between gastrointestinal and pancreatic localization. Endocr Relat Cancer 2005;12:1083–1092. Available at: \http://www.ncbi.nlm.nih.gov/pubmed/16322345.

43. Pape UF, Jann H, Muller-Nordhorn J, et al. Prognostic relevance of a novel TNM classification system for upper gastroenteropancreatic neuroendocrine tumors. Cancer 2008;113:256–265. Available at: https://www.ncbi.nlm.nih.gov/pubmed/18506737.

44. Rindi G, Bordi C, La Rosa S, et al. Gastroenteropancreatic (neuro)endocrine neoplasms: the histology report. Dig Liver Dis 2011;43 Suppl 4:S356–360. Available at: https://www.ncbi.nlm.nih.gov/pubmed/21459341.

45. Basturk O, Yang Z, Tang LH, et al. The high-grade (WHO G3) pancreatic neuroendocrine tumor category is morphologically and biologically heterogenous and includes both well differentiated and poorly differentiated neoplasms. Am J Surg Pathol 2015;39:683–690. Available at: https://www.ncbi.nlm.nih.gov/pubmed/25723112.

46. van Velthuysen ML, Groen EJ, van der Noort V, et al. Grading of neuroendocrine neoplasms: mitoses and Ki-67 are both essential. Neuroendocrinology 2014;100:221–227. Available at: https://www.ncbi.nlm.nih.gov/pubmed/25358267.

47. Travis W, Cree I, Papotti M. Lung neuroendocrine neoplasms: Introduction. WHO Classification of Tumours Editorial Board. Thoracic

Version 3.2025 © 2025 National Comprehensive Cancer Network© (NCCN©), All rights reserved. NCCN Guidelines® and this illustration may not be reproduced in any form without the express written permission of NCCN.

PLEASE NOTE that use of this NCCN Content is governed by the End-User License Agreement, and you MAY NOT distribute this Content or use it with any artificial intelligence model or tool.
Printed by Galya Basol Kochav on 1/7/2026 1:55:52 PM. Copyright © 2026 National Comprehensive Cancer Network, Inc. All Rights Reserved.

Tumours [Internet]. Vol. 5 (ed 5th ed). Lyon (France): International Agency for Research on Cancer; 2021.

48. Ströbel P, Marchevsky A, Marom E. Thymic neuroendocrine neoplasms: Introduction. WHO Classification of Tumours Editorial Board. Thoracic Tumours [Internet]. Vol. 5 (ed 5th ed). Lyon (France): International Agency for Research on Cancer; 2021.

49. Klimstra DS. Pathology reporting of neuroendocrine tumors: essential elements for accurate diagnosis, classification, and staging. Semin Oncol 2013;40:23–36. Available at: https://www.ncbi.nlm.nih.gov/pubmed/23391110.

50. Kulke MH. Are neuroendocrine tumors going mainstream? J Clin Oncol 2013;31:404–405. Available at: https://www.ncbi.nlm.nih.gov/pubmed/23248246.

51. Sorbye H, Welin S, Langer SW, et al. Predictive and prognostic factors for treatment and survival in 305 patients with advanced gastrointestinal neuroendocrine carcinoma (WHO G3): the NORDIC NEC study. Ann Oncol 2013;24:152–160. Available at: https://www.ncbi.nlm.nih.gov/pubmed/22967994.

52. Scarpa A, Mantovani W, Capelli P, et al. Pancreatic endocrine tumors: improved TNM staging and histopathological grading permit a clinically efficient prognostic stratification of patients. Mod Pathol 2010;23:824–833. Available at: https://www.ncbi.nlm.nih.gov/pubmed/20305616.

53. Strosberg JR, Weber JM, Feldman M, et al. Prognostic validity of the American Joint Committee on Cancer staging classification for midgut neuroendocrine tumors. J Clin Oncol 2013;31:420–425. Available at: https://www.ncbi.nlm.nih.gov/pubmed/23248248.

54. Edge SB, Byrd DR, Compton CC, et al., eds. AJCC Cancer Staging Manual (ed 7th). New York: Springer; 2010.

55. Amin MB, Edge SB, Greene FL, et al. AJCC Cancer Staging Manual, 8th edition. New York: Springer; 2017.

56. Halfdanarson T, Anaya DA, Shi C, et al. AJCC Cancer Staging System: Neuroendocrine Tumors of the Jejunum and Ileum (Version 9 of the AJCC Cancer Staging System). Chicago, Illinois: American College of Surgeons; 2023.

57. Ge P, Mittra E, Shi C, et al. AJCC Cancer Staging System: Neuroendocrine Tumors of the Duodenum and Ampulla of Vater (Version 9 of the AJCC Cancer Staging System) Chicago, Illinois: American College of Surgeons; 2023.

58. Overman MJ, Kakar S, Carr NJ, et al. AJCC Cancer Staging System: Appendix: Version 9 of AJCC Cancer Staging System (Version 9 of the AJCC Cancer Staging System). Chicago, Illinois: American College of Surgeons; 2023.

59. Shi C, Bellizzi AM, Mittra E, et al. AJCC Cancer Staging System: Neuroendocrine Tumors of the Colon and Rectum (Version 9 of the AJCC Cancer Staging System) Chicago, Illinois: American College of Surgeons; 2023.

60. Bellizzi AM, O'Toole D, Mittra E, et al. AJCC Cancer Staging System: Neuroendocrine Tumors of the Colon and Rectum (Version 9 of the AJCC Cancer Staging System) Chicago, Illinois: American College of Surgeons; 2023.

61. O'Toole D, Shi C, Dasari A, et al. AJCC Cancer Staging System: Neuroendocrine Tumors of the Stomach (Version 9 of the AJCC Cancer Staging System). Chicago, Illinois: American College of Surgeons; 2023.

62. Rindi G, Dasari A, Mittra E, et al. AJCC Cancer Staging System: Neuroendocrine Tumors of the Pancreas (Version 9 of the AJCC Cancer Staging System). Chicago, Illinois: American College of Surgeons; 2023.

63. Chagpar R, Chiang YJ, Xing Y, et al. Neuroendocrine tumors of the colon and rectum: prognostic relevance and comparative performance of current staging systems. Ann Surg Oncol 2013;20:1170–1178. Available at: https://www.ncbi.nlm.nih.gov/pubmed/23212760.

Version 3.2025 © 2025 National Comprehensive Cancer Network© (NCCN©), All rights reserved. NCCN Guidelines® and this illustration may not be reproduced in any form without the express written permission of NCCN.

PLEASE NOTE that use of this NCCN Content is governed by the End-User License Agreement, and you MAY NOT distribute this Content or use it with any artificial intelligence model or tool.
Printed by Galya Basol Kochav on 1/7/2026 1:55:52 PM. Copyright © 2026 National Comprehensive Cancer Network, Inc. All Rights Reserved.

64. Landry CS, Woodall C, Scoggins CR, et al. Analysis of 900 appendiceal carcinoid tumors for a proposed predictive staging system. Arch Surg 2008;143:664–670; discussion 670. Available at: https://www.ncbi.nlm.nih.gov/pubmed/18645109.

65. Landry CS, Brock G, Scoggins CR, et al. A proposed staging system for rectal carcinoid tumors based on an analysis of 4701 patients. Surgery 2008;144:460–466. Available at: https://www.ncbi.nlm.nih.gov/pubmed/18707046.

66. Landry CS, Brock G, Scoggins CR, et al. A proposed staging system for small bowel carcinoid tumors based on an analysis of 6,380 patients. Am J Surg 2008;196:896–903; discussion 903. Available at: https://www.ncbi.nlm.nih.gov/pubmed/19095106.

67. Landry CS, Brock G, Scoggins CR, et al. Proposed staging system for colon carcinoid tumors based on an analysis of 2,459 patients. J Am Coll Surg 2008;207:874–881. Available at: https://www.ncbi.nlm.nih.gov/pubmed/19183534.

68. Landry CS, Brock G, Scoggins CR, et al. A proposed staging system for gastric carcinoid tumors based on an analysis of 1,543 patients. Ann Surg Oncol 2009;16:51–60. Available at: https://www.ncbi.nlm.nih.gov/pubmed/18953609.

69. Li X, Gou S, Liu Z, et al. Assessment of the American Joint Commission on Cancer 8th edition staging system for patients with pancreatic neuroendocrine tumors: A Surveillance, Epidemiology, and End Results analysis. Cancer Med 2018;7:626–634. Available at: https://www.ncbi.nlm.nih.gov/pubmed/29380547.

70. Kim MK, Warner RR, Roayaie S, et al. Revised staging classification improves outcome prediction for small intestinal neuroendocrine tumors. J Clin Oncol 2013;31:3776–3781. Available at: https://www.ncbi.nlm.nih.gov/pubmed/24043726.

71. Strosberg JR, Cheema A, Weber J, et al. Prognostic validity of a novel American Joint Committee on Cancer Staging Classification for pancreatic neuroendocrine tumors. J Clin Oncol 2011;29:3044–3049. Available at: https://www.ncbi.nlm.nih.gov/pubmed/21709192.

72. Bilimoria KY, Bentrem DJ, Merkow RP, et al. Application of the pancreatic adenocarcinoma staging system to pancreatic neuroendocrine tumors. J Am Coll Surg 2007;205:558–563. Available at: https://www.ncbi.nlm.nih.gov/pubmed/17903729.

73. Halfdanarson TR, Rabe KG, Rubin J, Petersen GM. Pancreatic neuroendocrine tumors (PNETs): incidence, prognosis and recent trend toward improved survival. Ann Oncol 2008;19:1727–1733. Available at: https://www.ncbi.nlm.nih.gov/pubmed/18515795.

74. Curran T, Pockaj BA, Gray RJ, et al. Importance of lymph node involvement in pancreatic neuroendocrine tumors: impact on survival and implications for surgical resection. J Gastrointest Surg 2015;19:152–160; discussion 160. Available at: https://www.ncbi.nlm.nih.gov/pubmed/25118642.

75. Qadan M, Ma Y, Visser BC, et al. Reassessment of the current American Joint Committee on Cancer staging system for pancreatic neuroendocrine tumors. J Am Coll Surg 2014;218:188–195. Available at: https://www.ncbi.nlm.nih.gov/pubmed/24321190.

76. Chan K, Chauhan A, Shi C. AJCC cancer staging system version 9: Practice-informing updates for gastroenteropancreatic neuroendocrine tumors. Ann Surg Oncol 2024;31:4834–4836. Available at: https://www.ncbi.nlm.nih.gov/pubmed/38869764.

77. Ballian N, Loeffler AG, Rajamanickam V, et al. A simplified prognostic system for resected pancreatic neuroendocrine neoplasms. HPB (Oxford) 2009;11:422–428. Available at: https://www.ncbi.nlm.nih.gov/pubmed/19768147.

78. Klimstra DS, Modlin IR, Adsay NV, et al. Pathology reporting of neuroendocrine tumors: application of the Delphic consensus process to the development of a minimum pathology data set. Am J Surg Pathol 2010;34:300–313. Available at: https://www.ncbi.nlm.nih.gov/pubmed/20118772.

Version 3.2025 © 2025 National Comprehensive Cancer Network© (NCCN©), All rights reserved. NCCN Guidelines® and this illustration may not be reproduced in any form without the express written permission of NCCN.

PLEASE NOTE that use of this NCCN Content is governed by the End-User License Agreement, and you MAY NOT distribute this Content or use it with any artificial intelligence model or tool.
Printed by Galya Basol Kochav on 1/7/2026 1:55:52 PM. Copyright © 2026 National Comprehensive Cancer Network, Inc. All Rights Reserved.

79. Rossi RE, Garcia-Hernandez J, Meyer T, et al. Chromogranin A as a predictor of radiological disease progression in neuroendocrine tumours. Ann Transl Med 2015;3:118. Available at: https://www.ncbi.nlm.nih.gov/pubmed/26207246.

80. Mosli HH, Dennis A, Kocha W, et al. Effect of short-term proton pump inhibitor treatment and its discontinuation on chromogranin A in healthy subjects. J Clin Endocrinol Metab 2012;97:E1731–1735. Available at: https://www.ncbi.nlm.nih.gov/pubmed/22723311.

81. Hsiao RJ, Mezger MS, O'Connor DT. Chromogranin A in uremia: progressive retention of immunoreactive fragments. Kidney Int 1990;37:955–964. Available at: https://www.ncbi.nlm.nih.gov/pubmed/2313983.

82. Modlin IM, Kidd M, Malczewska A, et al. The NETest: The clinical utility of multigene blood analysis in the diagnosis and management of neuroendocrine tumors. Endocrinol Metab Clin North Am 2018;47:485–504. Available at: https://www.ncbi.nlm.nih.gov/pubmed/30098712.

83. Al-Toubah T, Cives M, Valone T, et al. Sensitivity and specificity of the NETest: A validation study. Neuroendocrinology 2021;111:580–585. Available at: https://www.ncbi.nlm.nih.gov/pubmed/32615553.

84. Gertner J, Tsoli M, Hayes AR, et al. The clinical utility of the NETest in patients with small intestinal neuroendocrine neoplasms (Si-NENs): A "real-life" study. Cancers (Basel) 2024;16. Available at: https://www.ncbi.nlm.nih.gov/pubmed/39061146.

85. Puliani G, Di Vito V, Feola T, et al. NETest: A systematic review focusing on the prognostic and predictive role. Neuroendocrinology 2022;112:523–536. Available at: https://www.ncbi.nlm.nih.gov/pubmed/34515175.

86. Modlin IM, Kidd M, Falconi M, et al. A multigenomic liquid biopsy biomarker for neuroendocrine tumor disease outperforms CgA and has surgical and clinical utility. Ann Oncol 2021;32:1425–1433. Available at: https://www.ncbi.nlm.nih.gov/pubmed/34390828.

87. Modlin IM, Kidd M, Frilling A, et al. Molecular genomic assessment using a blood-based mRNA signature (NETest) is cost-effective and predicts neuroendocrine tumor recurrence with 94% accuracy. Ann Surg 2021;274:481–490. Available at: https://www.ncbi.nlm.nih.gov/pubmed/34183517.

88. Modlin IM, Kidd M, Oberg K, et al. Early identification of residual disease after neuroendocrine tumor resection using a liquid biopsy multigenomic mRNA signature (NETest). Ann Surg Oncol 2021;28:7506–7517. Available at: https://www.ncbi.nlm.nih.gov/pubmed/34008138.

89. Bodei L, Kidd MS, Singh A, et al. PRRT genomic signature in blood for prediction of (177)Lu-octreotate efficacy. Eur J Nucl Med Mol Imaging 2018;45:1155–1169. Available at: https://www.ncbi.nlm.nih.gov/pubmed/29484451.

90. Qian ZR, Ter-Minassian M, Chan JA, et al. Prognostic significance of MTOR pathway component expression in neuroendocrine tumors. J Clin Oncol 2013;31:3418–3425. Available at: https://www.ncbi.nlm.nih.gov/pubmed/23980085.

91. Francis JM, Kiezun A, Ramos AH, et al. Somatic mutation of CDKN1B in small intestine neuroendocrine tumors. Nat Genet 2013;45:1483–1486. Available at: https://www.ncbi.nlm.nih.gov/pubmed/24185511.

92. Kim HS, Lee HS, Nam KH, et al. p27 loss is associated with poor prognosis in gastroenteropancreatic neuroendocrine tumors. Cancer Res Treat 2014;46:383–392. Available at: https://www.ncbi.nlm.nih.gov/pubmed/25036575.

93. Khan MS, Kirkwood A, Tsigani T, et al. Circulating tumor cells as prognostic markers in neuroendocrine tumors. J Clin Oncol 2013;31:365–372. Available at: https://www.ncbi.nlm.nih.gov/pubmed/23248251.

94. Oberg K, Modlin IM, De Herder W, et al. Consensus on biomarkers for neuroendocrine tumour disease. Lancet Oncol 2015;16:e435–e446. Available at: https://www.ncbi.nlm.nih.gov/pubmed/26370353.

Version 3.2025 © 2025 National Comprehensive Cancer Network© (NCCN©), All rights reserved. NCCN Guidelines® and this illustration may not be reproduced in any form without the express written permission of NCCN.

PLEASE NOTE that use of this NCCN Content is governed by the End-User License Agreement, and you MAY NOT distribute this Content or use it with any artificial intelligence model or tool.
Printed by Galya Basol Kochav on 1/7/2026 1:55:52 PM. Copyright © 2026 National Comprehensive Cancer Network, Inc. All Rights Reserved.

95. Raj N, Shah R, Stadler Z, et al. Real-time genomic characterization of metastatic pancreatic neuroendocrine tumors has prognostic implications and identifies potential germline actionability. JCO Precis Oncol 2018;2018. Available at: https://www.ncbi.nlm.nih.gov/pubmed/30687805.

96. Scarpa A, Chang DK, Nones K, et al. Whole-genome landscape of pancreatic neuroendocrine tumours. Nature 2017;543:65–71. Available at: https://www.ncbi.nlm.nih.gov/pubmed/28199314.

97. Mohindroo C, Baydogan S, Agarwal P, et al. Germline testing identifies pathogenic/likely pathogenic variants in patients with pancreatic neuroendocrine tumors. Cancer Prev Res (Phila) 2024;17:335–342. Available at: https://www.ncbi.nlm.nih.gov/pubmed/38662083.

98. Alexandraki KI, Grossman AB. The ectopic ACTH syndrome. Rev Endocr Metab Disord 2010;11:117–126. Available at: https://www.ncbi.nlm.nih.gov/pubmed/20544290.

99. Neary NM, Lopez-Chavez A, Abel BS, et al. Neuroendocrine ACTH-producing tumor of the thymus--experience with 12 patients over 25 years. J Clin Endocrinol Metab 2012;97:2223–2230. Available at: https://www.ncbi.nlm.nih.gov/pubmed/22508705.

100. Pasieka JL, McKinnon JG, Kinnear S, et al. Carcinoid syndrome symposium on treatment modalities for gastrointestinal carcinoid tumours: symposium summary. Can J Surg 2001;44:25–32. Available at: https://www.ncbi.nlm.nih.gov/pubmed/11220795.

101. Palaniswamy C, Frishman WH, Aronow WS. Carcinoid heart disease. Cardiol Rev 2012;20:167–176. Available at: https://www.ncbi.nlm.nih.gov/pubmed/22314145.

102. Choti MA, Bobiak S, Strosberg JR, et al. Prevalence of functional tumors in neuroendocrine carcinoma: An analysis from the NCCN NET database [Abstract]. ASCO Meeting Abstracts 2012;30:4126. Available at: http://meetinglibrary.asco.org/content/98670-114.

103. Soga J, Yakuwa Y, Osaka M. Carcinoid syndrome: a statistical evaluation of 748 reported cases. J Exp Clin Cancer Res 1999;18:133–141. Available at: https://www.ncbi.nlm.nih.gov/pubmed/10464698.

104. Thorson AH. Studies on carcinoid disease. Acta Med Scand Suppl 1958;334:1–132. Available at: https://www.ncbi.nlm.nih.gov/pubmed/13544882.

105. Öberg KE, Reubi JC, Kwekkeboom DJ, Krenning EP. Role of somatostatins in gastroenteropancreatic neuroendocrine tumor development and therapy. Gastroenterology 2010;139:742–753.e741. Available at: https://doi.org/10.1053/j.gastro.2010.07.002.

106. Gabriel M, Decristoforo C, Kendler D, et al. 68Ga-DOTA-Tyr3-octreotide PET in neuroendocrine tumors: comparison with somatostatin receptor scintigraphy and CT. J Nucl Med 2007;48:508–518. Available at: https://www.ncbi.nlm.nih.gov/pubmed/17401086.

107. Sadowski SM, Neychev V, Millo C, et al. Prospective study of 68Ga-DOTATATE positron emission tomography/computed tomography for detecting gastro-entero-pancreatic neuroendocrine tumors and unknown primary sites. J Clin Oncol 2016;34:588–596. Available at: https://www.ncbi.nlm.nih.gov/pubmed/26712231.

108. Srirajaskanthan R, Kayani I, Quigley AM, et al. The role of 68Ga-DOTATATE PET in patients with neuroendocrine tumors and negative or equivocal findings on 111In-DTPA-octreotide scintigraphy. J Nucl Med 2010;51:875–882. Available at: https://www.ncbi.nlm.nih.gov/pubmed/20484441.

109. Haug AR, Cindea-Drimus R, Auernhammer CJ, et al. Neuroendocrine tumor recurrence: diagnosis with 68Ga-DOTATATE PET/CT. Radiology 2014;270:517–525. Available at: https://www.ncbi.nlm.nih.gov/pubmed/24056402.

110. Haug AR, Cindea-Drimus R, Auernhammer CJ, et al. The role of 68Ga-DOTATATE PET/CT in suspected neuroendocrine tumors. J Nucl Med 2012;53:1686–1692. Available at: https://www.ncbi.nlm.nih.gov/pubmed/22984220.

Version 3.2025 © 2025 National Comprehensive Cancer Network© (NCCN©), All rights reserved. NCCN Guidelines® and this illustration may not be reproduced in any form without the express written permission of NCCN.

PLEASE NOTE that use of this NCCN Content is governed by the End-User License Agreement, and you MAY NOT distribute this Content or use it with any artificial intelligence model or tool.
Printed by Galya Basol Kochav on 1/7/2026 1:55:52 PM. Copyright © 2026 National Comprehensive Cancer Network, Inc. All Rights Reserved.

111. Singh S, Poon R, Wong R, Metser U. 68Ga PET imaging in patients with neuroendocrine tumors: A systematic review and meta-analysis. Clin Nucl Med 2018;43:802–810. Available at: https://www.ncbi.nlm.nih.gov/pubmed/30247209.

112. Deppen SA, Liu E, Blume JD, et al. Safety and efficacy of 68Ga-DOTATATE PET/CT for diagnosis, staging, and treatment management of neuroendocrine tumors. J Nucl Med 2016;57:708–714. Available at: https://www.ncbi.nlm.nih.gov/pubmed/26769865.

113. Hope TA, Bergsland EK, Bozkurt MF, et al. Appropriate use criteria for somatostatin receptor PET imaging in neuroendocrine tumors. J Nucl Med 2018;59:66–74. Available at: https://www.ncbi.nlm.nih.gov/pubmed/29025982.

114. Ayati N, Lee ST, Zakavi R, et al. Long-acting somatostatin analog therapy differentially alters (68)Ga-DOTATATE uptake in normal tissues compared with primary tumors and metastatic lesions. J Nucl Med 2018;59:223–227. Available at: https://www.ncbi.nlm.nih.gov/pubmed/28729431.

115. Yang X, Yang Y, Li Z, et al. Diagnostic value of circulating chromogranin a for neuroendocrine tumors: a systematic review and meta-analysis. PLoS One 2015;10:e0124884. Available at: https://www.ncbi.nlm.nih.gov/pubmed/25894842.

116. Franchina M, Cavalcoli F, Falco O, et al. Biochemical markers for neuroendocrine tumors: traditional circulating markers and recent development-A comprehensive review. Diagnostics (Basel) 2024;14. Available at: https://www.ncbi.nlm.nih.gov/pubmed/38928704.

117. Bevere M, Masetto F, Carazzolo ME, et al. An overview of circulating biomarkers in neuroendocrine neoplasms: A clinical guide. Diagnostics (Basel) 2023;13. Available at: https://www.ncbi.nlm.nih.gov/pubmed/37685358.

118. Florez JC, Shepard JA, Kradin RL. Case records of the Massachusetts General Hospital. Case 17-2013. A 56-year-old woman with poorly controlled diabetes mellitus and fatigue. N Engl J Med 2013;368:2126–2136. Available at: https://www.ncbi.nlm.nih.gov/pubmed/23697472.

119. Moertel CG, Weiland LH, Nagorney DM, Dockerty MB. Carcinoid tumor of the appendix: treatment and prognosis. N Engl J Med 1987;317:1699–1701. Available at: https://www.ncbi.nlm.nih.gov/pubmed/3696178.

120. Sandor A, Modlin IM. A retrospective analysis of 1570 appendiceal carcinoids. Am J Gastroenterol 1998;93:422–428. Available at: https://www.ncbi.nlm.nih.gov/pubmed/9517651.

121. Kleiman DA, Finnerty B, Beninato T, et al. Features associated with metastases among well-differentiated neuroendocrine (carcinoid) tumors of the appendix: The significance of small vessel invasion in addition to size. Dis Colon Rectum 2015;58:1137–1143. Available at: https://www.ncbi.nlm.nih.gov/pubmed/26544810.

122. Ricci C, Ingaldi C, Alberici L, et al. Histopathological diagnosis of appendiceal neuroendocrine neoplasms: when to perform a right hemicolectomy? A systematic review and meta-analysis. Endocrine 2019;66:460–466. Available at: https://www.ncbi.nlm.nih.gov/pubmed/31227991.

123. Man D, Wu J, Shen Z, Zhu X. Prognosis of patients with neuroendocrine tumor: a SEER database analysis. Cancer Manag Res 2018;10:5629–5638. Available at: https://www.ncbi.nlm.nih.gov/pubmed/30519109.

124. Gleeson FC, Levy MJ, Dozois EJ, et al. Endoscopically identified well-differentiated rectal carcinoid tumors: impact of tumor size on the natural history and outcomes. Gastrointest Endosc 2014;80:144–151. Available at: https://www.ncbi.nlm.nih.gov/pubmed/24462168.

125. Soga J. Carcinoids of the rectum: an evaluation of 1271 reported cases. Surg Today 1997;27:112–119. Available at: https://www.ncbi.nlm.nih.gov/pubmed/9017986.

Version 3.2025 © 2025 National Comprehensive Cancer Network© (NCCN©), All rights reserved. NCCN Guidelines® and this illustration may not be reproduced in any form without the express written permission of NCCN.

PLEASE NOTE that use of this NCCN Content is governed by the End-User License Agreement, and you MAY NOT distribute this Content or use it with any artificial intelligence model or tool.
Printed by Galya Basol Kochav on 1/7/2026 1:55:52 PM. Copyright © 2026 National Comprehensive Cancer Network, Inc. All Rights Reserved.

126. Gefen R, Emile SH, Horesh N, et al. When is neoadjuvant chemotherapy indicated in rectal neuroendocrine tumors? An analysis of the National Cancer Database. Tech Coloproctol 2024;28:56. Available at: https://www.ncbi.nlm.nih.gov/pubmed/38772962.

127. Gilligan CJ, Lawton GP, Tang LH, et al. Gastric carcinoid tumors: the biology and therapy of an enigmatic and controversial lesion. Am J Gastroenterol 1995;90:338–352. Available at: https://www.ncbi.nlm.nih.gov/pubmed/7872269.

128. Cao LL, Lu J, Lin JX, et al. Incidence and survival trends for gastric neuroendocrine neoplasms: An analysis of 3523 patients in the SEER database. Eur J Surg Oncol 2018;44:1628–1633. Available at: https://www.ncbi.nlm.nih.gov/pubmed/29983275.

129. Sok C, Ajay PS, Tsagkalidis V, et al. Management of gastric neuroendocrine tumors: A review. Ann Surg Oncol 2024;31:1509–1518. Available at: https://www.ncbi.nlm.nih.gov/pubmed/38062290.

130. Hirasawa T, Yamamoto N, Sano T. Is endoscopic resection appropriate for type 3 gastric neuroendocrine tumors? Retrospective multicenter study. Dig Endosc 2021;33:408–417. Available at: https://www.ncbi.nlm.nih.gov/pubmed/32578248.

131. Saund MS, Al Natour RH, Sharma AM, et al. Tumor size and depth predict rate of lymph node metastasis and utilization of lymph node sampling in surgically managed gastric carcinoids. Ann Surg Oncol 2011;18:2826–2832. Available at: https://www.ncbi.nlm.nih.gov/pubmed/21455598.

132. McCarthy DM. Proton pump inhibitor use, hypergastrinemia, and gastric carcinoids-What is the relationship? Int J Mol Sci 2020;21. Available at: https://www.ncbi.nlm.nih.gov/pubmed/31963924.

133. Sawaid IO, Samson AO. Proton pump inhibitors and cancer risk: A comprehensive review of epidemiological and mechanistic evidence. J Clin Med 2024;13. Available at: https://www.ncbi.nlm.nih.gov/pubmed/38610738.

134. Bakhos CT, Salami AC, Kaiser LR, et al. Thymic neuroendocrine tumors and thymic carcinoma: Demographics, treatment, and survival. Innovations (Phila) 2020;15:468–474. Available at: https://www.ncbi.nlm.nih.gov/pubmed/32938293.

135. Joish VN, Shah S, Tierce JC, et al. Serotonin levels and 1-year mortality in patients with neuroendocrine tumors: a systematic review and meta-analysis. Future Oncol 2019;15:1397–1406. Available at: https://www.ncbi.nlm.nih.gov/pubmed/30734573.

136. Ahmed FA, Wu VS, Kakish H, et al. Surgical management of 1- to 2-cm neuroendocrine tumors of the appendix: Appendectomy or right hemicolectomy? Surgery 2024;175:251–257. Available at: https://www.ncbi.nlm.nih.gov/pubmed/37981548.

137. Nesti C, Brautigam K, Benavent M, et al. Hemicolectomy versus appendectomy for patients with appendiceal neuroendocrine tumours 1-2 cm in size: a retrospective, Europe-wide, pooled cohort study. Lancet Oncol 2023;24:187–194. Available at: https://www.ncbi.nlm.nih.gov/pubmed/36640790.

138. Daskalakis K, Alexandraki K, Kassi E, et al. The risk of lymph node metastases and their impact on survival in patients with appendiceal neuroendocrine neoplasms: A systematic review and meta-analysis of adult and paediatric patients. Endocrine 2020;67:20–34. Available at: https://www.ncbi.nlm.nih.gov/pubmed/31493274.

139. Landry JP, Voros BA, Ramirez RA, et al. Management of appendiceal neuroendocrine tumors: Metastatic potential of small tumors. Ann Surg Oncol 2021;28:751–757. Available at: https://www.ncbi.nlm.nih.gov/pubmed/32691337.

140. Skancke M, Sharp SP, Maron DJ, Wexner SD. Elevated prevalence of nodal positivity in carcinoid tumours of the appendix smaller than 2 cm has a negative impact on overall survival. Colorectal Dis 2020;22:1958–1964. Available at: https://www.ncbi.nlm.nih.gov/pubmed/33463877.

141. Noor M, Huber AR, Cates JMM, Gonzalez RS. Risk factors for progression of appendiceal neuroendocrine tumours: Low-stage tumours

Version 3.2025 © 2025 National Comprehensive Cancer Network© (NCCN©), All rights reserved. NCCN Guidelines® and this illustration may not be reproduced in any form without the express written permission of NCCN.

PLEASE NOTE that use of this NCCN Content is governed by the End-User License Agreement, and you MAY NOT distribute this Content or use it with any artificial intelligence model or tool.
Printed by Galya Basol Kochav on 1/7/2026 1:55:52 PM. Copyright © 2026 National Comprehensive Cancer Network, Inc. All Rights Reserved.

<5 mm appear to be overwhelmingly indolent and may merit a separate designation. Histopathology 2021;79:416–426. Available at: https://www.ncbi.nlm.nih.gov/pubmed/33754384.

142. Strosberg JR, Al-Toubah T. Are hemicolectomies justified for appendiceal neuroendocrine tumours smaller than 2 cm? Lancet Oncol 2023;24:121–122. Available at: https://www.ncbi.nlm.nih.gov/pubmed/36640791.

143. Coskun H, Bostanci O, Dilege ME, et al. Carcinoid tumors of appendix: treatment and outcome. Ulus Travma Acil Cerrahi Derg 2006;12:150–154. Available at: https://www.ncbi.nlm.nih.gov/pubmed/16676255.

144. Murray SE, Lloyd RV, Sippel RS, et al. Postoperative surveillance of small appendiceal carcinoid tumors. Am J Surg 2014;207:342–345; discussion 345. Available at: https://www.ncbi.nlm.nih.gov/pubmed/24393285.

145. Shapiro R, Eldar S, Sadot E, et al. Appendiceal carcinoid at a large tertiary center: pathologic findings and long-term follow-up evaluation. Am J Surg 2011;201:805–808. Available at: https://www.ncbi.nlm.nih.gov/pubmed/21741512.

146. Cwikla JB, Buscombe JR, Caplin ME, et al. Diagnostic imaging of carcinoid metastases to the abdomen and pelvis. Med Sci Monit 2004;10 Suppl 3:9–16. Available at: https://www.ncbi.nlm.nih.gov/pubmed/16538192.

147. Kaltsas G, Rockall A, Papadogias D, et al. Recent advances in radiological and radionuclide imaging and therapy of neuroendocrine tumours. Eur J Endocrinol 2004;151:15–27. Available at: https://www.ncbi.nlm.nih.gov/pubmed/15248818.

148. Davar J, Connolly HM, Caplin ME, et al. Diagnosing and managing carcinoid heart disease in patients with neuroendocrine tumors: An expert statement. J Am Coll Cardiol 2017;69:1288–1304. Available at: https://www.ncbi.nlm.nih.gov/pubmed/28279296.

149. Castillo JG, Naib T, Zacks JS, Adams DH. Echocardiography in functional midgut neuroendocrine tumors: When and how often. Rev Endocr Metab Disord 2017;18:411–421. Available at: https://www.ncbi.nlm.nih.gov/pubmed/29080935.

150. Hofland J, Lamarca A, Steeds R, et al. Synoptic reporting of echocardiography in carcinoid heart disease (ENETS Carcinoid Heart Disease Task Force). J Neuroendocrinol 2022;34:e13060. Available at: https://www.ncbi.nlm.nih.gov/pubmed/34825753.

151. Phan AT, Oberg K, Choi J, et al. NANETS consensus guideline for the diagnosis and management of neuroendocrine tumors: well-differentiated neuroendocrine tumors of the thorax (includes lung and thymus). Pancreas 2010;39:784–798. Available at: https://www.ncbi.nlm.nih.gov/pubmed/20664476.

152. Daskalakis K, Karakatsanis A, Hessman O, et al. Association of a prophylactic surgical approach to stage IV small intestinal neuroendocrine tumors with survival. JAMA Oncol 2018;4:183–189. Available at: https://www.ncbi.nlm.nih.gov/pubmed/29049611.

153. Gudmundsdottir H, Habermann EB, Vierkant RA, et al. Survival and symptomatic relief after cytoreductive hepatectomy for neuroendocrine tumor liver metastases: Long-term follow-up evaluation of more than 500 patients. Ann Surg Oncol 2023;30:4840–4851. Available at: https://www.ncbi.nlm.nih.gov/pubmed/37208566.

154. Ejaz A, Reames BN, Maithel S, et al. Cytoreductive debulking surgery among patients with neuroendocrine liver metastasis: A multi-institutional analysis. HPB (Oxford) 2018;20:277–284. Available at: https://www.ncbi.nlm.nih.gov/pubmed/28964630.

155. Scott AT, Breheny PJ, Keck KJ, et al. Effective cytoreduction can be achieved in patients with numerous neuroendocrine tumor liver metastases (NETLMs). Surgery 2019;165:166–175. Available at: https://www.ncbi.nlm.nih.gov/pubmed/30343949.

156. Graff-Baker AN, Sauer DA, Pommier SJ, Pommier RF. Expanded criteria for carcinoid liver debulking: Maintaining survival and increasing

Version 3.2025 © 2025 National Comprehensive Cancer Network© (NCCN©), All rights reserved. NCCN Guidelines® and this illustration may not be reproduced in any form without the express written permission of NCCN.

PLEASE NOTE that use of this NCCN Content is governed by the End-User License Agreement, and you MAY NOT distribute this Content or use it with any artificial intelligence model or tool.
Printed by Galya Basol Kochav on 1/7/2026 1:55:52 PM. Copyright © 2026 National Comprehensive Cancer Network, Inc. All Rights Reserved.

the number of eligible patients. Surgery 2014;156:1369–1376; discussion 1376–1367. Available at: https://www.ncbi.nlm.nih.gov/pubmed/25456912.

157. Oberg K, Kvols L, Caplin M, et al. Consensus report on the use of somatostatin analogs for the management of neuroendocrine tumors of the gastroenteropancreatic system. Ann Oncol 2004;15:966–973. Available at: https://www.ncbi.nlm.nih.gov/pubmed/15151956.

158. Rinke A, Muller HH, Schade-Brittinger C, et al. Placebo-controlled, double-blind, prospective, randomized study on the effect of octreotide LAR in the control of tumor growth in patients with metastatic neuroendocrine midgut tumors: a report from the PROMID Study Group. J Clin Oncol 2009;27:4656–4663. Available at: https://www.ncbi.nlm.nih.gov/pubmed/19704057.

159. Rinke A, Wittenberg M, Schade-Brittinger C, et al. Placebo-controlled, double-blind, prospective, randomized study on the effect of octreotide LAR in the control of tumor growth in patients with metastatic neuroendocrine midgut tumors (PROMID): Results of long-term survival. Neuroendocrinology 2017;104:26–32. Available at: https://www.ncbi.nlm.nih.gov/pubmed/26731483.

160. Caplin ME, Pavel M, Cwikla JB, et al. Lanreotide in metastatic enteropancreatic neuroendocrine tumors. N Engl J Med 2014;371:224–233. Available at: https://www.ncbi.nlm.nih.gov/pubmed/25014687.

161. Caplin ME, Pavel M, Cwikla JB, et al. Anti-tumour effects of lanreotide for pancreatic and intestinal neuroendocrine tumours: the CLARINET open-label extension study. Endocr Relat Cancer 2016;23:191–199. Available at: https://www.ncbi.nlm.nih.gov/pubmed/26743120.

162. Pavel M, Cwikla JB, Lombard-Bohas C, et al. Efficacy and safety of high-dose lanreotide autogel in patients with progressive pancreatic or midgut neuroendocrine tumours: CLARINET FORTE phase 2 study results. Eur J Cancer 2021;157:403–414. Available at: https://www.ncbi.nlm.nih.gov/pubmed/34597974.

163. Ito T, Fujimori N, Honma Y, et al. Long-term safety and efficacy of lanreotide autogel in Japanese patients with neuroendocrine tumors: Final results of a phase II open-label extension study. Asia Pac J Clin Oncol 2021;17:e153–e161. Available at: https://www.ncbi.nlm.nih.gov/pubmed/32757459.

164. Strosberg J, El-Haddad G, Wolin E, et al. Phase 3 trial of (177)Lu-Dotatate for midgut neuroendocrine tumors. N Engl J Med 2017;376:125–135. Available at: https://www.ncbi.nlm.nih.gov/pubmed/28076709.

165. Strosberg JR, Caplin ME, Kunz PL, et al. 177Lu-Dotatate plus long-acting octreotide versus highdose long-acting octreotide in patients with midgut neuroendocrine tumours (NETTER-1): Final overall survival and long-term safety results from an open-label, randomised, controlled, phase 3 trial. Lancet Oncol 2021;22:1752–1763. Available at: https://www.ncbi.nlm.nih.gov/pubmed/34793718.

166. Singh S, Halperin D, Myrehaug S, et al. [(177)Lu]Lu-DOTA-TATE plus long-acting octreotide versus high-dose long-acting octreotide for the treatment of newly diagnosed, advanced grade 2-3, well-differentiated, gastroenteropancreatic neuroendocrine tumours (NETTER-2): An open-label, randomised, phase 3 study. Lancet 2024;403:2807–2817. Available at: https://www.ncbi.nlm.nih.gov/pubmed/38851203.

167. Yao JC, Phan AT, Chang DZ, et al. Efficacy of RAD001 (everolimus) and octreotide LAR in advanced low- to intermediate-grade neuroendocrine tumors: results of a phase II study. J Clin Oncol 2008;26:4311–4318. Available at: https://www.ncbi.nlm.nih.gov/pubmed/18779618.

168. Pavel ME, Hainsworth JD, Baudin E, et al. Everolimus plus octreotide long-acting repeatable for the treatment of advanced neuroendocrine tumours associated with carcinoid syndrome (RADIANT-2): a randomised, placebo-controlled, phase 3 study. Lancet 2011;378:2005–2012. Available at: https://www.ncbi.nlm.nih.gov/pubmed/22119496.

169. Pavel ME, Baudin E, Oberg KE, et al. Efficacy of everolimus plus octreotide LAR in patients with advanced neuroendocrine tumor and carcinoid syndrome: final overall survival from the randomized, placebo-

Version 3.2025 © 2025 National Comprehensive Cancer Network© (NCCN©), All rights reserved. NCCN Guidelines® and this illustration may not be reproduced in any form without the express written permission of NCCN.

PLEASE NOTE that use of this NCCN Content is governed by the End-User License Agreement, and you MAY NOT distribute this Content or use it with any artificial intelligence model or tool.
Printed by Galya Basol Kochav on 1/7/2026 1:55:52 PM. Copyright © 2026 National Comprehensive Cancer Network, Inc. All Rights Reserved.

controlled phase 3 RADIANT-2 study. Ann Oncol 2017;28:1569–1575. Available at: https://www.ncbi.nlm.nih.gov/pubmed/28444114.

170. Choueiri TK, Je Y, Sonpavde G, et al. Incidence and risk of treatment-related mortality in cancer patients treated with the mammalian target of rapamycin inhibitors. Ann Oncol 2013;24:2092–2097. Available at: https://www.ncbi.nlm.nih.gov/pubmed/23658373.

171. Parithivel K, Ramaiya N, Jagannathan JP, et al. Everolimus- and temsirolimus-associated enteritis: report of three cases. J Clin Oncol 2010;29:e404–406. Available at: http://www.ncbi.nlm.nih.gov/pubmed/21357780.

172. Subramaniam S, Zell JA, Kunz PL. Everolimus causing severe hypertriglyceridemia and acute pancreatitis. J Natl Compr Canc Netw 2013;11:5–9. Available at: https://www.ncbi.nlm.nih.gov/pubmed/23307976.

173. Yao JC, Fazio N, Singh S, et al. Everolimus for the treatment of advanced, non-functional neuroendocrine tumours of the lung or gastrointestinal tract (RADIANT-4): a randomised, placebo-controlled, phase 3 study. Lancet 2016;387:968–977. Available at: https://www.ncbi.nlm.nih.gov/pubmed/26703889.

174. Panzuto F, Rinzivillo M, Fazio N, et al. Real-world study of everolimus in advanced progressive neuroendocrine tumors. Oncologist 2014;19:966–974. Available at: https://www.ncbi.nlm.nih.gov/pubmed/25117065.

175. Fazio N, Buzzoni R, Delle Fave G, et al. Everolimus in advanced, progressive, well-differentiated, non-functional neuroendocrine tumors: RADIANT-4 lung subgroup analysis. Cancer Sci 2018;109:174–181. Available at: https://www.ncbi.nlm.nih.gov/pubmed/29055056.

176. Pavel ME, Singh S, Strosberg JR, et al. Health-related quality of life for everolimus versus placebo in patients with advanced, non-functional, well-differentiated gastrointestinal or lung neuroendocrine tumours (RADIANT-4): a multicentre, randomised, double-blind, placebo-controlled, phase 3 trial. Lancet Oncol 2017;18:1411–1422. Available at: https://www.ncbi.nlm.nih.gov/pubmed/28838862.

177. Chan JA, Geyer S, Zemla T, et al. Phase 3 trial of cabozantinib to treat advanced neuroendocrine tumors. N Engl J Med 2024. Available at: https://www.ncbi.nlm.nih.gov/pubmed/39282913.

178. Paulson AS, Bergsland EK. Systemic therapy for advanced carcinoid tumors: where do we go from here? J Natl Compr Canc Netw 2012;10:785–793. Available at: https://www.ncbi.nlm.nih.gov/pubmed/22679120.

179. Medley L, Morel AN, Farrugia D, et al. Phase II study of single agent capecitabine in the treatment of metastatic non-pancreatic neuroendocrine tumours. Br J Cancer 2011;104:1067–1070. Available at: https://www.ncbi.nlm.nih.gov/pubmed/21386841.

180. Girot P, Baudin E, Senellart H, et al. Oxaliplatin and 5-fluorouracil in advanced well-differentiated digestive neuroendocrine tumors: A multicenter national retrospective study from the French Group of Endocrine Tumors. Neuroendocrinology 2022;112:537–546. Available at: https://www.ncbi.nlm.nih.gov/pubmed/34348346.

181. Ekeblad S, Sundin A, Janson ET, et al. Temozolomide as monotherapy is effective in treatment of advanced malignant neuroendocrine tumors. Clin Cancer Res 2007;13:2986–2991. Available at: https://www.ncbi.nlm.nih.gov/pubmed/17505000.

182. Mitry E, Walter T, Baudin E, et al. Bevacizumab plus capecitabine in patients with progressive advanced well-differentiated neuroendocrine tumors of the gastro-intestinal (GI-NETs) tract (BETTER trial)--a phase II non-randomised trial. Eur J Cancer 2014;50:3107–3115. Available at: https://www.ncbi.nlm.nih.gov/pubmed/25454413.

183. Kunz PL, Balise RR, Fehrenbacher L, et al. Oxaliplatin-fluoropyrimidine chemotherapy plus bevacizumab in advanced neuroendocrine tumors: An analysis of 2 phase II trials. Pancreas 2016;45:1394–1400. Available at: https://www.ncbi.nlm.nih.gov/pubmed/27171514.

Version 3.2025 © 2025 National Comprehensive Cancer Network© (NCCN©), All rights reserved. NCCN Guidelines® and this illustration may not be reproduced in any form without the express written permission of NCCN.

PLEASE NOTE that use of this NCCN Content is governed by the End-User License Agreement, and you MAY NOT distribute this Content or use it with any artificial intelligence model or tool.
Printed by Galya Basol Kochav on 1/7/2026 1:55:52 PM. Copyright © 2026 National Comprehensive Cancer Network, Inc. All Rights Reserved.

184. Imhof A, Brunner P, Marincek N, et al. Response, survival, and long-term toxicity after therapy with the radiolabeled somatostatin analogue [90Y-DOTA]-TOC in metastasized neuroendocrine cancers. J Clin Oncol 2011;29:2416–2423. Available at: https://www.ncbi.nlm.nih.gov/pubmed/21555692.

185. Krenning EP, Teunissen JJ, Valkema R, et al. Molecular radiotherapy with somatostatin analogs for (neuro-)endocrine tumors. J Endocrinol Invest 2005;28:146–150. Available at: https://www.ncbi.nlm.nih.gov/pubmed/16625865.

186. Kwekkeboom DJ, Bakker WH, Kam BL, et al. Treatment of patients with gastro-entero-pancreatic (GEP) tumours with the novel radiolabelled somatostatin analogue [177Lu-DOTA(0),Tyr3]octreotate. Eur J Nucl Med Mol Imaging 2003;30:417–422. Available at: https://www.ncbi.nlm.nih.gov/pubmed/12634971.

187. Kwekkeboom DJ, Teunissen JJ, Bakker WH, et al. Radiolabeled somatostatin analog [177Lu-DOTA0,Tyr3]octreotate in patients with endocrine gastroenteropancreatic tumors. J Clin Oncol 2005;23:2754–2762. Available at: https://www.ncbi.nlm.nih.gov/pubmed/15837990.

188. Kwekkeboom DJ, Teunissen JJM, Kam BL, et al. Treatment of patients who have endocrine gastroenteropancreatic tumors with radiolabeled somatostatin analogues. Hematol Oncol Clin North Am 2007;21:561–573. Available at: http://www.ncbi.nlm.nih.gov/pubmed/17548040.

189. Bushnell DL, Jr., O'Dorisio TM, O'Dorisio MS, et al. 90Y-edotreotide for metastatic carcinoid refractory to octreotide. J Clin Oncol 2010;28:1652–1659. Available at: https://www.ncbi.nlm.nih.gov/pubmed/20194865.

190. Kong G, Thompson M, Collins M, et al. Assessment of predictors of response and long-term survival of patients with neuroendocrine tumour treated with peptide receptor chemoradionuclide therapy (PRCRT). Eur J Nucl Med Mol Imaging 2014;41:1831–1844. Available at: https://www.ncbi.nlm.nih.gov/pubmed/24844348.

191. Villard L, Romer A, Marincek N, et al. Cohort study of somatostatin-based radiopeptide therapy with [(90)Y-DOTA]-TOC versus [(90)Y-DOTA]-TOC plus [(177)Lu-DOTA]-TOC in neuroendocrine cancers. J Clin Oncol 2012;30:1100–1106. Available at: https://www.ncbi.nlm.nih.gov/pubmed/22393097.

192. Horsch D, Ezziddin S, Haug A, et al. Peptide receptor radionuclide therapy for neuroendocrine tumors in Germany: first results of a multi-institutional cancer registry. Recent Results Cancer Res 2013;194:457–465. Available at: https://www.ncbi.nlm.nih.gov/pubmed/22918775.

193. Paganelli G, Sansovini M, Nicolini S, et al. (177)Lu-PRRT in advanced gastrointestinal neuroendocrine tumors: 10-year follow-up of the IRST phase II prospective study. Eur J Nucl Med Mol Imaging 2021;48:152–160. Available at: https://www.ncbi.nlm.nih.gov/pubmed/32472437.

194. Saravana-Bawan B, Bajwa A, Paterson J, et al. Efficacy of 177Lu peptide receptor radionuclide therapy for the treatment of neuroendocrine tumors: A Meta-analysis. Clin Nucl Med 2019;44:719–727. Available at: https://www.ncbi.nlm.nih.gov/pubmed/31205149.

195. Travis WD. Advances in neuroendocrine lung tumors. Ann Oncol 2010;21 Suppl 7:vii65–71. Available at: https://www.ncbi.nlm.nih.gov/pubmed/20943645.

196. Baudin E, Capdevila J, Horsch D, et al. Treatment of advanced BP-NETS with lanreotide autogel/depot vs placebo: The phase III SPINET study. Endocr Relat Cancer 2024;31. Available at: https://www.ncbi.nlm.nih.gov/pubmed/38913539.

197. Fazio N, Granberg D, Grossman A, et al. Everolimus plus octreotide long-acting repeatable in patients with advanced lung neuroendocrine tumors: analysis of the phase 3, randomized, placebo-controlled RADIANT-2 study. Chest 2013;143:955–962. Available at: https://www.ncbi.nlm.nih.gov/pubmed/23187897.

198. Chong CR, Wirth LJ, Nishino M, et al. Chemotherapy for locally advanced and metastatic pulmonary carcinoid tumors. Lung Cancer

Version 3.2025 © 2025 National Comprehensive Cancer Network© (NCCN©), All rights reserved. NCCN Guidelines® and this illustration may not be reproduced in any form without the express written permission of NCCN.

PLEASE NOTE that use of this NCCN Content is governed by the End-User License Agreement, and you MAY NOT distribute this Content or use it with any artificial intelligence model or tool.
Printed by Galya Basol Kochav on 1/7/2026 1:55:52 PM. Copyright © 2026 National Comprehensive Cancer Network, Inc. All Rights Reserved.

2014;86:241–246. Available at: https://www.ncbi.nlm.nih.gov/pubmed/25218177.

199. Crona J, Fanola I, Lindholm DP, et al. Effect of temozolomide in patients with metastatic bronchial carcinoids. Neuroendocrinology 2013;98:151–155. Available at: https://www.ncbi.nlm.nih.gov/pubmed/23969949.

200. Al-Toubah T, Morse B, Strosberg J. Capecitabine and temozolomide in advanced lung neuroendocrine neoplasms. Oncologist 2020;25:e48–e52. Available at: https://www.ncbi.nlm.nih.gov/pubmed/31455747.

201. Papaxoinis G, Kordatou Z, McCallum L, et al. Capecitabine and temozolomide in patients with advanced pulmonary carcinoid tumours. Neuroendocrinology 2020;110:413–421. Available at: https://www.ncbi.nlm.nih.gov/pubmed/31437838.

202. Rossi A, Di Maio M, Chiodini P, et al. Carboplatin- or cisplatin-based chemotherapy in first-line treatment of small-cell lung cancer: The COCIS meta-analysis of individual patient data. J Clin Oncol 2012;30:1692–1698. Available at: https://www.ncbi.nlm.nih.gov/pubmed/22473169.

203. Iwasa S, Morizane C, Okusaka T, et al. Cisplatin and etoposide as first-line chemotherapy for poorly differentiated neuroendocrine carcinoma of the hepatobiliary tract and pancreas. Jpn J Clin Oncol 2010;40:313–318. Available at: https://www.ncbi.nlm.nih.gov/pubmed/20047862.

204. Brabander T, van der Zwan WA, Teunissen JJM, et al. Long-term efficacy, survival, and safety of [(177)Lu-DOTA(0),Tyr(3)]octreotate in patients with gastroenteropancreatic and bronchial neuroendocrine tumors. Clin Cancer Res 2017;23:4617–4624. Available at: https://www.ncbi.nlm.nih.gov/pubmed/28428192.

205. Mariniello A, Bodei L, Tinelli C, et al. Long-term results of PRRT in advanced bronchopulmonary carcinoid. Eur J Nucl Med Mol Imaging 2016;43:441–452. Available at: https://www.ncbi.nlm.nih.gov/pubmed/26392198.

206. Ianniello A, Sansovini M, Severi S, et al. Peptide receptor radionuclide therapy with (177)Lu-DOTATATE in advanced bronchial carcinoids: prognostic role of thyroid transcription factor 1 and (18)F-FDG PET. Eur J Nucl Med Mol Imaging 2016;43:1040–1046. Available at: https://www.ncbi.nlm.nih.gov/pubmed/26611427.

207. Zidan L, Iravani A, Oleinikov K, et al. Efficacy and safety of (177)Lu-DOTATATE in lung neuroendocrine tumors: A bicenter study. J Nucl Med 2022;63:218–225. Available at: https://www.ncbi.nlm.nih.gov/pubmed/34049983.

208. Brentjens R, Saltz L. Islet cell tumors of the pancreas: the medical oncologist's perspective. Surg Clin North Am 2001;81:527–542. Available at: https://www.ncbi.nlm.nih.gov/pubmed/11459269.

209. Janson ET, Oberg K. Long-term management of the carcinoid syndrome. Treatment with octreotide alone and in combination with alpha-interferon. Acta Oncol 1993;32:225–229. Available at: https://www.ncbi.nlm.nih.gov/pubmed/7686765.

210. Kvols LK, Moertel CG, O'Connell MJ, et al. Treatment of the malignant carcinoid syndrome. Evaluation of a long-acting somatostatin analogue. N Engl J Med 1986;315:663–666. Available at: https://www.ncbi.nlm.nih.gov/pubmed/2427948.

211. Khan MS, El-Khouly F, Davies P, et al. Long-term results of treatment of malignant carcinoid syndrome with prolonged release Lanreotide (Somatuline Autogel). Aliment Pharmacol Ther 2011;34:235–242. Available at: https://www.ncbi.nlm.nih.gov/pubmed/21585408.

212. O'Toole D, Ducreux M, Bommelaer G, et al. Treatment of carcinoid syndrome: a prospective crossover evaluation of lanreotide versus octreotide in terms of efficacy, patient acceptability, and tolerance. Cancer 2000;88:770–776. Available at: https://www.ncbi.nlm.nih.gov/pubmed/10679645.

213. Ruszniewski P, Ish-Shalom S, Wymenga M, et al. Rapid and sustained relief from the symptoms of carcinoid syndrome: results from an open 6-month study of the 28-day prolonged-release formulation of

Version 3.2025 © 2025 National Comprehensive Cancer Network© (NCCN©), All rights reserved. NCCN Guidelines® and this illustration may not be reproduced in any form without the express written permission of NCCN.

PLEASE NOTE that use of this NCCN Content is governed by the End-User License Agreement, and you MAY NOT distribute this Content or use it with any artificial intelligence model or tool.
Printed by Galya Basol Kochav on 1/7/2026 1:55:52 PM. Copyright © 2026 National Comprehensive Cancer Network, Inc. All Rights Reserved.

lanreotide. Neuroendocrinology 2004;80:244–251. Available at: https://www.ncbi.nlm.nih.gov/pubmed/15627802.

214. Ruszniewski P, Valle JW, Lombard-Bohas C, et al. Patient-reported outcomes with lanreotide Autogel/Depot for carcinoid syndrome: An international observational study. Dig Liver Dis 2016;48:552–558. Available at: https://www.ncbi.nlm.nih.gov/pubmed/26917486.

215. Wymenga AN, Eriksson B, Salmela PI, et al. Efficacy and safety of prolonged-release lanreotide in patients with gastrointestinal neuroendocrine tumors and hormone-related symptoms. J Clin Oncol 1999;17:1111. Available at: https://www.ncbi.nlm.nih.gov/pubmed/10561168.

216. Vinik AI, Wolin EM, Liyanage N, et al. Evaluation of lanreotide depot/autogel efficacy and safety as a carcinoid syndrome treatment (Elect): A randomized, double-blind, placebo-controlled trial. Endocr Pract 2016;22:1068–1080. Available at: https://www.ncbi.nlm.nih.gov/pubmed/27214300.

217. Fisher GA, Jr., Wolin EM, Liyanage N, et al. Lanreotide therapy in carcinoid syndrome: Prospective analysis of patient-reported symptoms in patients responsive to prior octreotide therapy and patients naive to somatostatin analogue therapy in the Elect phase 3 study. Endocr Pract 2018;24:243–255. Available at: https://www.ncbi.nlm.nih.gov/pubmed/29547049.

218. Kulke MH, O'Dorisio T, Phan A, et al. Telotristat etiprate, a novel serotonin synthesis inhibitor, in patients with carcinoid syndrome and diarrhea not adequately controlled by octreotide. Endocr Relat Cancer 2014;21:705–714. Available at: https://www.ncbi.nlm.nih.gov/pubmed/25012985.

219. Pavel M, Horsch D, Caplin M, et al. Telotristat etiprate for carcinoid syndrome: a single-arm, multicenter trial. J Clin Endocrinol Metab 2015;100:1511–1519. Available at: https://www.ncbi.nlm.nih.gov/pubmed/25636046.

220. Kulke MH, Horsch D, Caplin ME, et al. Telotristat ethyl, a tryptophan hydroxylase inhibitor for the treatment of carcinoid syndrome. J Clin Oncol 2017;35:14–23. Available at: https://www.ncbi.nlm.nih.gov/pubmed/27918724.

221. Kulke MH, Kennecke HF, Murali K, Joish VN. Changes in carcinoid syndrome symptoms among patients receiving telotristat ethyl in US clinical practice: Findings from the TELEPRO-II real-world study. Cancer Manag Res 2021;13:7439–7446. Available at: https://www.ncbi.nlm.nih.gov/pubmed/34611437.

222. Strosberg J, Joish VN, Giacalone S, et al. TELEPRO: Patient-reported carcinoid syndrome symptom improvement following initiation of telotristat ethyl in the real world. Oncologist 2019;24:1446–1452. Available at: https://www.ncbi.nlm.nih.gov/pubmed/31189618.

223. Horsch D, Anthony L, Gross DJ, et al. Long-term treatment with telotristat ethyl in patients with carcinoid syndrome symptoms: Results from the TELEPATH study. Neuroendocrinology 2022;112:298–310. Available at: https://www.ncbi.nlm.nih.gov/pubmed/33940581.

224. Habibollahi P, Bai HX, Sanampudi S, et al. Effectiveness of liver-directed therapy for the management of intractable hypoglycemia in metastatic insulinoma. Pancreas 2020;49:763–767. Available at: https://www.ncbi.nlm.nih.gov/pubmed/32541627.

225. Anderson AS, Krauss D, Lang R. Cardiovascular complications of malignant carcinoid disease. Am Heart J 1997;134:693–702. Available at: https://www.ncbi.nlm.nih.gov/pubmed/9351737.

226. Jacobsen MB, Nitter-Hauge S, Bryde PE, Hanssen LE. Cardiac manifestations in mid-gut carcinoid disease. Eur Heart J 1995;16:263–268. Available at: https://www.ncbi.nlm.nih.gov/pubmed/7538079.

227. Bhattacharyya S, Toumpanakis C, Chilkunda D, et al. Risk factors for the development and progression of carcinoid heart disease. Am J Cardiol 2011;107:1221–1226. Available at: https://www.ncbi.nlm.nih.gov/pubmed/21296329.

Version 3.2025 © 2025 National Comprehensive Cancer Network© (NCCN©), All rights reserved. NCCN Guidelines® and this illustration may not be reproduced in any form without the express written permission of NCCN.

PLEASE NOTE that use of this NCCN Content is governed by the End-User License Agreement, and you MAY NOT distribute this Content or use it with any artificial intelligence model or tool.
Printed by Galya Basol Kochav on 1/7/2026 1:55:52 PM. Copyright © 2026 National Comprehensive Cancer Network, Inc. All Rights Reserved.

228. Almquist D, Cabrera A, Sonbol MB, et al. DIPNECH: The Mayo experience [abstract]. J Clin Oncol 2019;37:Abstract e20029. Available at: https://ascopubs.org/doi/abs/10.1200/JCO.2019.37.15_suppl.e20029.

229. Al-Toubah T, Strosberg J, Halfdanarson TR, et al. Somatostatin analogs improve respiratory symptoms in patients with diffuse idiopathic neuroendocrine cell hyperplasia. Chest 2020;158:401–405. Available at: https://www.ncbi.nlm.nih.gov/pubmed/32059961.

230. Yao JC, Eisner MP, Leary C, et al. Population-based study of islet cell carcinoma. Ann Surg Oncol 2007;14:3492–3500. Available at: https://www.ncbi.nlm.nih.gov/pubmed/17896148.

231. Sonbol MB, Mazza GL, Mi L, et al. Survival and incidence patterns of pancreatic neuroendocrine tumors over the last 2 decades: A SEER database analysis. Oncologist 2022;27:573–578. Available at: https://www.ncbi.nlm.nih.gov/pubmed/35348774.

232. Moore FD, Scoinski MA, Joste NE. Endocrine Tumors and Malignancies. In: Skarin A, ed. Atlas of Diagnostic Oncology (ed 3rd). Philadelphia: Elsevier Science Limited; 2003.

233. Rehfeld JF, Federspiel B, Bardram L. A neuroendocrine tumor syndrome from cholecystokinin secretion. N Engl J Med 2013;368:1165–1166. Available at: https://www.ncbi.nlm.nih.gov/pubmed/23514309.

234. Alexakis N, Neoptolemos JP. Pancreatic neuroendocrine tumours. Best Pract Res Clin Gastroenterol 2008;22:183–205. Available at: https://www.ncbi.nlm.nih.gov/pubmed/18206821.

235. Papadopoulou-Marketou N, Tsoli M, Chatzellis E, et al. Hereditary syndromes associated with pancreatic and lung neuroendocrine tumors. Cancers (Basel) 2024;16. Available at: https://www.ncbi.nlm.nih.gov/pubmed/38893191.

236. James PD, Tsolakis AV, Zhang M, et al. Incremental benefit of preoperative EUS for the detection of pancreatic neuroendocrine tumors: a meta-analysis. Gastrointest Endosc 2015;81:848–856.e841. Available at: https://www.ncbi.nlm.nih.gov/pubmed/25805462.

237. Kulke MH, Bendell J, Kvols L, et al. Evolving diagnostic and treatment strategies for pancreatic neuroendocrine tumors. J Hematol Oncol 2011;4:29. Available at: https://www.ncbi.nlm.nih.gov/pubmed/21672194.

238. Bernini GP, Moretti A, Ferdeghini M, et al. A new human chromogranin 'A' immunoradiometric assay for the diagnosis of neuroendocrine tumours. Br J Cancer 2001;84:636–642. Available at: https://www.ncbi.nlm.nih.gov/pubmed/11237384.

239. Campana D, Nori F, Piscitelli L, et al. Chromogranin A: is it a useful marker of neuroendocrine tumors? J Clin Oncol 2007;25:1967–1973. Available at: https://www.ncbi.nlm.nih.gov/pubmed/17513802.

240. Nehar D, Lombard-Bohas C, Olivieri S, et al. Interest of Chromogranin A for diagnosis and follow-up of endocrine tumours. Clin Endocrinol (Oxf) 2004;60:644–652. Available at: https://www.ncbi.nlm.nih.gov/pubmed/15104570.

241. Ter-Minassian M, Chan JA, Hooshmand SM, et al. Clinical presentation, recurrence, and survival in patients with neuroendocrine tumors: results from a prospective institutional database. Endocr Relat Cancer 2013;20:187–196. Available at: https://www.ncbi.nlm.nih.gov/pubmed/23319495.

242. Yao JC, Pavel M, Phan AT, et al. Chromogranin A and neuron-specific enolase as prognostic markers in patients with advanced pNET treated with everolimus. J Clin Endocrinol Metab 2011;96:3741–3749. Available at: https://www.ncbi.nlm.nih.gov/pubmed/21994954.

243. Jensen RT, Fraker DL. Zollinger-Ellison syndrome. Advances in treatment of gastric hypersecretion and the gastrinoma. JAMA 1994;271:1429–1435. Available at: https://www.ncbi.nlm.nih.gov/pubmed/7513768.

244. Osefo N, Ito T, Jensen RT. Gastric acid hypersecretory states: recent insights and advances. Curr Gastroenterol Rep 2009;11:433–441. Available at: https://www.ncbi.nlm.nih.gov/pubmed/19903418.

Version 3.2025 © 2025 National Comprehensive Cancer Network© (NCCN©), All rights reserved. NCCN Guidelines® and this illustration may not be reproduced in any form without the express written permission of NCCN.

PLEASE NOTE that use of this NCCN Content is governed by the End-User License Agreement, and you MAY NOT distribute this Content or use it with any artificial intelligence model or tool.
Printed by Galya Basol Kochav on 1/7/2026 1:55:52 PM. Copyright © 2026 National Comprehensive Cancer Network, Inc. All Rights Reserved.

245. Cryer PE, Axelrod L, Grossman AB, et al. Evaluation and management of adult hypoglycemic disorders: an Endocrine Society Clinical Practice Guideline. J Clin Endocrinol Metab 2009;94:709–728. Available at: https://www.ncbi.nlm.nih.gov/pubmed/19088155.

246. Doppman JL, Chang R, Fraker DL, et al. Localization of insulinomas to regions of the pancreas by intra-arterial stimulation with calcium. Ann Intern Med 1995;123:269–273. Available at: https://www.ncbi.nlm.nih.gov/pubmed/7611592.

247. Pattison DA, Hicks RJ. Molecular imaging in the investigation of hypoglycaemic syndromes and their management. Endocr Relat Cancer 2017;24:R203–R221. Available at: https://www.ncbi.nlm.nih.gov/pubmed/28400403.

248. Nockel P, Babic B, Millo C, et al. Localization of insulinoma using 68Ga-DOTATATE PET/CT scan. J Clin Endocrinol Metab 2017;102:195–199. Available at: https://www.ncbi.nlm.nih.gov/pubmed/27805844.

249. Tuzcu SA, Pekkolay Z, Kilinc F, Tuzcu AK. ^{68}Ga-DOTATATE PET/CT can be an alternative imaging method in insulinoma patients. J Nucl Med Technol 2017;45:198–200. Available at: https://www.ncbi.nlm.nih.gov/pubmed/28798227.

250. Abdelkawi MM, Romeih MA, Nasr MA, NasrElDin EA. (68)Ga-DOTATATE PET/CT: How is it reliable in imaging of cases having clinical suspicion of insulinomas? Eur J Radiol 2024;179:111669. Available at: https://www.ncbi.nlm.nih.gov/pubmed/39137605.

251. Yu H, Bao X, Gu Y, et al. Comparison of PET/CT using (68)Ga-NOTA-Exendin-4 with (68)Ga-DOTATATE, (18)F-FDG, and conventional imaging in the localization of insulinomas. Eur J Nucl Med Mol Imaging 2025. Available at: https://www.ncbi.nlm.nih.gov/pubmed/40259061.

252. Lee LC, Grant CS, Salomao DR, et al. Small, nonfunctioning, asymptomatic pancreatic neuroendocrine tumors (PNETs): role for nonoperative management. Surgery 2012;152:965–974. Available at: https://www.ncbi.nlm.nih.gov/pubmed/23102679.

253. Strosberg JR, Cheema A, Kvols LK. Stage I nonfunctioning neuroendocrine tumors of the pancreas: Surgery or surveillance? Journal of Clinical Oncology 2011;29:349–349. Available at: http://ascopubs.org/doi/abs/10.1200/jco.2011.29.4_suppl.349.

254. Cherenfant J, Stocker SJ, Gage MK, et al. Predicting aggressive behavior in nonfunctioning pancreatic neuroendocrine tumors. Surgery 2013;154:785–791; discussion 791–783. Available at: https://www.ncbi.nlm.nih.gov/pubmed/24074416.

255. Haynes AB, Deshpande V, Ingkakul T, et al. Implications of incidentally discovered, nonfunctioning pancreatic endocrine tumors: short-term and long-term patient outcomes. Arch Surg 2011;146:534–538. Available at: https://www.ncbi.nlm.nih.gov/pubmed/21576607.

256. Kuo EJ, Salem RR. Population-level analysis of pancreatic neuroendocrine tumors 2 cm or less in size. Ann Surg Oncol 2013;20:2815–2821. Available at: https://www.ncbi.nlm.nih.gov/pubmed/23771245.

257. Regenet N, Carrere N, Boulanger G, et al. Is the 2-cm size cutoff relevant for small nonfunctioning pancreatic neuroendocrine tumors: A French multicenter study. Surgery 2016;159:901–907. Available at: https://www.ncbi.nlm.nih.gov/pubmed/26590096.

258. Sadot E, Reidy-Lagunes DL, Tang LH, et al. Observation versus resection for small asymptomatic pancreatic neuroendocrine tumors: A matched case-control study. Ann Surg Oncol 2016;23:1361–1370. Available at: https://www.ncbi.nlm.nih.gov/pubmed/26597365.

259. Partelli S, Massironi S, Zerbi A, et al. Management of asymptomatic sporadic non-functioning pancreatic neuroendocrine neoplasms no larger than 2 cm: Interim analysis of prospective ASPEN trial. Br J Surg 2022;109:1186–1190. Available at: https://www.ncbi.nlm.nih.gov/pubmed/35986682.

260. Heidsma CM, Engelsman AF, van Dieren S, et al. Watchful waiting for small non-functional pancreatic neuroendocrine tumours: Nationwide

Version 3.2025 © 2025 National Comprehensive Cancer Network© (NCCN©), All rights reserved. NCCN Guidelines® and this illustration may not be reproduced in any form without the express written permission of NCCN.

PLEASE NOTE that use of this NCCN Content is governed by the End-User License Agreement, and you MAY NOT distribute this Content or use it with any artificial intelligence model or tool.
Printed by Galya Basol Kochav on 1/7/2026 1:55:52 PM. Copyright © 2026 National Comprehensive Cancer Network, Inc. All Rights Reserved.

prospective cohort study (PANDORA). Br J Surg 2021;108:888–891. Available at: https://www.ncbi.nlm.nih.gov/pubmed/33783475.

261. Jonasch E, Donskov F, Iliopoulos O, et al. Belzutifan for renal cell carcinoma in von Hippel-Lindau disease. N Engl J Med 2021;385:2036–2046. Available at: https://www.ncbi.nlm.nih.gov/pubmed/34818478.

262. Else T, Jonasch E, Iliopoulos O, et al. Belzutifan for von Hippel-Lindau disease: Pancreatic lesion population of the phase 2 LITESPARK-004 study. Clin Cancer Res 2024;30:1750–1757. Available at: https://www.ncbi.nlm.nih.gov/pubmed/38393723.

263. Stehouwer CD, Lems WF, Fischer HR, et al. Aggravation of hypoglycemia in insulinoma patients by the long-acting somatostatin analogue octreotide (Sandostatin). Acta Endocrinol (Copenh) 1989;121:34–40. Available at: https://www.ncbi.nlm.nih.gov/pubmed/2545062.

264. Matej A, Bujwid H, Wronski J. Glycemic control in patients with insulinoma. Hormones (Athens) 2016;15:489–499. Available at: https://www.ncbi.nlm.nih.gov/pubmed/28222404.

265. Wahba A, Tan Z, Dillon JS. Management of functional neuroendocrine tumors. Curr Probl Cancer 2024;52:101130. Available at: https://www.ncbi.nlm.nih.gov/pubmed/39213785.

266. Brown E, Watkin D, Evans J, et al. Multidisciplinary management of refractory insulinomas. Clin Endocrinol (Oxf) 2018;88:615–624. Available at: https://www.ncbi.nlm.nih.gov/pubmed/29205458.

267. Ferrone CR, Tang LH, Tomlinson J, et al. Determining prognosis in patients with pancreatic endocrine neoplasms: can the WHO classification system be simplified? J Clin Oncol 2007;25:5609–5615. Available at: https://www.ncbi.nlm.nih.gov/pubmed/18065733.

268. Parekh JR, Wang SC, Bergsland EK, et al. Lymph node sampling rates and predictors of nodal metastases in pancreatic neuroendocrine tumor resections: the UCSF experience with 149 patients. Pancreas 2012;41:840–844. Available at: http://www.ncbi.nlm.nih.gov/pubmed/22781907.

269. Tsutsumi K, Ohtsuka T, Mori Y, et al. Analysis of lymph node metastasis in pancreatic neuroendocrine tumors (PNETs) based on the tumor size and hormonal production. J Gastroenterol 2012;47:678–685. Available at: https://www.ncbi.nlm.nih.gov/pubmed/22350698.

270. Eldor R, Glaser B, Fraenkel M, et al. Glucagonoma and the glucagonoma syndrome - cumulative experience with an elusive endocrine tumour. Clin Endocrinol (Oxf) 2011;74:593–598. Available at: https://www.ncbi.nlm.nih.gov/pubmed/21470282.

271. Castro PG, de Leon AM, Trancon JG, et al. Glucagonoma syndrome: a case report. J Med Case Rep 2011;5:402. Available at: https://www.ncbi.nlm.nih.gov/pubmed/21859461.

272. Boninsegna L, Panzuto F, Partelli S, et al. Malignant pancreatic neuroendocrine tumour: lymph node ratio and Ki67 are predictors of recurrence after curative resections. Eur J Cancer 2012;48:1608–1615. Available at: https://www.ncbi.nlm.nih.gov/pubmed/22129889.

273. Casadei R, Ricci C, Pezzilli R, et al. Are there prognostic factors related to recurrence in pancreatic endocrine tumors? Pancreatology 2010;10:33–38. Available at: http://www.ncbi.nlm.nih.gov/pubmed/20299821.

274. Kim SJ, Kim JW, Oh DY, et al. Clinical course of neuroendocrine tumors with different origins (the pancreas, gastrointestinal tract, and lung). Am J Clin Oncol 2011;35:549–556. Available at: http://www.ncbi.nlm.nih.gov/pubmed/21659833.

275. Singh S, Moody L, Chan DL, et al. Follow-up recommendations for completely resected gastroenteropancreatic neuroendocrine tumors. JAMA Oncol 2018;4:1597–1604. Available at: https://www.ncbi.nlm.nih.gov/pubmed/30054622.

276. Strosberg JR, Cheema A, Weber JM, et al. Relapse-free survival in patients with nonmetastatic, surgically resected pancreatic neuroendocrine

Version 3.2025 © 2025 National Comprehensive Cancer Network© (NCCN©), All rights reserved. NCCN Guidelines® and this illustration may not be reproduced in any form without the express written permission of NCCN.

PLEASE NOTE that use of this NCCN Content is governed by the End-User License Agreement, and you MAY NOT distribute this Content or use it with any artificial intelligence model or tool.
Printed by Galya Basol Kochav on 1/7/2026 1:55:52 PM. Copyright © 2026 National Comprehensive Cancer Network, Inc. All Rights Reserved.

tumors: an analysis of the AJCC and ENETS staging classifications. Ann Surg 2012;256:321–325. Available at: https://www.ncbi.nlm.nih.gov/pubmed/22415420.

277. Lesurtel M, Nagorney DM, Mazzaferro V, et al. When should a liver resection be performed in patients with liver metastases from neuroendocrine tumours? A systematic review with practice recommendations. HPB (Oxford) 2015;17:17–22. Available at: https://www.ncbi.nlm.nih.gov/pubmed/24636662.

278. De Jong MC, Farnell MB, Sclabas G, et al. Liver-directed therapy for hepatic metastases in patients undergoing pancreaticoduodenectomy: a dual-center analysis. Ann Surg 2010;252:142–148. Available at: https://www.ncbi.nlm.nih.gov/pubmed/20531007.

279. Mayo SC, de Jong MC, Pulitano C, et al. Surgical management of hepatic neuroendocrine tumor metastasis: results from an international multi-institutional analysis. Ann Surg Oncol 2010;17:3129–3136. Available at: https://www.ncbi.nlm.nih.gov/pubmed/20585879.

280. Saxena A, Chua TC, Perera M, et al. Surgical resection of hepatic metastases from neuroendocrine neoplasms: a systematic review. Surg Oncol 2012;21:e131–141. Available at: https://www.ncbi.nlm.nih.gov/pubmed/22658833.

281. Glazer ES, Tseng JF, Al-Refaie W, et al. Long-term survival after surgical management of neuroendocrine hepatic metastases. HPB (Oxford) 2011;12:427–433. Available at: http://www.ncbi.nlm.nih.gov/pubmed/20662794.

282. Criss CR, Makary MS. Liver-directed locoregional therapies for neuroendocrine liver metastases: Recent advances and management. Curr Oncol 2024;31:2076–2091. Available at: https://www.ncbi.nlm.nih.gov/pubmed/38668057.

283. Hofland J, Refardt JC, Feelders RA, et al. Approach to the patient: Insulinoma. J Clin Endocrinol Metab 2024;109:1109–1118. Available at: https://www.ncbi.nlm.nih.gov/pubmed/37925662.

284. Hofland J, Falconi M, Christ E, et al. European Neuroendocrine Tumor Society 2023 guidance paper for functioning pancreatic neuroendocrine tumour syndromes. J Neuroendocrinol 2023;35:e13318. Available at: https://www.ncbi.nlm.nih.gov/pubmed/37578384.

285. Kulke MH, Bergsland EK, Yao JC. Glycemic control in patients with insulinoma treated with everolimus. N Engl J Med 2009;360:195–197. Available at: https://www.ncbi.nlm.nih.gov/pubmed/19129539.

286. Refardt J, Zandee WT, Brabander T, et al. Inferior outcome of neuroendocrine tumor patients negative on somatostatin receptor imaging. Endocr Relat Cancer 2020;27:615–624. Available at: https://www.ncbi.nlm.nih.gov/pubmed/33032265.

287. Yao JC, Shah MH, Ito T, et al. Everolimus for advanced pancreatic neuroendocrine tumors. N Engl J Med 2011;364:514–523. Available at: https://www.ncbi.nlm.nih.gov/pubmed/21306238.

288. Yao JC, Pavel M, Lombard-Bohas C, et al. Everolimus for the treatment of advanced pancreatic neuroendocrine tumors: Overall survival and circulating biomarkers from the randomized, phase III RADIANT-3 study. J Clin Oncol 2016;34:3906–3913. Available at: https://www.ncbi.nlm.nih.gov/pubmed/27621394.

289. Lombard-Bohas C, Yao JC, Hobday T, et al. Impact of prior chemotherapy use on the efficacy of everolimus in patients with advanced pancreatic neuroendocrine tumors: a subgroup analysis of the phase III RADIANT-3 trial. Pancreas 2015;44:181–189. Available at: https://www.ncbi.nlm.nih.gov/pubmed/25479584.

290. Faivre S, Niccoli P, Castellano D, et al. Sunitinib in pancreatic neuroendocrine tumors: updated progression-free survival and final overall survival from a phase III randomized study. Ann Oncol 2017;28:339–343. Available at: https://www.ncbi.nlm.nih.gov/pubmed/27836885.

291. Valle JW, Borbath I, Rosbrook B, et al. Sunitinib in patients with pancreatic neuroendocrine tumors: update of safety data. Future Oncol 2019;15:1219–1230. Available at: https://www.ncbi.nlm.nih.gov/pubmed/30701988.

Version 3.2025 © 2025 National Comprehensive Cancer Network© (NCCN©), All rights reserved. NCCN Guidelines® and this illustration may not be reproduced in any form without the express written permission of NCCN.

PLEASE NOTE that use of this NCCN Content is governed by the End-User License Agreement, and you MAY NOT distribute this Content or use it with any artificial intelligence model or tool.
Printed by Galya Basol Kochav on 1/7/2026 1:55:52 PM. Copyright © 2026 National Comprehensive Cancer Network, Inc. All Rights Reserved.

292. Richards CJ, Je Y, Schutz FA, et al. Incidence and risk of congestive heart failure in patients with renal and nonrenal cell carcinoma treated with sunitinib. J Clin Oncol 2011;29:3450–3456. Available at: https://www.ncbi.nlm.nih.gov/pubmed/21810682.

293. Schutz FA, Je Y, Richards CJ, Choueiri TK. Meta-analysis of randomized controlled trials for the incidence and risk of treatment-related mortality in patients with cancer treated with vascular endothelial growth factor tyrosine kinase inhibitors. J Clin Oncol 2012;30:871–877. Available at: https://www.ncbi.nlm.nih.gov/pubmed/22312105.

294. Pelle E, Al-Toubah T, Morse B, Strosberg J. Belzutifan in a patient with VHL-associated metastatic pancreatic neuroendocrine tumor. J Natl Compr Canc Netw 2022;20:1285–1287. Available at: https://www.ncbi.nlm.nih.gov/pubmed/36509068.

295. Chan JA, Stuart K, Earle CC, et al. Prospective study of bevacizumab plus temozolomide in patients with advanced neuroendocrine tumors. J Clin Oncol 2012;30:2963–2968. Available at: https://www.ncbi.nlm.nih.gov/pubmed/22778320.

296. Kulke MH, Stuart K, Enzinger PC, et al. Phase II study of temozolomide and thalidomide in patients with metastatic neuroendocrine tumors. J Clin Oncol 2006;24:401–406. Available at: https://www.ncbi.nlm.nih.gov/pubmed/16421420.

297. Kulke MH, Hornick JL, Frauenhoffer C, et al. O6-methylguanine DNA methyltransferase deficiency and response to temozolomide-based therapy in patients with neuroendocrine tumors. Clin Cancer Res 2009;15:338–345. Available at: https://www.ncbi.nlm.nih.gov/pubmed/19118063.

298. Strosberg JR, Fine RL, Choi J, et al. First-line chemotherapy with capecitabine and temozolomide in patients with metastatic pancreatic endocrine carcinomas. Cancer 2011;117:268–275. Available at: https://www.ncbi.nlm.nih.gov/pubmed/20824724.

299. Kunz PL, Graham NT, Catalano PJ, et al. Randomized study of temozolomide or temozolomide and capecitabine in patients with advanced pancreatic neuroendocrine Tumors (ECOG-ACRIN E2211). J Clin Oncol 2023;41:1359–1369. Available at: https://www.ncbi.nlm.nih.gov/pubmed/36260828.

300. Lu Y, Zhao Z, Wang J, et al. Safety and efficacy of combining capecitabine and temozolomide (CAPTEM) to treat advanced neuroendocrine neoplasms: A meta-analysis. Medicine (Baltimore) 2018;97:e12784. Available at: https://www.ncbi.nlm.nih.gov/pubmed/30313101.

301. Chan JA, Blaszkowsky L, Stuart K, et al. A prospective, phase 1/2 study of everolimus and temozolomide in patients with advanced pancreatic neuroendocrine tumor. Cancer 2013;119:3212–3218. Available at: https://www.ncbi.nlm.nih.gov/pubmed/23733618.

302. Faure M, Niccoli P, Autret A, et al. Systemic chemotherapy with FOLFOX in metastatic grade 1/2 neuroendocrine cancer. Mol Clin Oncol 2017;6:44–48. Available at: https://www.ncbi.nlm.nih.gov/pubmed/28123727.

303. Oziel-Taieb S, Zemmour C, Raoul JL, et al. Efficacy of FOLFOX chemotherapy in metastatic enteropancreatic neuroendocrine tumors. Anticancer Res 2021;41:2071–2078. Available at: https://www.ncbi.nlm.nih.gov/pubmed/33813416.

304. Al-Toubah T, Morse B, Pelle E, Strosberg J. Efficacy of FOLFOX in patients with aggressive pancreatic neuroendocrine tumors after prior capecitabine/temozolomide. Oncologist 2021;26:115–119. Available at: https://www.ncbi.nlm.nih.gov/pubmed/33225478.

305. Bajetta E, Catena L, Procopio G, et al. Are capecitabine and oxaliplatin (XELOX) suitable treatments for progressing low-grade and high-grade neuroendocrine tumours? Cancer Chemother Pharmacol 2007;59:637–642. Available at: https://www.ncbi.nlm.nih.gov/pubmed/16937105.

306. Spada F, Antonuzzo L, Marconcini R, et al. Oxaliplatin-based chemotherapy in advanced neuroendocrine tumors: Clinical outcomes and preliminary correlation with biological factors. Neuroendocrinology

Version 3.2025 © 2025 National Comprehensive Cancer Network© (NCCN©), All rights reserved. NCCN Guidelines® and this illustration may not be reproduced in any form without the express written permission of NCCN.

PLEASE NOTE that use of this NCCN Content is governed by the End-User License Agreement, and you MAY NOT distribute this Content or use it with any artificial intelligence model or tool.
Printed by Galya Basol Kochav on 1/7/2026 1:55:52 PM. Copyright © 2026 National Comprehensive Cancer Network, Inc. All Rights Reserved.

2016;103:806–814. Available at: https://www.ncbi.nlm.nih.gov/pubmed/26789262.

307. Zandee WT, Brabander T, Blazevic A, et al. Symptomatic and radiological response to 177Lu-DOTATATE for the treatment of functioning pancreatic neuroendocrine tumors. J Clin Endocrinol Metab 2019;104:1336–1344. Available at: https://www.ncbi.nlm.nih.gov/pubmed/30566620.

308. Baudin E, Walter TA, Beron A, et al. First multicentric randomized phase II trial investigating the antitumor efficacy of peptide receptor radionucleide therapy with 177Lutetium-Octreotate (OCLU) in unresectable progressive neuroendocrine pancreatic tumor: Results of the OCLURANDOM trial [abstract]. Ann Oncol 2022;33:Abstract 8870. Available at: https://oncologypro.esmo.org/meeting-resources/esmo-congress-2022/first-multicentric-randomized-phase-ii-trial-investigating-the-antitumor-efficacy-of-peptide-receptor-radionucleide-therapy-with-sup-177-sup-lute.

309. Johnston FM, Mavros MN, Herman JM, Pawlik TM. Local therapies for hepatic metastases. J Natl Compr Canc Netw 2013;11:153–160. Available at: https://www.ncbi.nlm.nih.gov/pubmed/23411382.

310. Jones NB, Shah MH, Bloomston M. Liver-directed therapies in patients with advanced neuroendocrine tumors. J Natl Compr Canc Netw 2012;10:765–774. Available at: https://www.ncbi.nlm.nih.gov/pubmed/22679118.

311. Kennedy A, Bester L, Salem R, et al. Role of hepatic intra-arterial therapies in metastatic neuroendocrine tumours (NET): guidelines from the NET-Liver-Metastases Consensus Conference. HPB (Oxford) 2015;17:29–37. Available at: https://www.ncbi.nlm.nih.gov/pubmed/25186181.

312. Lewis MA, Hubbard J. Multimodal liver-directed management of neuroendocrine hepatic metastases. Int J Hepatol 2011;2011:452343. Available at: https://www.ncbi.nlm.nih.gov/pubmed/22121491.

313. Du S, Ni J, Weng L, et al. Aggressive locoregional treatment improves the outcome of liver metastases from grade 3 gastroenteropancreatic neuroendocrine tumors. Medicine (Baltimore) 2015;94:e1429. Available at: https://www.ncbi.nlm.nih.gov/pubmed/26313798.

314. Liu DM, Kennedy A, Turner D, et al. Minimally invasive techniques in management of hepatic neuroendocrine metastatic disease. Am J Clin Oncol 2009;32:200–215. Available at: https://www.ncbi.nlm.nih.gov/pubmed/19346815.

315. Mohan H, Nicholson P, Winter DC, et al. Radiofrequency ablation for neuroendocrine liver metastases: a systematic review. J Vasc Interv Radiol 2015;26:935–942.e931. Available at: https://www.ncbi.nlm.nih.gov/pubmed/25840836.

316. Siperstein AE, Rogers SJ, Hansen PD, Gitomirsky A. Laparoscopic thermal ablation of hepatic neuroendocrine tumor metastases. Surgery 1997;122:1147–1154; discussion 1154–1145. Available at: https://www.ncbi.nlm.nih.gov/pubmed/9426432.

317. Taner T, Atwell TD, Zhang L, et al. Adjunctive radiofrequency ablation of metastatic neuroendocrine cancer to the liver complements surgical resection. HPB (Oxford) 2013;15:190–195. Available at: https://www.ncbi.nlm.nih.gov/pubmed/23374359.

318. Bloomston M, Muscarella P, Shah MH, et al. Cytoreduction results in high perioperative mortality and decreased survival in patients undergoing pancreatectomy for neuroendocrine tumors of the pancreas. J Gastrointest Surg 2006;10:1361–1370. Available at: https://www.ncbi.nlm.nih.gov/pubmed/17175455.

319. Gomez D, Malik HZ, Al-Mukthar A, et al. Hepatic resection for metastatic gastrointestinal and pancreatic neuroendocrine tumours: outcome and prognostic predictors. HPB (Oxford) 2007;9:345–351. Available at: https://www.ncbi.nlm.nih.gov/pubmed/18345317.

320. Pederzoli P, Falconi M, Bonora A, et al. Cytoreductive surgery in advanced endocrine tumours of the pancreas. Ital J Gastroenterol Hepatol

Version 3.2025 © 2025 National Comprehensive Cancer Network© (NCCN©), All rights reserved. NCCN Guidelines® and this illustration may not be reproduced in any form without the express written permission of NCCN.

PLEASE NOTE that use of this NCCN Content is governed by the End-User License Agreement, and you MAY NOT distribute this Content or use it with any artificial intelligence model or tool.
Printed by Galya Basol Kochav on 1/7/2026 1:55:52 PM. Copyright © 2026 National Comprehensive Cancer Network, Inc. All Rights Reserved.

1999;31 Suppl 2:S207–212. Available at: https://www.ncbi.nlm.nih.gov/pubmed/10604132.

321. Cloyd JM, Wiseman JT, Pawlik TM. Surgical management of pancreatic neuroendocrine liver metastases. J Gastrointest Oncol 2020;11:590–600. Available at: https://www.ncbi.nlm.nih.gov/pubmed/32655938.

322. Hudson JM, Chung HT, Chu W, et al. Stereotactic ablative radiotherapy for the management of liver metastases from neuroendocrine neoplasms: A preliminary study. Neuroendocrinology 2022;112:153–160. Available at: https://www.ncbi.nlm.nih.gov/pubmed/33530088.

323. Strosberg JR, Weber JM, Choi J, et al. A phase II clinical trial of sunitinib following hepatic transarterial embolization for metastatic neuroendocrine tumors. Ann Oncol 2012;23:2335–2341. Available at: https://www.ncbi.nlm.nih.gov/pubmed/22317769.

324. Gates J, Hartnell GG, Stuart KE, Clouse ME. Chemoembolization of hepatic neoplasms: safety, complications, and when to worry. Radiographics 1999;19:399–414. Available at: https://www.ncbi.nlm.nih.gov/pubmed/10194787.

325. Hur S, Chung JW, Kim HC, et al. Survival outcomes and prognostic factors of transcatheter arterial chemoembolization for hepatic neuroendocrine metastases. J Vasc Interv Radiol 2013;24:947–956; quiz 957. Available at: https://www.ncbi.nlm.nih.gov/pubmed/23602421.

326. Ruszniewski P, Malka D. Hepatic arterial chemoembolization in the management of advanced digestive endocrine tumors. Digestion 2000;62 Suppl 1:79–83. Available at: https://www.ncbi.nlm.nih.gov/pubmed/10940692.

327. Perry LJ, Stuart K, Stokes KR, Clouse ME. Hepatic arterial chemoembolization for metastatic neuroendocrine tumors. Surgery 1994;116:1111–1116; discussion 1116–1117. Available at: https://www.ncbi.nlm.nih.gov/pubmed/7985095.

328. Devcic Z, Rosenberg J, Braat AJ, et al. The efficacy of hepatic 90Y resin radioembolization for metastatic neuroendocrine tumors: a meta-analysis. J Nucl Med 2014;55:1404–1410. Available at: https://www.ncbi.nlm.nih.gov/pubmed/25012459.

329. Kennedy AS, Dezarn WA, McNeillie P, et al. Radioembolization for unresectable neuroendocrine hepatic metastases using resin 90Y-microspheres: early results in 148 patients. Am J Clin Oncol 2008;31:271–279. Available at: http://www.ncbi.nlm.nih.gov/pubmed/18525307.

330. Memon K, Lewandowski RJ, Mulcahy MF, et al. Radioembolization for neuroendocrine liver metastases: safety, imaging, and long-term outcomes. Int J Radiat Oncol Biol Phys 2012;83:887–894. Available at: https://www.ncbi.nlm.nih.gov/pubmed/22137020.

331. Braat A, Kappadath SC, Ahmadzadehfar H, et al. Radioembolization with (90)Y resin microspheres of neuroendocrine liver metastases: International multicenter study on efficacy and toxicity. Cardiovasc Intervent Radiol 2019;42:413–425. Available at: https://www.ncbi.nlm.nih.gov/pubmed/30603975.

332. Schaarschmidt BM, Wildgruber M, Kloeckner R, et al. (90)Y radioembolization in the treatment of neuroendocrine neoplasms: Results of an international multicenter retrospective study. J Nucl Med 2022;63:679–685. Available at: https://www.ncbi.nlm.nih.gov/pubmed/34475236.

333. Kanabar R, Barriuso J, McNamara MG, et al. Liver embolisation for patients with neuroendocrine neoplasms: systematic review. Neuroendocrinology 2021;111:354–369. Available at: https://www.ncbi.nlm.nih.gov/pubmed/32172229.

334. Pericleous M, Caplin ME, Tsochatzis E, et al. Hepatic artery embolization in advanced neuroendocrine tumors: Efficacy and long-term outcomes. Asia Pac J Clin Oncol 2016;12:61–69. Available at: https://www.ncbi.nlm.nih.gov/pubmed/26663886.

Version 3.2025 © 2025 National Comprehensive Cancer Network© (NCCN©), All rights reserved. NCCN Guidelines® and this illustration may not be reproduced in any form without the express written permission of NCCN.

PLEASE NOTE that use of this NCCN Content is governed by the End-User License Agreement, and you MAY NOT distribute this Content or use it with any artificial intelligence model or tool.
Printed by Galya Basol Kochav on 1/7/2026 1:55:52 PM. Copyright © 2026 National Comprehensive Cancer Network, Inc. All Rights Reserved.

335. Kennedy AS. Hepatic-directed therapies in patients with neuroendocrine tumors. Hematol Oncol Clin North Am 2016;30:193–207. Available at: https://www.ncbi.nlm.nih.gov/pubmed/26614377.

336. Devulapalli KK, Fidelman N, Soulen MC, et al. (90)Y radioembolization for hepatic malignancy in patients with previous biliary intervention: Multicenter analysis of hepatobiliary infections. Radiology 2018;288:774–781. Available at: https://www.ncbi.nlm.nih.gov/pubmed/29737954.

337. El-Haddad G, Strosberg J. Radioembolization for metastatic neuroendocrine tumors. Dig Dis Interv 2021;5:103–112. Available at: 10.1055/s-0041-1729755.

338. Chen KS, Lawhn-Heath C, Behr S, et al. Outcomes after high-dose radiation in the management of neuroendocrine neoplasms. PLoS One 2021;16:e0252574. Available at: https://www.ncbi.nlm.nih.gov/pubmed/34077464.

339. Contessa JN, Griffith KA, Wolff E, et al. Radiotherapy for pancreatic neuroendocrine tumors. Int J Radiat Oncol Biol Phys 2009;75:1196–1200. Available at: https://www.ncbi.nlm.nih.gov/pubmed/19327905.

340. Iwata T, Ueno H, Itami J, et al. Efficacy of radiotherapy for primary tumor in patients with unresectable pancreatic neuroendocrine tumors. Jpn J Clin Oncol 2017;47:826–831. Available at: https://www.ncbi.nlm.nih.gov/pubmed/28591817.

341. Lai Q, Coppola A, Mrzljak A, Cigrovski Berkovic M. Liver transplantation for the cure of neuroendocrine liver metastasis: A systematic review with particular attention to the risk factors of death and recurrence. Biomedicines 2024;12. Available at: https://www.ncbi.nlm.nih.gov/pubmed/39594986.

342. Kasai Y, Ito T, Masui T, et al. Liver transplantation for gastroenteropancreatic neuroendocrine liver metastasis: Optimal patient selection and perioperative management in the era of multimodal treatments. J Gastroenterol 2025;60:1–9. Available at: https://www.ncbi.nlm.nih.gov/pubmed/39547997.

343. Gorji L, Brown ZJ, Limkemann A, et al. Liver transplant as a treatment of primary and secondary liver neoplasms. JAMA Surg 2024;159:211–218. Available at: https://www.ncbi.nlm.nih.gov/pubmed/38055245.

344. Citterio D, Coppa J, Sposito C, et al. The role of liver transplantation in the treatment of liver metastases from neuroendocrine tumors. Curr Treat Options Oncol 2023;24:1651–1665. Available at: https://www.ncbi.nlm.nih.gov/pubmed/37882889.

345. Eshmuminov D, Studer DJ, Lopez Lopez V, et al. Controversy over liver transplantation or resection for neuroendocrine liver metastasis: tumor biology cuts the deal. Ann Surg 2023;277:e1063–e1071. Available at: https://www.ncbi.nlm.nih.gov/pubmed/35975918.

346. Sher LS, Levi DM, Wecsler JS, et al. Liver transplantation for metastatic neuroendocrine tumors: Outcomes and prognostic variables. J Surg Oncol 2015;112:125–132. Available at: https://www.ncbi.nlm.nih.gov/pubmed/26171686.

347. Rossi RE, Burroughs AK, Caplin ME. Liver transplantation for unresectable neuroendocrine tumor liver metastases. Ann Surg Oncol 2014;21:2398–2405. Available at: https://www.ncbi.nlm.nih.gov/pubmed/24562931.

348. Klimstra DS, Modlin IR, Coppola D, et al. The pathologic classification of neuroendocrine tumors: a review of nomenclature, grading, and staging systems. Pancreas 2010;39:707–712. Available at: https://www.ncbi.nlm.nih.gov/pubmed/20664470.

349. Bellizzi AM. Assigning site of origin in metastatic neuroendocrine neoplasms: a clinically significant application of diagnostic immunohistochemistry. Adv Anat Pathol 2013;20:285–314. Available at: https://www.ncbi.nlm.nih.gov/pubmed/23939147.

350. Howe JR, Cardona K, Fraker DL, et al. The surgical management of small bowel neuroendocrine tumors: Consensus Guidelines of the North American Neuroendocrine Tumor Society. Pancreas 2017;46:715–731. Available at: https://www.ncbi.nlm.nih.gov/pubmed/28609357.

Version 3.2025 © 2025 National Comprehensive Cancer Network© (NCCN©), All rights reserved. NCCN Guidelines® and this illustration may not be reproduced in any form without the express written permission of NCCN.

PLEASE NOTE that use of this NCCN Content is governed by the End-User License Agreement, and you MAY NOT distribute this Content or use it with any artificial intelligence model or tool.
Printed by Galya Basol Kochav on 1/7/2026 1:55:52 PM. Copyright © 2026 National Comprehensive Cancer Network, Inc. All Rights Reserved.

351. Wang SC, Parekh JR, Zuraek MB, et al. Identification of unknown primary tumors in patients with neuroendocrine liver metastases. Arch Surg 2010;145:276–280. Available at: https://www.ncbi.nlm.nih.gov/pubmed/20231629.

352. Meko JB, Doherty GM, Siegel BA, Norton JA. Evaluation of somatostatin-receptor scintigraphy for detecting neuroendocrine tumors. Surgery 1996;120:975–983; discussion 983–974. Available at: https://www.ncbi.nlm.nih.gov/pubmed/8957483.

353. Inzani F, Petrone G, Rindi G. The new World Health Organization classification for pancreatic neuroendocrine neoplasia. Endocrinol Metab Clin North Am 2018;47:463–470. Available at: https://www.ncbi.nlm.nih.gov/pubmed/30098710.

354. Coriat R, Walter T, Terris B, et al. Gastroenteropancreatic well-differentiated grade 3 neuroendocrine tumors: Review and position statement. Oncologist 2016;21:1191–1199. Available at: https://www.ncbi.nlm.nih.gov/pubmed/27401895.

355. Elvebakken H, Perren A, Scoazec JY, et al. A consensus-developed morphological re-evaluation of 196 high-grade gastroenteropancreatic neuroendocrine neoplasms and its clinical correlations. Neuroendocrinology 2021;111:883–894. Available at: https://www.ncbi.nlm.nih.gov/pubmed/33002892.

356. Velayoudom-Cephise FL, Duvillard P, Foucan L, et al. Are G3 ENETS neuroendocrine neoplasms heterogeneous? Endocr Relat Cancer 2013;20:649–657. Available at: https://www.ncbi.nlm.nih.gov/pubmed/23845449.

357. Heetfeld M, Chougnet CN, Olsen IH, et al. Characteristics and treatment of patients with G3 gastroenteropancreatic neuroendocrine neoplasms. Endocr Relat Cancer 2015;22:657–664. Available at: https://www.ncbi.nlm.nih.gov/pubmed/26113608.

358. Chan DL, Ulaner GA, Pattison D, et al. Dual PET imaging in bronchial neuroendocrine neoplasms: The NETPET score as a prognostic biomarker. J Nucl Med 2021;62:1278–1284. Available at: https://www.ncbi.nlm.nih.gov/pubmed/33579809.

359. Chan DL, Hayes AR, Karfis I, et al. Dual [^{68}Ga]DOTATATE and [^{18}F]FDG PET/CT in patients with metastatic gastroenteropancreatic neuroendocrine neoplasms: A multicentre validation of the NETPET score. Br J Cancer 2023;128:549–555. Available at: https://www.ncbi.nlm.nih.gov/pubmed/36434154.

360. Metser U, Nunez JE, Chan D, et al. Dual somatostatin Receptor/^{18}F-FDG PET/CT Imaging in patients with well-differentiated, grade 2 and 3 gastroenteropancreatic neuroendocrine tumors. J Nucl Med 2024;65:1591–1596. Available at: https://www.ncbi.nlm.nih.gov/pubmed/39266292.

361. Sigel CS, Krauss Silva VW, Reid MD, et al. Well differentiated grade 3 pancreatic neuroendocrine tumors compared with related neoplasms: A morphologic study. Cancer Cytopathol 2018;126:326–335. Available at: https://www.ncbi.nlm.nih.gov/pubmed/29451738.

362. Tang LH, Basturk O, Sue JJ, Klimstra DS. A practical approach to the classification of WHO grade 3 (G3) well-differentiated neuroendocrine tumor (WD-NET) and poorly differentiated neuroendocrine carcinoma (PD-NEC) of the pancreas. Am J Surg Pathol 2016;40:1192–1202. Available at: https://www.ncbi.nlm.nih.gov/pubmed/27259015.

363. Tang LH, Untch BR, Reidy DL, et al. Well-differentiated neuroendocrine tumors with a morphologically apparent high-grade component: A pathway distinct from poorly differentiated neuroendocrine carcinomas. Clin Cancer Res 2016;22:1011–1017. Available at: https://www.ncbi.nlm.nih.gov/pubmed/26482044.

364. Yachida S, Vakiani E, White CM, et al. Small cell and large cell neuroendocrine carcinomas of the pancreas are genetically similar and distinct from well-differentiated pancreatic neuroendocrine tumors. Am J Surg Pathol 2012;36:173–184. Available at: https://www.ncbi.nlm.nih.gov/pubmed/22251937.

Version 3.2025 © 2025 National Comprehensive Cancer Network© (NCCN©), All rights reserved. NCCN Guidelines® and this illustration may not be reproduced in any form without the express written permission of NCCN.

PLEASE NOTE that use of this NCCN Content is governed by the End-User License Agreement, and you MAY NOT distribute this Content or use it with any artificial intelligence model or tool.
Printed by Galya Basol Kochav on 1/7/2026 1:55:52 PM. Copyright © 2026 National Comprehensive Cancer Network, Inc. All Rights Reserved.

365. Konukiewitz B, Schlitter AM, Jesinghaus M, et al. Somatostatin receptor expression related to TP53 and RB1 alterations in pancreatic and extrapancreatic neuroendocrine neoplasms with a Ki67-index above 20. Mod Pathol 2017;30:587–598. Available at: https://www.ncbi.nlm.nih.gov/pubmed/28059098.

366. Merola E, Rinke A, Partelli S, et al. Surgery with radical intent: Is there an indication for G3 neuroendocrine neoplasms? Ann Surg Oncol 2020;27:1348–1355. Available at: https://www.ncbi.nlm.nih.gov/pubmed/31720931.

367. Krug S, Teupe F, Michl P, et al. Brain metastases in patients with neuroendocrine neoplasms: Risk factors and outcome. BMC Cancer 2019;19:362. Available at: https://www.ncbi.nlm.nih.gov/pubmed/30991982.

368. Sahu A, Jefford M, Lai-Kwon J, et al. CAPTEM in metastatic well-differentiated intermediate to high grade neuroendocrine tumors: A single centre experience. J Oncol 2019;2019:9032753. Available at: https://www.ncbi.nlm.nih.gov/pubmed/30915122.

369. Chan DL, Bergsland EK, Chan JA, et al. Temozolomide in grade 3 gastroenteropancreatic neuroendocrine neoplasms: A multicenter retrospective review. Oncologist 2021;26:950–955. Available at: https://www.ncbi.nlm.nih.gov/pubmed/34342086.

370. Marabelle A, Fakih M, Lopez J, et al. Association of tumour mutational burden with outcomes in patients with advanced solid tumours treated with pembrolizumab: prospective biomarker analysis of the multicohort, open-label, phase 2 KEYNOTE-158 study. Lancet Oncol 2020;21:1353–1365. Available at: https://www.ncbi.nlm.nih.gov/pubmed/32919526.

371. Merino DM, McShane LM, Fabrizio D, et al. Establishing guidelines to harmonize tumor mutational burden (TMB): in silico assessment of variation in TMB quantification across diagnostic platforms: phase I of the Friends of Cancer Research TMB Harmonization Project. J Immunother Cancer 2020;8:e000147. Available at: https://www.ncbi.nlm.nih.gov/pubmed/32217756.

372. Carlsen EA, Fazio N, Granberg D, et al. Peptide receptor radionuclide therapy in gastroenteropancreatic NEN G3: A multicenter cohort study. Endocr Relat Cancer 2019;26:227–239. Available at: https://www.ncbi.nlm.nih.gov/pubmed/30540557.

373. Sorbye H, Kong G, Grozinsky-Glasberg S. PRRT in high-grade gastroenteropancreatic neuroendocrine neoplasms (WHO G3). Endocr Relat Cancer 2020;27:R67–R77. Available at: https://www.ncbi.nlm.nih.gov/pubmed/31846429.

374. Raj N, Coffman K, Le T, et al. Treatment response and clinical outcomes of well-differentiated high-grade neuroendocrine tumors to lutetium-177-DOTATATE. Neuroendocrinology 2022;112:1177–1186. Available at: https://www.ncbi.nlm.nih.gov/pubmed/35609558.

375. Hijioka S, Hosoda W, Matsuo K, et al. Rb Loss and KRAS mutation are predictors of the response to platinum-based chemotherapy in pancreatic neuroendocrine neoplasm with grade 3: A Japanese multicenter pancreatic NEN-G3 study. Clin Cancer Res 2017;23:4625–4632. Available at: https://www.ncbi.nlm.nih.gov/pubmed/28455360.

376. Apostolidis L, Dal Buono A, Merola E, et al. Multicenter analysis of treatment outcomes for systemic therapy in well differentiated grade 3 neuroendocrine tumors (NET G3). Cancers (Basel) 2021;13. Available at: https://www.ncbi.nlm.nih.gov/pubmed/33923759.

377. Borghesani M, Reni A, Lauricella E, et al. Efficacy and toxicity analysis of mFOLFIRINOX in high-grade gastroenteropancreatic neuroendocrine neoplasms. J Natl Compr Canc Netw 2024;22. Available at: https://www.ncbi.nlm.nih.gov/pubmed/38744314.

378. Chan DL, Thompson R, Lam M, et al. External beam radiotherapy in the treatment of gastroenteropancreatic neuroendocrine tumours: A systematic review. Clin Oncol (R Coll Radiol) 2018;30:400–408. Available at: https://www.ncbi.nlm.nih.gov/pubmed/29615284.

379. Hentic O, Hammel P, Couvelard A, et al. FOLFIRI regimen: an effective second-line chemotherapy after failure of etoposide-platinum combination in patients with neuroendocrine carcinomas grade 3. Endocr

Version 3.2025 © 2025 National Comprehensive Cancer Network© (NCCN©), All rights reserved. NCCN Guidelines® and this illustration may not be reproduced in any form without the express written permission of NCCN.

PLEASE NOTE that use of this NCCN Content is governed by the End-User License Agreement, and you MAY NOT distribute this Content or use it with any artificial intelligence model or tool.
Printed by Galya Basol Kochav on 1/7/2026 1:55:52 PM. Copyright © 2026 National Comprehensive Cancer Network, Inc. All Rights Reserved.

Relat Cancer 2012;19:751–757. Available at: https://www.ncbi.nlm.nih.gov/pubmed/22940375.

380. Morizane C, Machida N, Honma Y, et al. Effectiveness of etoposide and cisplatin vs irinotecan and cisplatin therapy for patients with advanced neuroendocrine carcinoma of the digestive system: The TOPIC-NEC phase 3 randomized clinical trial. JAMA Oncol 2022;8:1447–1455. Available at: https://www.ncbi.nlm.nih.gov/pubmed/35980649.

381. Zhu J, Strosberg JR, Dropkin E, Strickler JH. Treatment of high-grade metastatic pancreatic neuroendocrine carcinoma with FOLFIRINOX. J Gastrointest Cancer 2015;46:166–169. Available at: https://www.ncbi.nlm.nih.gov/pubmed/25662891.

382. Butt BP, Stokmo HL, Ladekarl M, et al. Folfirinox in the treatment of advanced gastroenteropancreatic neuroendocrine carsinomas [abstract]. Ann Oncol 2021;32:Abstract 1108P. Available at: https://www.annalsofoncology.org/article/S0923-7534(21)02404-2/pdf.

383. Al-Toubah T, Halfdanarson T, Gile J, et al. Efficacy of ipilimumab and nivolumab in patients with high-grade neuroendocrine neoplasms. ESMO Open 2022;7:100364. Available at: https://www.ncbi.nlm.nih.gov/pubmed/34973511.

384. Klein O, Kee D, Markman B, et al. Immunotherapy of ipilimumab and nivolumab in patients with advanced neuroendocrine tumors: A subgroup analysis of the CA209-538 clinical trial for rare cancers. Clin Cancer Res 2020;26:4454–4459. Available at: https://www.ncbi.nlm.nih.gov/pubmed/32532787.

385. Patel SP, Othus M, Chae YK, et al. A phase II basket trial of dual anti-CTLA-4 and anti-PD-1 blockade in rare tumors (DART SWOG 1609) in patients with nonpancreatic neuroendocrine tumors. Clin Cancer Res 2020;26:2290–2296. Available at: https://www.ncbi.nlm.nih.gov/pubmed/31969335.

386. Patel SP, Mayerson E, Chae YK, et al. A phase II basket trial of dual anti-CTLA-4 and anti-PD-1 blockade in rare tumors (DART) SWOG S1609: High-grade neuroendocrine neoplasm cohort. Cancer 2021;127:3194–3201. Available at: https://www.ncbi.nlm.nih.gov/pubmed/33882143.

387. Dasari A, Mehta K, Byers LA, et al. Comparative study of lung and extrapulmonary poorly differentiated neuroendocrine carcinomas: A SEER database analysis of 162,983 cases. Cancer 2018;124:807–815. Available at: https://www.ncbi.nlm.nih.gov/pubmed/29211313.

388. Zhu J, Wang Y, Sun H, et al. Surgery versus radiotherapy for limited-stage small cell esophageal carcinoma: A multicenter, retrospective, cohort study in China (ChiSCEC). Int J Surg 2024;110:956–964. Available at: https://www.ncbi.nlm.nih.gov/pubmed/37995095.

389. Atsumi K, Shioyama Y, Nomoto S, et al. Chemoradiation for small cell esophageal carcinoma: Report of 11 cases from multi-institution experience. J Radiat Res 2010;51:15–20. Available at: https://www.ncbi.nlm.nih.gov/pubmed/19755801.

390. Verma V, Sleightholm RL, Fang P, et al. National Cancer Database report of nonmetastatic esophageal small cell carcinoma. Cancer Med 2018;7:6365–6373. Available at: https://www.ncbi.nlm.nih.gov/pubmed/30403012.

391. Ueberroth BE, Liu AJ, Starr JS, et al. Neuroendocrine carcinoma of the anus and rectum: Patient characteristics and treatment options. Clin Colorectal Cancer 2021;20:e139–e149. Available at: https://www.ncbi.nlm.nih.gov/pubmed/33551318.

392. Brieau B, Lepere C, Walter T, et al. Radiochemotherapy versus surgery in nonmetastatic anorectal neuroendocrine carcinoma: A multicenter study by the Association des Gastro-Enterologues Oncologues. Medicine (Baltimore) 2015;94:e1864. Available at: https://www.ncbi.nlm.nih.gov/pubmed/26496341.

393. Frizziero M, Spada F, Lamarca A, et al. Carboplatin in combination with oral or intravenous etoposide for extra-pulmonary, poorly-differentiated neuroendocrine carcinomas. Neuroendocrinology 2019;109:100–112. Available at: https://www.ncbi.nlm.nih.gov/pubmed/30703770.

Version 3.2025 © 2025 National Comprehensive Cancer Network© (NCCN©), All rights reserved. NCCN Guidelines® and this illustration may not be reproduced in any form without the express written permission of NCCN.

PLEASE NOTE that use of this NCCN Content is governed by the End-User License Agreement, and you MAY NOT distribute this Content or use it with any artificial intelligence model or tool.
Printed by Galya Basol Kochav on 1/7/2026 1:55:52 PM. Copyright © 2026 National Comprehensive Cancer Network, Inc. All Rights Reserved.

394. Zhang P, Li J, Li J, et al. Etoposide and cisplatin versus irinotecan and cisplatin as the first-line therapy for patients with advanced, poorly differentiated gastroenteropancreatic neuroendocrine carcinoma: A randomized phase 2 study. Cancer 2020;126 Suppl 9:2086–2092. Available at: https://www.ncbi.nlm.nih.gov/pubmed/32293725.

395. Hadoux J, Malka D, Planchard D, et al. Post-first-line FOLFOX chemotherapy for grade 3 neuroendocrine carcinoma. Endocr Relat Cancer 2015;22:289–298. Available at: https://www.ncbi.nlm.nih.gov/pubmed/25770151.

396. Kobayashi N, Takeda Y, Okubo N, et al. Phase II study of temozolomide monotherapy in patients with extrapulmonary neuroendocrine carcinoma. Cancer Sci 2021;112:1936–1942. Available at: https://www.ncbi.nlm.nih.gov/pubmed/33453146.

397. Rogowski W, Wachula E, Gorzelak A, et al. Capecitabine and temozolomide combination for treatment of high-grade, well-differentiated neuroendocrine tumour and poorly-differentiated neuroendocrine carcinoma - retrospective analysis. Endokrynol Pol 2019;70:313–317. Available at: https://www.ncbi.nlm.nih.gov/pubmed/30843182.

398. Riesco-Martinez MC, Capdevila J, Alonso V, et al. Nivolumab plus platinum-doublet chemotherapy in treatment-naive patients with advanced grade 3 neuroendocrine neoplasms of gastroenteropancreatic or unknown origin: The multicenter phase 2 NICE-NEC trial (GETNE-T1913). Nat Commun 2024;15:6753. Available at: https://www.ncbi.nlm.nih.gov/pubmed/39117670.

399. McGarrah PW, Leventakos K, Hobday TJ, et al. Efficacy of second-line chemotherapy in extrapulmonary neuroendocrine carcinoma. Pancreas 2020;49:529–533. Available at: https://www.ncbi.nlm.nih.gov/pubmed/32282766.

400. Sherman S, Rotem O, Shochat T, et al. Efficacy of immune check-point inhibitors (ICPi) in large cell neuroendocrine tumors of lung (LCNEC). Lung Cancer 2020;143:40–46. Available at: https://www.ncbi.nlm.nih.gov/pubmed/32203769.

401. Capdevila J, Hernando J, Teule A, et al. Durvalumab plus tremelimumab for the treatment of advanced neuroendocrine neoplasms of gastroenteropancreatic and lung origin. Nat Commun 2023;14:2973. Available at: https://www.ncbi.nlm.nih.gov/pubmed/37221181.

402. Marabelle A, Le DT, Ascierto PA, et al. Efficacy of pembrolizumab in patients with noncolorectal high microsatellite instability/mismatch repair-deficient cancer: Results from the phase II KEYNOTE-158 study. J Clin Oncol 2020;38:1–10. Available at: https://www.ncbi.nlm.nih.gov/pubmed/31682550.

403. Salama AKS, Li S, Macrae ER, et al. Dabrafenib and trametinib in patients with tumors with *BRAF*^{V600E} mutations: Results of the NCI-MATCH trial Subprotocol H. J Clin Oncol 2020;38:3895–3904. Available at: https://www.ncbi.nlm.nih.gov/pubmed/32758030.

404. Sigal DS, Bhangoo MS, Hermel JA, et al. Comprehensive genomic profiling identifies novel NTRK fusions in neuroendocrine tumors. Oncotarget 2018;9:35809–35812. Available at: https://www.ncbi.nlm.nih.gov/pubmed/30533196.

405. Doebele RC, Drilon A, Paz-Ares L, et al. Entrectinib in patients with advanced or metastatic NTRK fusion-positive solid tumours: Integrated analysis of three phase 1-2 trials. Lancet Oncol 2020;21:271–282. Available at: https://www.ncbi.nlm.nih.gov/pubmed/31838007.

406. Drilon A, Laetsch TW, Kummar S, et al. Efficacy of larotrectinib in TRK fusion-positive cancers in adults and children. N Engl J Med 2018;378:731–739. Available at: https://www.ncbi.nlm.nih.gov/pubmed/29466156.

407. Solomon BJ, Drilon A, Lin JJ, et al. Repotrectinib in patients (pts) with NTRK fusion-positive (NTRK+) advanced solid tumors, including NSCLC: Update from the phase I/II TRIDENT-1 trial [abstract]. Ann Oncol 2023;34:Abstract 1372P. Available at: https://www.annalsofoncology.org/article/S0923-7534(23)03242-8/fulltext.

408. Subbiah V, Wolf J, Konda B, et al. Tumour-agnostic efficacy and safety of selpercatinib in patients with RET fusion-positive solid tumours

Version 3.2025 © 2025 National Comprehensive Cancer Network© (NCCN©), All rights reserved. NCCN Guidelines® and this illustration may not be reproduced in any form without the express written permission of NCCN.

PLEASE NOTE that use of this NCCN Content is governed by the End-User License Agreement, and you MAY NOT distribute this Content or use it with any artificial intelligence model or tool.
Printed by Galya Basol Kochav on 1/7/2026 1:55:52 PM. Copyright © 2026 National Comprehensive Cancer Network, Inc. All Rights Reserved.

other than lung or thyroid tumours (LIBRETTO-001): A phase 1/2, open-label, basket trial. Lancet Oncol 2022;23:1261–1273. Available at: https://www.ncbi.nlm.nih.gov/pubmed/36108661.

409. Funder JW, Carey RM, Mantero F, et al. The management of primary aldosteronism: Case detection, diagnosis, and treatment: An Endocrine Society Clinical Practice Guideline. J Clin Endocrinol Metab 2016;101:1889–1916. Available at: https://www.ncbi.nlm.nih.gov/pubmed/26934393.

410. Fleseriu M, Auchus R, Bancos I, et al. Consensus on diagnosis and management of Cushing's disease: a guideline update. Lancet Diabetes Endocrinol 2021;9:847–875. Available at: https://www.ncbi.nlm.nih.gov/pubmed/34687601.

411. Fassnacht M, Arlt W, Bancos I, et al. Management of adrenal incidentalomas: European Society of Endocrinology Clinical Practice Guideline in collaboration with the European Network for the Study of Adrenal Tumors. Eur J Endocrinol 2016;175:G1–G34. Available at: https://www.ncbi.nlm.nih.gov/pubmed/27390021.

412. Fassnacht M, Tsagarakis S, Terzolo M, et al. European Society of Endocrinology clinical practice guidelines on the management of adrenal incidentalomas, in collaboration with the European Network for the Study of Adrenal Tumors. Eur J Endocrinol 2023;189:G1–G42. Available at: https://www.ncbi.nlm.nih.gov/pubmed/37318239.

413. Young WF, Jr. Diagnosis and treatment of primary aldosteronism: practical clinical perspectives. J Intern Med 2019;285:126–148. Available at: https://www.ncbi.nlm.nih.gov/pubmed/30255616.

414. Williams TA, Reincke M. MANAGEMENT OF ENDOCRINE DISEASE: Diagnosis and management of primary aldosteronism: the Endocrine Society guideline 2016 revisited. Eur J Endocrinol 2018;179:R19–R29. Available at: https://www.ncbi.nlm.nih.gov/pubmed/29674485.

415. Vaidya A, Carey RM. Evolution of the primary aldosteronism syndrome: Updating the approach. J Clin Endocrinol Metab 2020;105:3771–3783. Available at: https://www.ncbi.nlm.nih.gov/pubmed/32865201.

416. Yip L, Duh QY, Wachtel H, et al. American Association of Endocrine Surgeons Guidelines for adrenalectomy: Executive summary. JAMA Surg 2022;157:870–877. Available at: https://www.ncbi.nlm.nih.gov/pubmed/35976622.

417. Guignat L, Bertherat J. The diagnosis of Cushing's syndrome: an Endocrine Society Clinical Practice Guideline: commentary from a European perspective. Eur J Endocrinol 2010;163:9–13. Available at: https://www.ncbi.nlm.nih.gov/pubmed/20375177.

418. Ng CS, Altinmakas E, Wei W, et al. Combining washout and noncontrast data from adrenal protocol CT: Improving diagnostic performance. Acad Radiol 2018;25:861–868. Available at: https://www.ncbi.nlm.nih.gov/pubmed/29398440.

419. Caoili EM, Korobkin M, Francis IR, et al. Adrenal masses: characterization with combined unenhanced and delayed enhanced CT. Radiology 2002;222:629–633. Available at: https://www.ncbi.nlm.nih.gov/pubmed/11867777.

420. Szolar DH, Korobkin M, Reittner P, et al. Adrenocortical carcinomas and adrenal pheochromocytomas: mass and enhancement loss evaluation at delayed contrast-enhanced CT. Radiology 2005;234:479–485. Available at: https://www.ncbi.nlm.nih.gov/pubmed/15671003.

421. Raymond VM, Else T, Everett JN, et al. Prevalence of germline TP53 mutations in a prospective series of unselected patients with adrenocortical carcinoma. J Clin Endocrinol Metab 2013;98:E119–125. Available at: https://www.ncbi.nlm.nih.gov/pubmed/23175693.

422. Gaujoux S, Mihai R, joint working group of E, Ensat. European Society of Endocrine Surgeons (ESES) and European Network for the Study of Adrenal Tumours (ENSAT) recommendations for the surgical management of adrenocortical carcinoma. Br J Surg 2017;104:358–376. Available at: https://www.ncbi.nlm.nih.gov/pubmed/28199015.

Version 3.2025 © 2025 National Comprehensive Cancer Network© (NCCN©), All rights reserved. NCCN Guidelines® and this illustration may not be reproduced in any form without the express written permission of NCCN.

PLEASE NOTE that use of this NCCN Content is governed by the End-User License Agreement, and you MAY NOT distribute this Content or use it with any artificial intelligence model or tool.
Printed by Galya Basol Kochav on 1/7/2026 1:55:52 PM. Copyright © 2026 National Comprehensive Cancer Network, Inc. All Rights Reserved.

423. Autorino R, Bove P, De Sio M, et al. Open versus laparoscopic adrenalectomy for adrenocortical carcinoma: A meta-analysis of surgical and oncological outcomes. Ann Surg Oncol 2016;23:1195–1202. Available at: https://www.ncbi.nlm.nih.gov/pubmed/26480850.

424. Tang Y, Liu Z, Zou Z, et al. Benefits of adjuvant mitotane after resection of adrenocortical carcinoma: A systematic review and meta-analysis. Biomed Res Int 2018;2018:9362108. Available at: https://www.ncbi.nlm.nih.gov/pubmed/29967789.

425. Terzolo M, Fassnacht M, Perotti P, et al. Adjuvant mitotane versus surveillance in low-grade, localised adrenocortical carcinoma (ADIUVO): An international, multicentre, open-label, randomised, phase 3 trial and observational study. Lancet Diabetes Endocrinol 2023;11:720–730. Available at: https://www.ncbi.nlm.nih.gov/pubmed/37619579.

426. Barzon L, Fallo F, Sonino N, et al. Adrenocortical carcinoma: experience in 45 patients. Oncology 1997;54:490–496. Available at: https://www.ncbi.nlm.nih.gov/pubmed/9394846.

427. Baudin E, Pellegriti G, Bonnay M, et al. Impact of monitoring plasma 1,1-dichlorodiphenildichloroethane (o,p'DDD) levels on the treatment of patients with adrenocortical carcinoma. Cancer 2001;92:1385–1392. Available at: https://www.ncbi.nlm.nih.gov/pubmed/11745214.

428. Haak HR, Hermans J, van de Velde CJ, et al. Optimal treatment of adrenocortical carcinoma with mitotane: results in a consecutive series of 96 patients. Br J Cancer 1994;69:947–951. Available at: https://www.ncbi.nlm.nih.gov/pubmed/8180029.

429. Veytsman I, Nieman L, Fojo T. Management of endocrine manifestations and the use of mitotane as a chemotherapeutic agent for adrenocortical carcinoma. J Clin Oncol 2009;27:4619–4629. Available at: https://www.ncbi.nlm.nih.gov/pubmed/19667279.

430. Berruti A, Terzolo M, Sperone P, et al. Etoposide, doxorubicin and cisplatin plus mitotane in the treatment of advanced adrenocortical carcinoma: a large prospective phase II trial. Endocr Relat Cancer 2005;12:657–666. Available at: https://www.ncbi.nlm.nih.gov/pubmed/16172198.

431. Uchihara M, Tanioka M, Kojima Y, et al. Clinical management and outcomes associated with etoposide, doxorubicin, and cisplatin plus mitotane treatment in metastatic adrenocortical carcinoma: A single institute experience. Int J Clin Oncol 2021;26:2275–2281. Available at: https://www.ncbi.nlm.nih.gov/pubmed/34468885.

432. Fassnacht M, Terzolo M, Allolio B, et al. Combination chemotherapy in advanced adrenocortical carcinoma. N Engl J Med 2012;366:2189–2197. Available at: https://www.ncbi.nlm.nih.gov/pubmed/22551107.

433. Campbell MT, Balderrama-Brondani V, Jimenez C, et al. Cabozantinib monotherapy for advanced adrenocortical carcinoma: A single-arm, phase 2 trial. Lancet Oncol 2024;25:649–657. Available at: https://www.ncbi.nlm.nih.gov/pubmed/38608694.

434. Raj N, Zheng Y, Kelly V, et al. PD-1 blockade in advanced adrenocortical carcinoma. J Clin Oncol 2020;38:71–80. Available at: https://www.ncbi.nlm.nih.gov/pubmed/31644329.

435. Habra MA, Stephen B, Campbell M, et al. Phase II clinical trial of pembrolizumab efficacy and safety in advanced adrenocortical carcinoma. J Immunother Cancer 2019;7:253. Available at: https://www.ncbi.nlm.nih.gov/pubmed/31533818.

436. Naing A, Meric-Bernstam F, Stephen B, et al. Phase 2 study of pembrolizumab in patients with advanced rare cancers. J Immunother Cancer 2020;8:e000347. Available at: https://www.ncbi.nlm.nih.gov/pubmed/32188704.

437. Patel SP, Othus M, Chae YK, et al. Phase II basket trial of dual anti-CTLA-4 and anti-PD-1 blockade in rare tumors (DART) SWOG S1609: Adrenocortical carcinoma cohort. J Immunother Cancer 2024;12. Available at: https://www.ncbi.nlm.nih.gov/pubmed/39067873.

438. Fleseriu M, Biller BMK. Treatment of Cushing's syndrome with osilodrostat: Practical applications of recent studies with case examples.

Version 3.2025 © 2025 National Comprehensive Cancer Network© (NCCN©), All rights reserved. NCCN Guidelines® and this illustration may not be reproduced in any form without the express written permission of NCCN.

PLEASE NOTE that use of this NCCN Content is governed by the End-User License Agreement, and you MAY NOT distribute this Content or use it with any artificial intelligence model or tool.
Printed by Galya Basol Kochav on 1/7/2026 1:55:52 PM. Copyright © 2026 National Comprehensive Cancer Network, Inc. All Rights Reserved.

Pituitary 2022;25:795–809. Available at: https://www.ncbi.nlm.nih.gov/pubmed/36002784.

439. Pivonello R, Simeoli C, Di Paola N, et al. Osilodrostat: A novel potent inhibitor of 11-beta-hydroxylase for the treatment of Cushing's syndrome. touchREV Endocrinol 2024;20:43–51. Available at: https://www.ncbi.nlm.nih.gov/pubmed/38812665.

440. Turkova H, Prodanov T, Maly M, et al. Characteristics and outcomes of metastatic Sdhb and sporadic pheochromocytoma/paraganglioma: An National Institutes of Health study. Endocr Pract 2016;22:302–314. Available at: https://www.ncbi.nlm.nih.gov/pubmed/26523625.

441. King KS, Prodanov T, Kantorovich V, et al. Metastatic pheochromocytoma/paraganglioma related to primary tumor development in childhood or adolescence: significant link to SDHB mutations. J Clin Oncol 2011;29:4137–4142. Available at: https://www.ncbi.nlm.nih.gov/pubmed/21969497.

442. Hamidi O, Young WF, Jr., Gruber L, et al. Outcomes of patients with metastatic phaeochromocytoma and paraganglioma: A systematic review and meta-analysis. Clin Endocrinol (Oxf) 2017;87:440–450. Available at: https://www.ncbi.nlm.nih.gov/pubmed/28746746.

443. Nicolas M, Dahia P. Predictors of outcome in phaeochromocytomas and paragangliomas. F1000Res 2017;6:2160. Available at: https://www.ncbi.nlm.nih.gov/pubmed/29333259.

444. Hamidi O, Young WF, Jr., Iniguez-Ariza NM, et al. Malignant pheochromocytoma and paraganglioma: 272 patients over 55 years. J Clin Endocrinol Metab 2017;102:3296–3305. Available at: https://www.ncbi.nlm.nih.gov/pubmed/28605453.

445. Neary NM, King KS, Pacak K. Drugs and pheochromocytoma--don't be fooled by every elevated metanephrine. N Engl J Med 2011;364:2268–2270. Available at: http://www.ncbi.nlm.nih.gov/pubmed/21651412.

446. Pacak K. Phaeochromocytoma: a catecholamine and oxidative stress disorder. Endocr Regul 2011;45:65–90. Available at: https://www.ncbi.nlm.nih.gov/pubmed/21615192.

447. Timmers HJ, Chen CC, Carrasquillo JA, et al. Staging and functional characterization of pheochromocytoma and paraganglioma by 18F-fluorodeoxyglucose (18F-FDG) positron emission tomography. J Natl Cancer Inst 2012;104:700–708. Available at: https://www.ncbi.nlm.nih.gov/pubmed/22517990.

448. Fishbein L, Merrill S, Fraker DL, et al. Inherited mutations in pheochromocytoma and paraganglioma: why all patients should be offered genetic testing. Ann Surg Oncol 2013;20:1444–1450. Available at: https://www.ncbi.nlm.nih.gov/pubmed/23512077.

449. Pacak K, Jochmanova I, Prodanov T, et al. New syndrome of paraganglioma and somatostatinoma associated with polycythemia. J Clin Oncol 2013;31:1690–1698. Available at: https://www.ncbi.nlm.nih.gov/pubmed/23509317.

450. Zhuang Z, Yang C, Lorenzo F, et al. Somatic HIF2A gain-of-function mutations in paraganglioma with polycythemia. N Engl J Med 2012;367:922–930. Available at: https://www.ncbi.nlm.nih.gov/pubmed/22931260.

451. Burnichon N, Cascon A, Schiavi F, et al. MAX mutations cause hereditary and sporadic pheochromocytoma and paraganglioma. Clin Cancer Res 2012;18:2828–2837. Available at: https://www.ncbi.nlm.nih.gov/pubmed/22452945.

452. Cascon A, Comino-Mendez I, Curras-Freixes M, et al. Whole-exome sequencing identifies MDH2 as a new familial paraganglioma gene. J Natl Cancer Inst 2015;107:djv053. Available at: https://www.ncbi.nlm.nih.gov/pubmed/25766404.

453. van Hulsteijn LT, Dekkers OM, Hes FJ, et al. Risk of malignant paraganglioma in SDHB-mutation and SDHD-mutation carriers: a systematic review and meta-analysis. J Med Genet 2012;49:768–776. Available at: https://www.ncbi.nlm.nih.gov/pubmed/23099648.

Version 3.2025 © 2025 National Comprehensive Cancer Network© (NCCN©), All rights reserved. NCCN Guidelines® and this illustration may not be reproduced in any form without the express written permission of NCCN.

PLEASE NOTE that use of this NCCN Content is governed by the End-User License Agreement, and you MAY NOT distribute this Content or use it with any artificial intelligence model or tool.
Printed by Galya Basol Kochav on 1/7/2026 1:55:52 PM. Copyright © 2026 National Comprehensive Cancer Network, Inc. All Rights Reserved.

454. Else T, S. G, Fishbein L. Hereditary Paraganglioma-Pheochromocytoma Syndromes. 2008 May 21 [Updated 2023 Sep 21]. In: Adam MP, Feldman J, Mirzaa GM, et al., editors. GeneReviews® [Internet]. Seattle (WA): University of Washington, Seattle; 1993-2025. Available at: http://www.ncbi.nlm.nih.gov/books/NBK1548/. Accessed July 23, 2025.

455. Amar L, Pacak K, Steichen O, et al. International consensus on initial screening and follow-up of asymptomatic SDHx mutation carriers. Nat Rev Endocrinol 2021;17:435–444. Available at: https://www.ncbi.nlm.nih.gov/pubmed/34021277.

456. Conzo G, Musella M, Corcione F, et al. Laparoscopic adrenalectomy, a safe procedure for pheochromocytoma. A retrospective review of clinical series. Int J Surg 2013;11:152–156. Available at: https://www.ncbi.nlm.nih.gov/pubmed/23267853.

457. Grant CS. Pheochromocytoma. In: Clark OH, Duh QY, eds. Textbook of Endocrine Surgery. Philadelphia, PA: WB Saunders 1997.

458. Wang W, Li P, Wang Y, et al. Effectiveness and safety of laparoscopic adrenalectomy of large pheochromocytoma: a prospective, nonrandomized, controlled study. Am J Surg 2015;210:230–235. Available at: https://www.ncbi.nlm.nih.gov/pubmed/25952614.

459. Fishbein L, Del Rivero J, Else T, et al. The North American Neuroendocrine Tumor Society Consensus Guidelines for surveillance and management of metastatic and/or unresectable pheochromocytoma and paraganglioma. Pancreas 2021;50:469–493. Available at: https://www.ncbi.nlm.nih.gov/pubmed/33939658.

460. FDA approves belzutifan for pheochromocytoma or paraganglioma. Available at: https://www.fda.gov/drugs/resources-information-approved-drugs/fda-approves-belzutifan-pheochromocytoma-or-paraganglioma. Accessed July 24, 2025.

461. Jimenez C, Habra MA, Campbell MT, et al. Cabozantinib in patients with unresectable and progressive metastatic phaeochromocytoma or paraganglioma (the Natalie Trial): A single-arm, phase 2 trial. Lancet Oncol 2024;25:658–667. Available at: https://www.ncbi.nlm.nih.gov/pubmed/38608693.

462. Krempf M, Lumbroso J, Mornex R, et al. Use of m-[131I]iodobenzylguanidine in the treatment of malignant pheochromocytoma. J Clin Endocrinol Metab 1991;72:455–461. Available at: http://www.ncbi.nlm.nih.gov/pubmed/1991814.

463. Rose B, Matthay KK, Price D, et al. High-dose 131I-metaiodobenzylguanidine therapy for 12 patients with malignant pheochromocytoma. Cancer 2003;98:239–248. Available at: https://www.ncbi.nlm.nih.gov/pubmed/12872341.

464. Pryma DA, Chin BB, Noto RB, et al. Efficacy and safety of high-specific-activity (131)I-MIBG therapy in patients with advanced pheochromocytoma or paraganglioma. J Nucl Med 2019;60:623–630. Available at: https://www.ncbi.nlm.nih.gov/pubmed/30291194.

465. Deschler-Baier B, Konda B, Massarelli E, et al. Clinical activity of selpercatinib in *RET*-mutant pheochromocytoma. J Clin Endocrinol Metab 2025;110:e600–e606. Available at: https://www.ncbi.nlm.nih.gov/pubmed/38661071.

466. Baudin E, Goichot B, Berruti A, et al. Sunitinib for metastatic progressive phaeochromocytomas and paragangliomas: Results from FIRSTMAPPP, an academic, multicentre, international, randomised, placebo-controlled, double-blind, phase 2 trial. Lancet 2024;403:1061–1070. Available at: https://www.ncbi.nlm.nih.gov/pubmed/38402886.

467. Averbuch SD, Steakley CS, Young RC, et al. Malignant pheochromocytoma: effective treatment with a combination of cyclophosphamide, vincristine, and dacarbazine. Ann Intern Med 1988;109:267–273. Available at: https://www.ncbi.nlm.nih.gov/pubmed/3395037.

468. Ayala-Ramirez M, Feng L, Habra MA, et al. Clinical benefits of systemic chemotherapy for patients with metastatic pheochromocytomas or sympathetic extra-adrenal paragangliomas: insights from the largest

Version 3.2025 © 2025 National Comprehensive Cancer Network© (NCCN©), All rights reserved. NCCN Guidelines® and this illustration may not be reproduced in any form without the express written permission of NCCN.

PLEASE NOTE that use of this NCCN Content is governed by the End-User License Agreement, and you MAY NOT distribute this Content or use it with any artificial intelligence model or tool.
Printed by Galya Basol Kochav on 1/7/2026 1:55:52 PM. Copyright © 2026 National Comprehensive Cancer Network, Inc. All Rights Reserved.

single-institutional experience. Cancer 2012;118:2804–2812. Available at: https://www.ncbi.nlm.nih.gov/pubmed/22006217.

469. Hadoux J, Favier J, Scoazec JY, et al. SDHB mutations are associated with response to temozolomide in patients with metastatic pheochromocytoma or paraganglioma. Int J Cancer 2014;135:2711–2720. Available at: https://www.ncbi.nlm.nih.gov/pubmed/24752622.

470. Tanabe A, Naruse M, Nomura K, et al. Combination chemotherapy with cyclophosphamide, vincristine, and dacarbazine in patients with malignant pheochromocytoma and paraganglioma. Horm Cancer 2013;4:103–110. Available at: https://www.ncbi.nlm.nih.gov/pubmed/23361939.

471. Jaiswal SK, Sarathi V, Memon SS, et al. 177Lu-DOTATATE therapy in metastatic/inoperable pheochromocytoma-paraganglioma. Endocr Connect 2020;9:864–873. Available at: https://www.ncbi.nlm.nih.gov/pubmed/32784267.

472. Vyakaranam AR, Crona J, Norlen O, et al. Favorable outcome in patients with pheochromocytoma and paraganglioma treated with ^{177}Lu-DOTATATE. Cancers (Basel) 2019;11. Available at: https://www.ncbi.nlm.nih.gov/pubmed/31261748.

473. Yoshinaga K, Oriuchi N, Wakabayashi H, et al. Effects and safety of (1)(3)(1)I-metaiodobenzylguanidine (MIBG) radiotherapy in malignant neuroendocrine tumors: results from a multicenter observational registry. Endocr J 2014;61:1171–1180. Available at: https://www.ncbi.nlm.nih.gov/pubmed/25214026.

474. Inaki A, Shiga T, Tsushima Y, et al. An open-label, single-arm, multi-center, phase II clinical trial of single-dose [^{131}I]meta-iodobenzylguanidine therapy for patients with refractory pheochromocytoma and paraganglioma. Ann Nucl Med 2022;36:267–278. Available at: https://www.ncbi.nlm.nih.gov/pubmed/34870794.

475. van Hulsteijn LT, Niemeijer ND, Dekkers OM, Corssmit EP. (131)I-MIBG therapy for malignant paraganglioma and phaeochromocytoma: systematic review and meta-analysis. Clin Endocrinol (Oxf) 2014;80:487–501. Available at: https://www.ncbi.nlm.nih.gov/pubmed/24118038.

476. Nasca V, Prinzi N, Coppa J, et al. Sunitinib for the treatment of patients with advanced pheochromocytomas or paragangliomas: The phase 2 non-randomized SUTNET clinical trial. Eur J Cancer 2024;209:114276. Available at: https://www.ncbi.nlm.nih.gov/pubmed/39128186.

477. Prinzi N, Corti F, Torchio M, et al. Metastatic pheochromocytomas and paragangliomas: Where are we? Tumori 2022;108:526–540. Available at: https://www.ncbi.nlm.nih.gov/pubmed/35593402.

478. Huang H, Abraham J, Hung E, et al. Treatment of malignant pheochromocytoma/paraganglioma with cyclophosphamide, vincristine, and dacarbazine: Recommendation from a 22-year follow-up of 18 patients. Cancer 2008;113:2020–2028. Available at: https://www.ncbi.nlm.nih.gov/pubmed/18780317.

479. Tong A, Li M, Cui Y, et al. Temozolomide is a potential therapeutic tool for patients with metastatic pheochromocytoma/paraganglioma-Case report and review of the literature. Front Endocrinol (Lausanne) 2020;11:61. Available at: https://www.ncbi.nlm.nih.gov/pubmed/32132978.

480. Kong G, Grozinsky-Glasberg S, Hofman MS, et al. Efficacy of peptide receptor radionuclide therapy for functional metastatic paraganglioma and pheochromocytoma. J Clin Endocrinol Metab 2017;102:3278–3287. Available at: https://www.ncbi.nlm.nih.gov/pubmed/28605448.

481. Satapathy S, Mittal BR, Bhansali A. 'Peptide receptor radionuclide therapy in the management of advanced pheochromocytoma and paraganglioma: A systematic review and meta-analysis'. Clin Endocrinol (Oxf) 2019;91:718–727. Available at: https://www.ncbi.nlm.nih.gov/pubmed/31569282.

482. Nastos K, Cheung VTF, Toumpanakis C, et al. Peptide receptor radionuclide treatment and (131)I-MIBG in the management of patients with metastatic/progressive phaeochromocytomas and paragangliomas. J

Version 3.2025 © 2025 National Comprehensive Cancer Network© (NCCN©), All rights reserved. NCCN Guidelines® and this illustration may not be reproduced in any form without the express written permission of NCCN.

PLEASE NOTE that use of this NCCN Content is governed by the End-User License Agreement, and you MAY NOT distribute this Content or use it with any artificial intelligence model or tool.
Printed by Galya Basol Kochav on 1/7/2026 1:55:52 PM. Copyright © 2026 National Comprehensive Cancer Network, Inc. All Rights Reserved.

Surg Oncol 2017;115:425–434. Available at: https://www.ncbi.nlm.nih.gov/pubmed/28166370.

483. Pinato DJ, Black JR, Ramaswami R, et al. Peptide receptor radionuclide therapy for metastatic paragangliomas. Med Oncol 2016;33:47. Available at: https://www.ncbi.nlm.nih.gov/pubmed/27059363.

484. Zandee WT, Feelders RA, Smit Duijzentkunst DA, et al. Treatment of inoperable or metastatic paragangliomas and pheochromocytomas with peptide receptor radionuclide therapy using 177Lu-DOTATATE. Eur J Endocrinol 2019;181:45–53. Available at: https://www.ncbi.nlm.nih.gov/pubmed/31067510.

485. Prado-Wohlwend S, Del Olmo-Garcia MI, Bello-Arques P, Merino-Torres JF. [^{177}Lu]Lu-DOTA-TATE and [^{131}I]MIBG phenotypic imaging-based therapy in metastatic/inoperable pheochromocytomas and paragangliomas: Comparative results in a single center. Front Endocrinol (Lausanne) 2022;13:778322. Available at: https://www.ncbi.nlm.nih.gov/pubmed/35197929.

486. Tang CYL, Chua WM, Huang HL, et al. Safety and efficacy of peptide receptor radionuclide therapy in patients with advanced pheochromocytoma and paraganglioma: A single-institution experience and review of the literature. J Neuroendocrinol 2023;35:e13349. Available at: https://www.ncbi.nlm.nih.gov/pubmed/37937484.

487. Rubino M, Di Stasio GD, Bodei L, et al. Peptide receptor radionuclide therapy with 177Lu- or 90Y-SSTR peptides in malignant pheochromocytomas (PCCs) and paragangliomas (PGLs): Results from a single institutional retrospective analysis. Endocrine 2024;84:704–710. Available at: https://www.ncbi.nlm.nih.gov/pubmed/38324106.

488. Lin F, Carrasquillo J, del Rivero J, et al. Safety and efficacy of Lu-177-DOTATATE in metastatic or inoperable pheochromocytoma/paraganglioma – An interim analysis [abstract]. J Nucl Med 2023;64:Abstract P1296. Available at: https://jnm.snmjournals.org/content/64/supplement_1/p1296.

489. Laderian B, Zhou M, Luk L, et al. A phase 2 study of lanreotide as a therapy for pheochromocytomas (PCs) and paragangliomas (PGs) [abstract]. J Clin Oncol 2025;43:Abstract 10612. Available at: https://ascopubs.org/doi/10.1200/JCO.2025.43.16_suppl.10612.

490. Larsson C, Skogseid B, Oberg K, et al. Multiple endocrine neoplasia type 1 gene maps to chromosome 11 and is lost in insulinoma. Nature 1988;332:85–87. Available at: https://www.ncbi.nlm.nih.gov/pubmed/2894610.

491. Minoletti F, Butti MG, Coronelli S, et al. The two genes generating RET/PTC3 are localized in chromosomal band 10q11.2. Genes Chromosomes Cancer 1994;11:51–57. Available at: https://www.ncbi.nlm.nih.gov/pubmed/7529046.

492. Hofstra RM, Landsvater RM, Ceccherini I, et al. A mutation in the RET proto-oncogene associated with multiple endocrine neoplasia type 2B and sporadic medullary thyroid carcinoma. Nature 1994;367:375–376. Available at: https://www.ncbi.nlm.nih.gov/pubmed/7906866.

493. Giusti F, Marini F, Brandi ML. Multiple Endocrine Neoplasia Type 1. 2005 Aug 31 [Updated 2017 Dec 14]. In: Adam MP, Feldman J, Mirzaa GM, et al., editors. GeneReviews® [Internet]. Seattle (WA): University of Washington, Seattle; 1993-2025. Available at: http://www.ncbi.nlm.nih.gov/books/NBK1538/. Accessed July 23, 2025.

494. Thakker RV, Newey PJ, Walls GV, et al. Clinical practice guidelines for multiple endocrine neoplasia type 1 (MEN1). J Clin Endocrinol Metab 2012;97:2990–3011. Available at: https://www.ncbi.nlm.nih.gov/pubmed/22723327.

495. Niederle B, Selberherr A, Bartsch DK, et al. Multiple endocrine neoplasia type 1 and the pancreas: diagnosis and treatment of functioning and non-functioning pancreatic and duodenal neuroendocrine neoplasia within the MEN1 syndrome - An international consensus statement. Neuroendocrinology 2021;111:609–630. Available at: https://www.ncbi.nlm.nih.gov/pubmed/32971521.

Version 3.2025 © 2025 National Comprehensive Cancer Network© (NCCN©), All rights reserved. NCCN Guidelines® and this illustration may not be reproduced in any form without the express written permission of NCCN.

PLEASE NOTE that use of this NCCN Content is governed by the End-User License Agreement, and you MAY NOT distribute this Content or use it with any artificial intelligence model or tool.
Printed by Galya Basol Kochav on 1/7/2026 1:55:52 PM. Copyright © 2026 National Comprehensive Cancer Network, Inc. All Rights Reserved.

496. Mitchell BK, Merrell RC, Kinder BK. Localization studies in patients with hyperparathyroidism. Surg Clin North Am 1995;75:483–498. Available at: https://www.ncbi.nlm.nih.gov/pubmed/7747254.

497. Wei JP, Burke GJ, Mansberger AR, Jr. Preoperative imaging of abnormal parathyroid glands in patients with hyperparathyroid disease using combination Tc-99m-pertechnetate and Tc-99m-sestamibi radionuclide scans. Ann Surg 1994;219:568–572; discussion 572–563. Available at: https://www.ncbi.nlm.nih.gov/pubmed/8185405.

498. Lavely WC, Goetze S, Friedman KP, et al. Comparison of SPECT/CT, SPECT, and planar imaging with single- and dual-phase (99m)Tc-sestamibi parathyroid scintigraphy. J Nucl Med 2007;48:1084–1089. Available at: https://www.ncbi.nlm.nih.gov/pubmed/17574983.

499. Bann DV, Zacharia T, Goldenberg D, Goyal N. Parathyroid localization using 4D-computed tomography. Ear Nose Throat J 2015;94:E55–57. Available at: https://www.ncbi.nlm.nih.gov/pubmed/25923289.

500. Kebebew E, Clark OH. Parathyroid adenoma, hyperplasia, and carcinoma: localization, technical details of primary neck exploration, and treatment of hypercalcemic crisis. Surg Oncol Clin N Am 1998;7:721–748. Available at: https://www.ncbi.nlm.nih.gov/pubmed/9735131.

501. Wells SA, Jr., Ellis GJ, Gunnells JC, et al. Parathyroid autotransplantation in primary parathyroid hyperplasia. N Engl J Med 1976;295:57–62. Available at: https://www.ncbi.nlm.nih.gov/pubmed/1272325.

502. Wilhelm SM, Wang TS, Ruan DT, et al. The american association of endocrine surgeons guidelines for definitive management of primary hyperparathyroidism. JAMA Surg 2016;151:959–968. Available at: https://pubmed.ncbi.nlm.nih.gov/27532368/.

503. Lairmore TC, Govednik CM, Quinn CE, et al. A randomized, prospective trial of operative treatments for hyperparathyroidism in patients with multiple endocrine neoplasia type 1. Surgery 2014;156:1326–1334; discussion 1334–1325. Available at: https://www.ncbi.nlm.nih.gov/pubmed/25262224.

504. Adkisson CD, Stauffer JA, Bowers SP, et al. What extent of pancreatic resection do patients with MEN-1 require? JOP 2012;13:402–408. Available at: https://www.ncbi.nlm.nih.gov/pubmed/22797396.

505. Newey PJ, Newell-Price J. MEN1 surveillance Guidelines: Time to (re)think? J Endocr Soc 2022;6:bvac001. Available at: https://www.ncbi.nlm.nih.gov/pubmed/35079671.

506. Kamilaris CDC, Stratakis CA. Multiple endocrine neoplasia Type 1 (MEN1): An update and the significance of early genetic and clinical diagnosis. Front Endocrinol (Lausanne) 2019;10:339. Available at: https://www.ncbi.nlm.nih.gov/pubmed/31263451.

507. Klein Haneveld MJ, van Treijen MJC, Pieterman CRC, et al. Initiating pancreatic neuroendocrine tumor (pNET) screening in young MEN1 patients: Results from the DutchMEN study group. J Clin Endocrinol Metab 2021;106:3515–3525. Available at: https://www.ncbi.nlm.nih.gov/pubmed/34333645.

508. Goudet P, Dalac A, Le Bras M, et al. MEN1 disease occurring before 21 years old: A 160-patient cohort study from the Groupe d'etude des Tumeurs Endocrines. J Clin Endocrinol Metab 2015;100:1568–1577. Available at: https://www.ncbi.nlm.nih.gov/pubmed/25594862.

509. Goncalves TD, Toledo RA, Sekiya T, et al. Penetrance of functioning and nonfunctioning pancreatic neuroendocrine tumors in multiple endocrine neoplasia type 1 in the second decade of life. J Clin Endocrinol Metab 2014;99:E89–96. Available at: https://www.ncbi.nlm.nih.gov/pubmed/24178797.

510. Montenegro FL, Lourenco DM, Jr., Tavares MR, et al. Total parathyroidectomy in a large cohort of cases with hyperparathyroidism associated with multiple endocrine neoplasia type 1: experience from a single academic center. Clinics (Sao Paulo) 2012;67 Suppl 1:131–139. Available at: https://www.ncbi.nlm.nih.gov/pubmed/22584718.

Version 3.2025 © 2025 National Comprehensive Cancer Network© (NCCN©), All rights reserved. NCCN Guidelines® and this illustration may not be reproduced in any form without the express written permission of NCCN.

PLEASE NOTE that use of this NCCN Content is governed by the End-User License Agreement, and you MAY NOT distribute this Content or use it with any artificial intelligence model or tool.
Printed by Galya Basol Kochav on 1/7/2026 1:55:52 PM. Copyright © 2026 National Comprehensive Cancer Network, Inc. All Rights Reserved.

511. Faggiano A, Modica R, Lo Calzo F, et al. Lanreotide therapy vs active surveillance in MEN1-related pancreatic neuroendocrine tumors < 2 centimeters. J Clin Endocrinol Metab 2020;105. Available at: https://www.ncbi.nlm.nih.gov/pubmed/31586182.

512. Eng C, Smith DP, Mulligan LM, et al. A novel point mutation in the tyrosine kinase domain of the RET proto-oncogene in sporadic medullary thyroid carcinoma and in a family with FMTC. Oncogene 1995;10:509–513. Available at: https://www.ncbi.nlm.nih.gov/pubmed/7845675.

513. Eng C, Plitt G. Multiple Endocrine Neoplasia Type 2. 1999 Sep 27 [Updated 2023 Aug 10]. In: Adam MP, Feldman J, Mirzaa GM, et al., editors. GeneReviews® [Internet]. Seattle (WA): University of Washington, Seattle; 1993-2025. Available at: http://www.ncbi.nlm.nih.gov/books/NBK1257/. Accessed July 23, 2025.

514. Wells SA, Jr., Asa SL, Dralle H, et al. Revised American Thyroid Association guidelines for the management of medullary thyroid carcinoma. Thyroid 2015;25:567–610. Available at: https://www.ncbi.nlm.nih.gov/pubmed/25810047.

515. Amodru V, Taieb D, Guerin C, et al. MEN2-related pheochromocytoma: Current state of knowledge, specific characteristics in MEN2B, and perspectives. Endocrine 2020;69:496–503. Available at: https://www.ncbi.nlm.nih.gov/pubmed/32388798.

516. Castinetti F, Qi XP, Walz MK, et al. Outcomes of adrenal-sparing surgery or total adrenalectomy in phaeochromocytoma associated with multiple endocrine neoplasia type 2: an international retrospective population-based study. Lancet Oncol 2014;15:648–655. Available at: https://www.ncbi.nlm.nih.gov/pubmed/24745698.

517. Singh S, Hope TA, Bergsland EB, et al. Consensus report of the 2021 National Cancer Institute neuroendocrine tumor clinical trials planning meeting. J Natl Cancer Inst 2023;115:1001–1010. Available at: https://www.ncbi.nlm.nih.gov/pubmed/37255328.

Version 3.2025 © 2025 National Comprehensive Cancer Network© (NCCN©), All rights reserved. NCCN Guidelines® and this illustration may not be reproduced in any form without the express written permission of NCCN.